



Introduction to Radiology For TB Nurses

Megan Devine, MD

Medical Consultant
Heartland National TB Center

Associate Professor
Internal Medicine/Pulmonary Medicine/Critical Care
University of Texas Health Science Center at Tyler

Chest Radiology in TB

- X-Rays penetrate air, absorbed by fluids/solids
- Chest radiographs show us shadows of organs and structures in the chest
- Interpretation of a chest radiograph is pattern recognition that requires clinical correlation for true diagnosis
- To know what “abnormal” looks like, you have to know what “normal” looks like



Chest Radiology Basics

- Dark/black = Air
- Dense White = Calcium (Bone Density)
- White = Water Density (Everything else)
 - Water
 - Blood
 - Fat
 - Tissue
 - Pus



Posterior-Anterior CXR

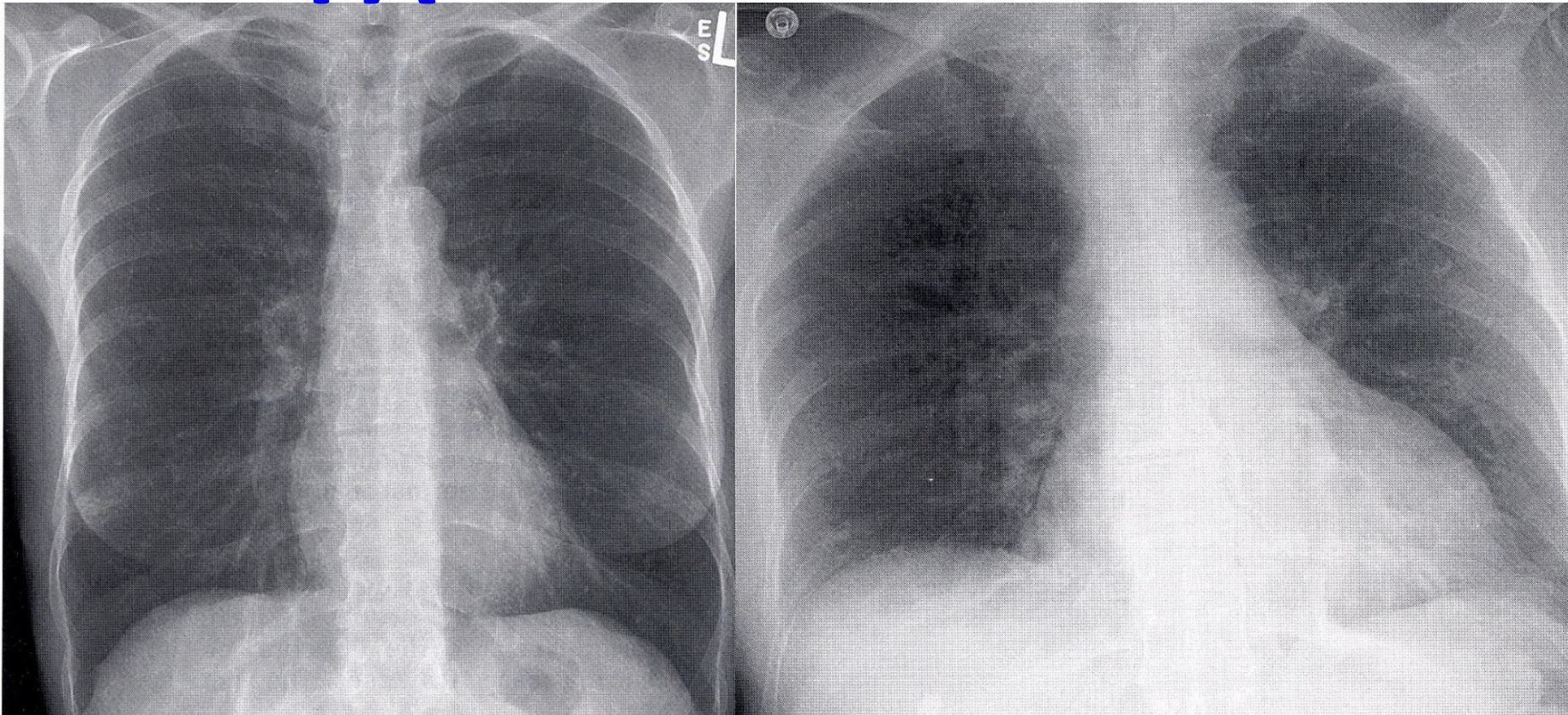


Normal CXR - distance 6 feet from X-ray tube to cassette
to reduce magnification and enhance sharpness.

Same Patient, Two Views

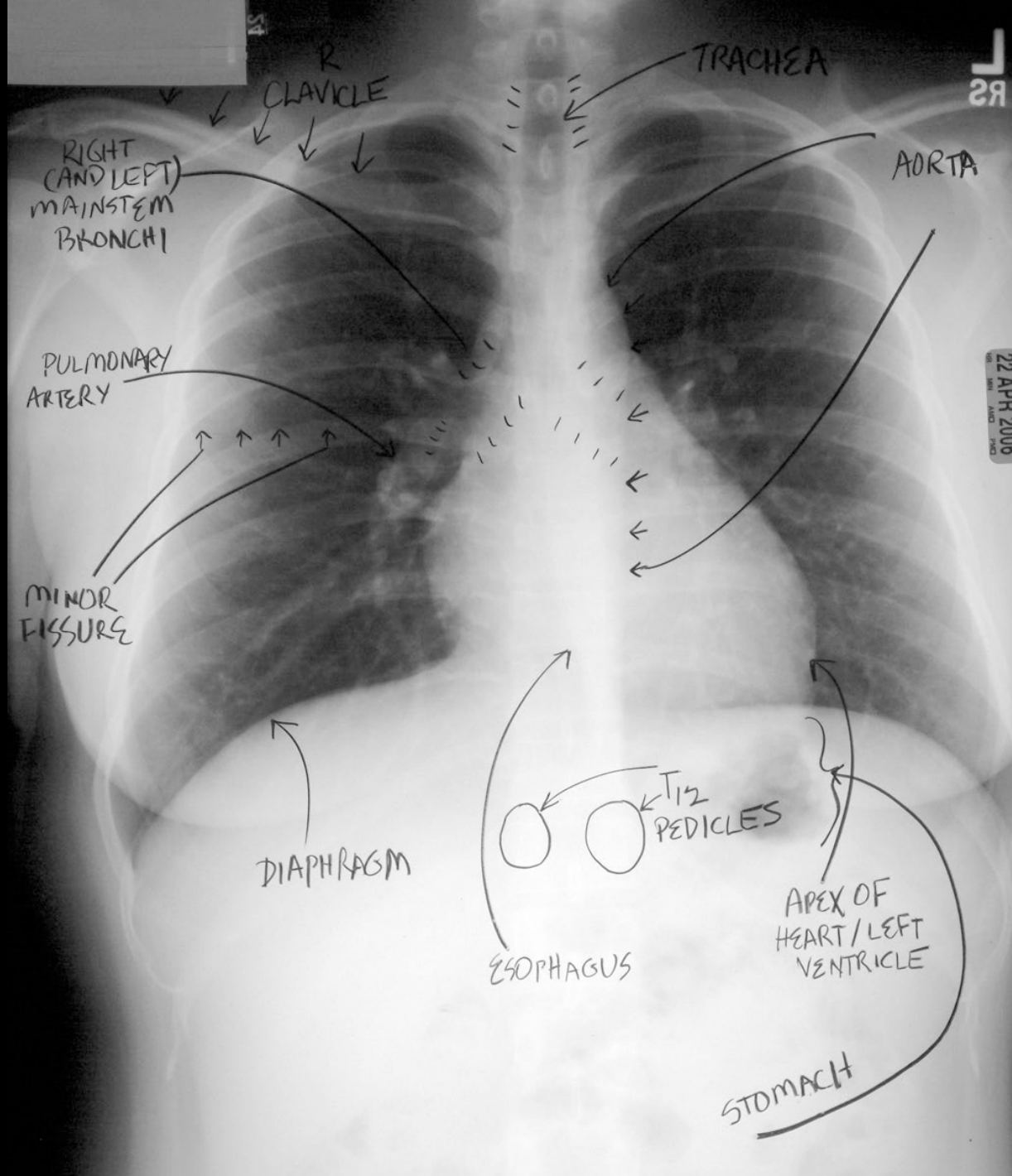
PA

AP

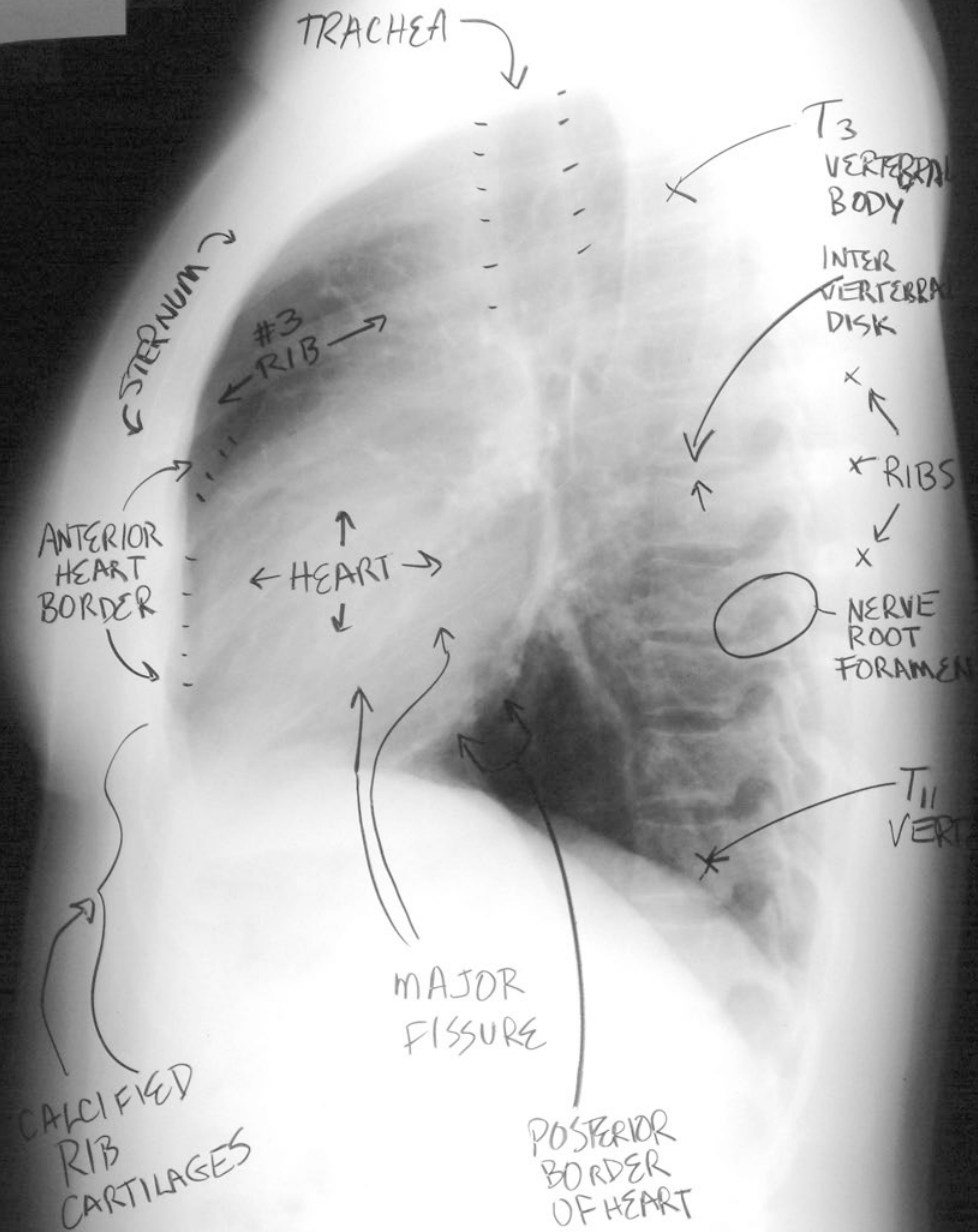


AP is taken at a shorter X-ray tube to receptor distance.
Compared with the PA CXR, the AP has a greater magnification, and the anatomy appears less sharp.



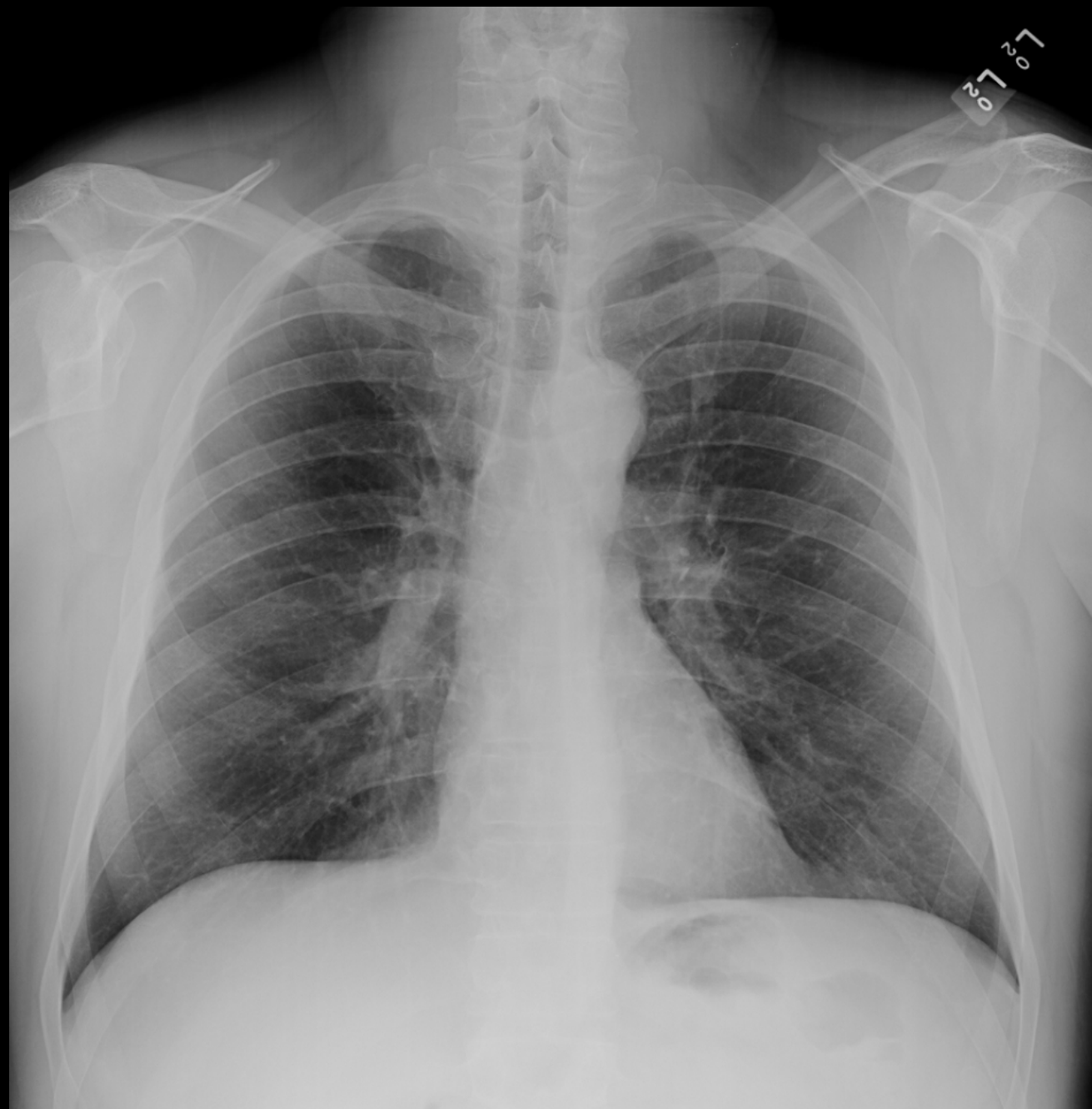

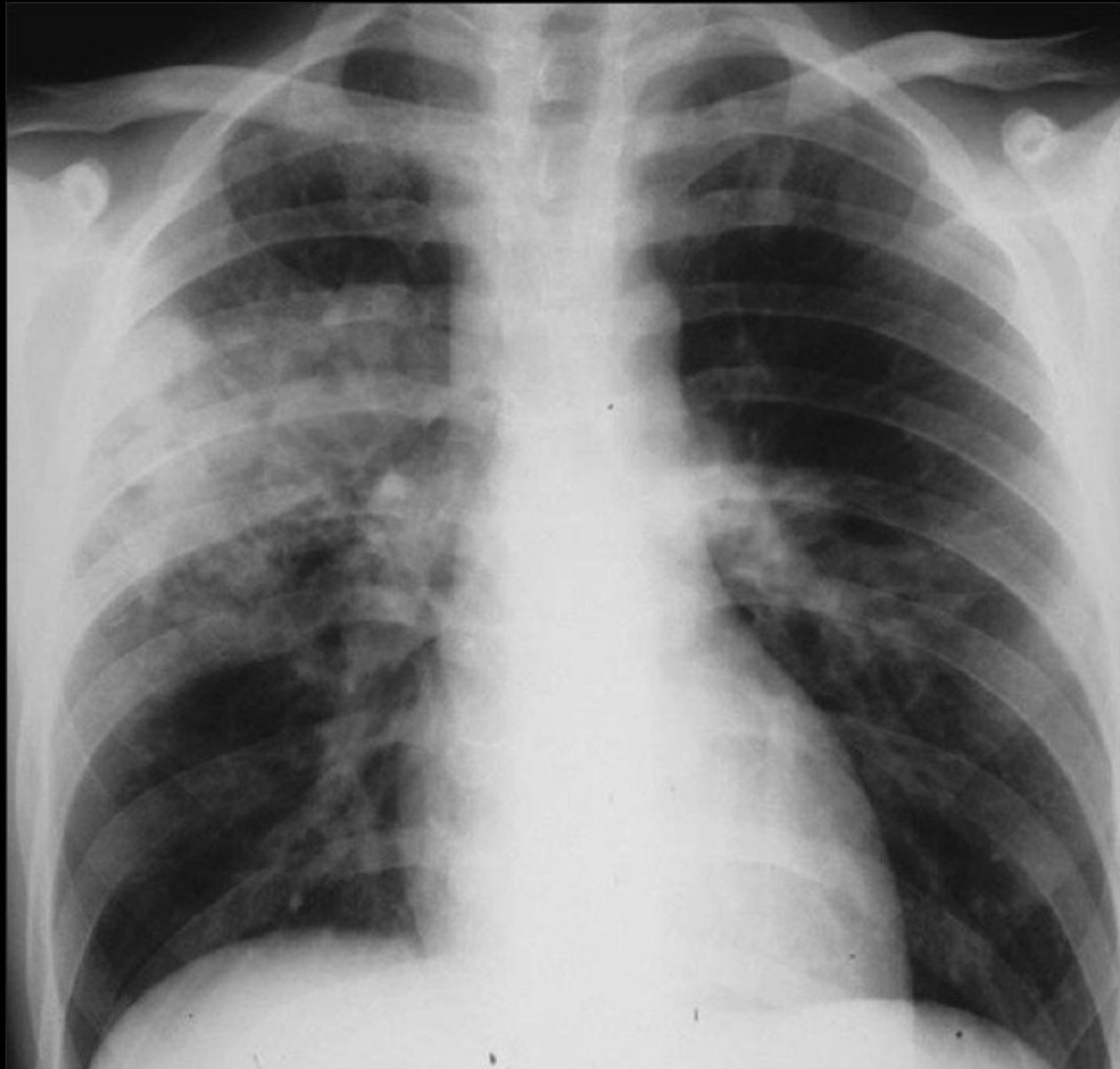
22 APR 2006

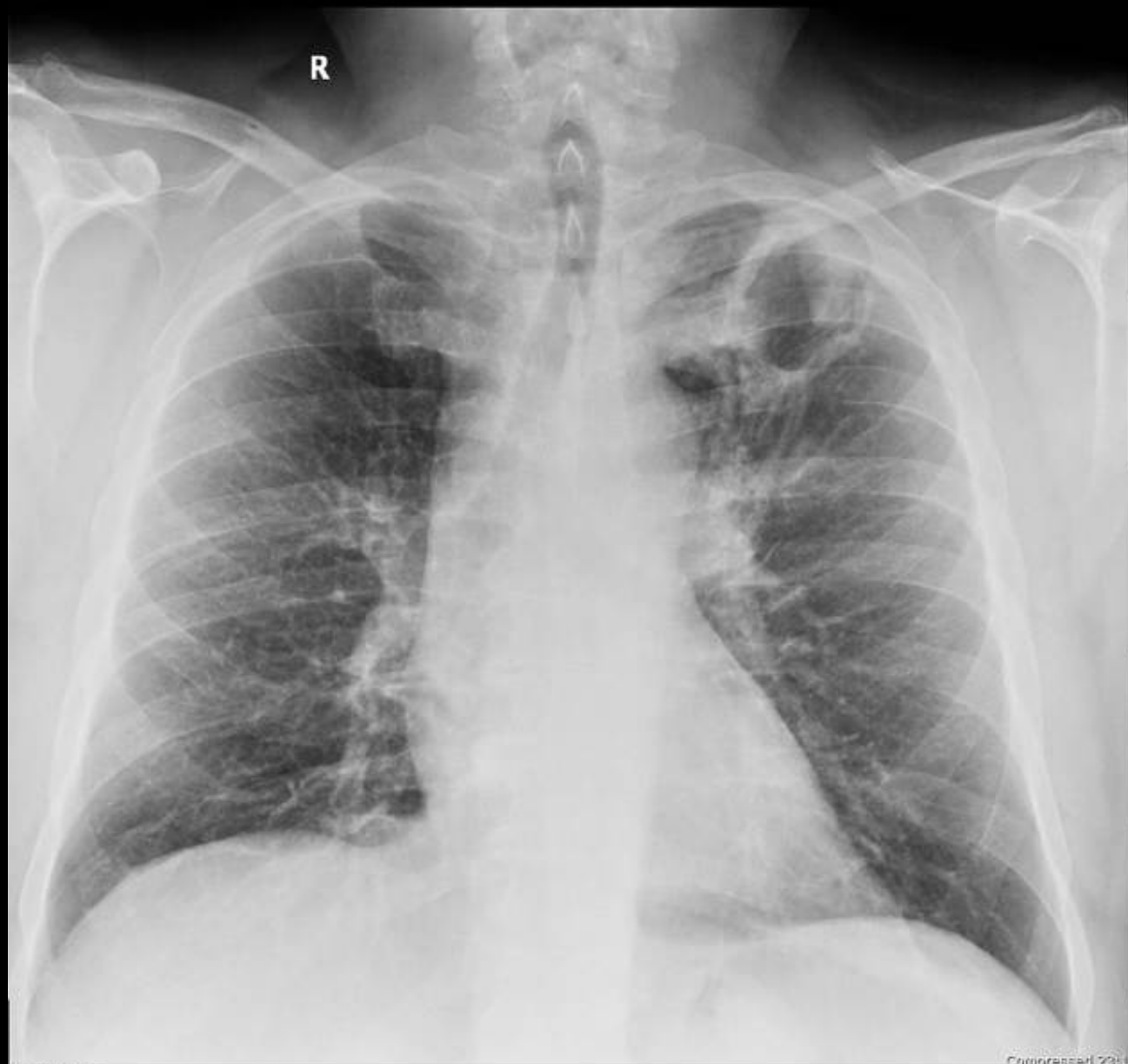

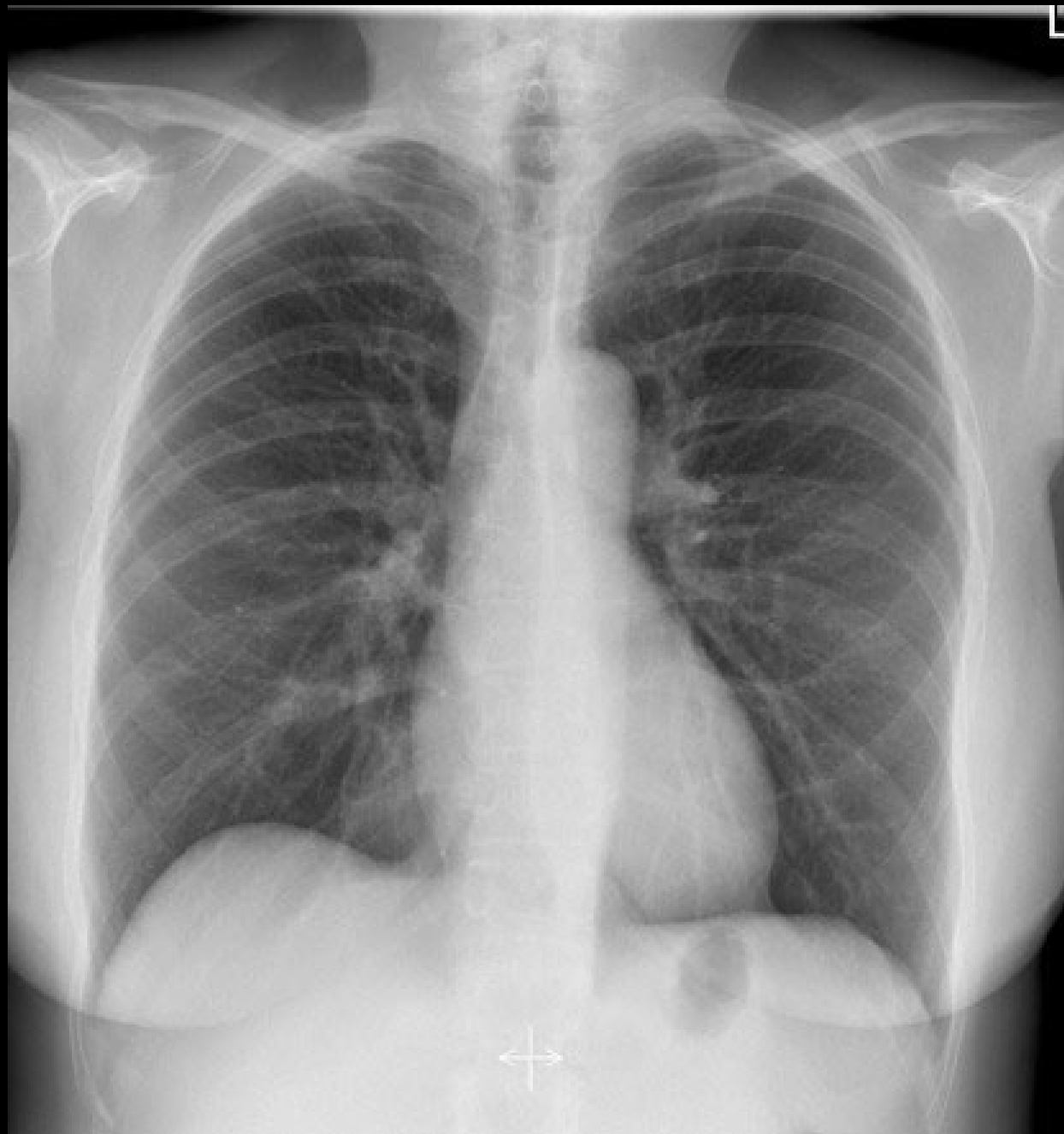
Normal Or Abnormal ?

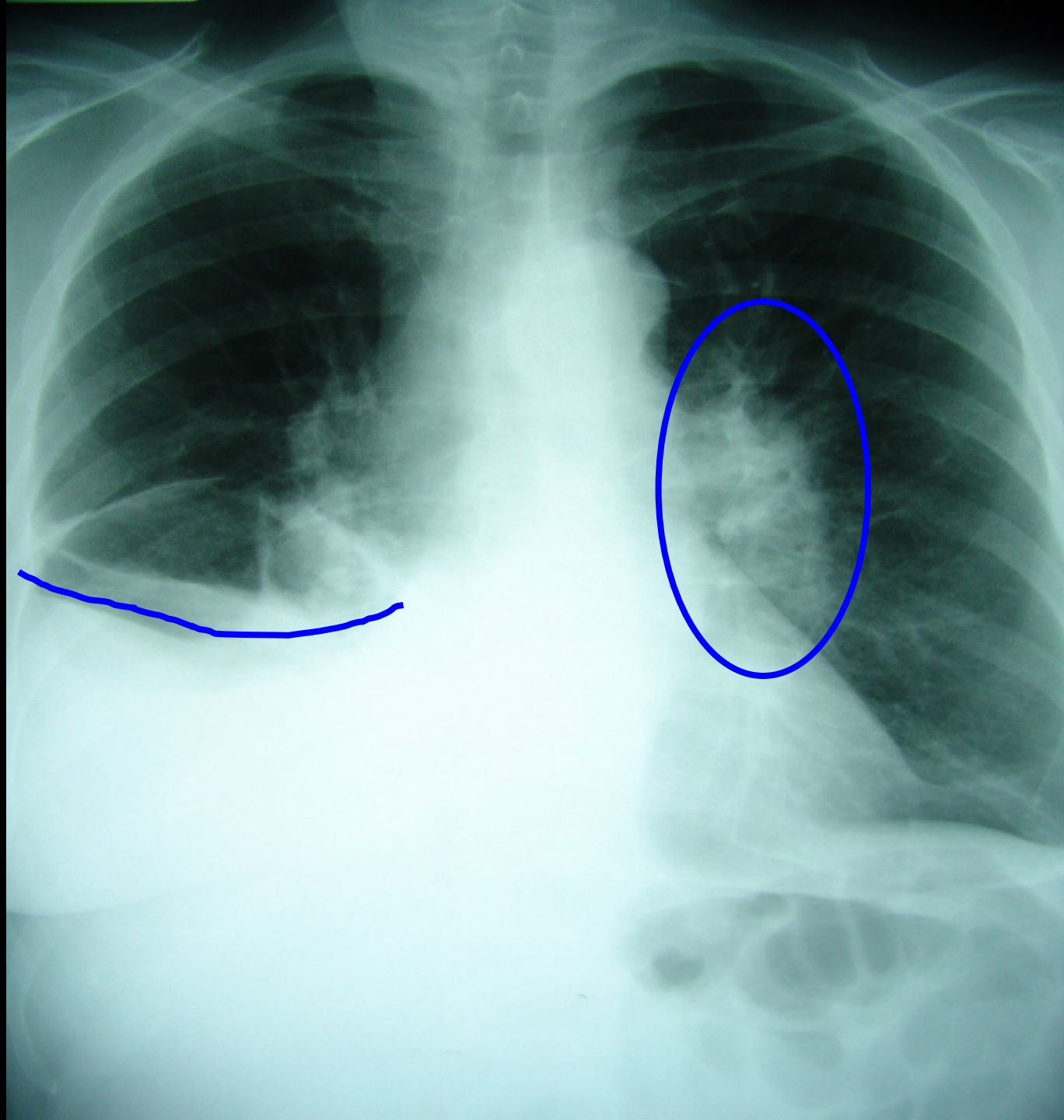


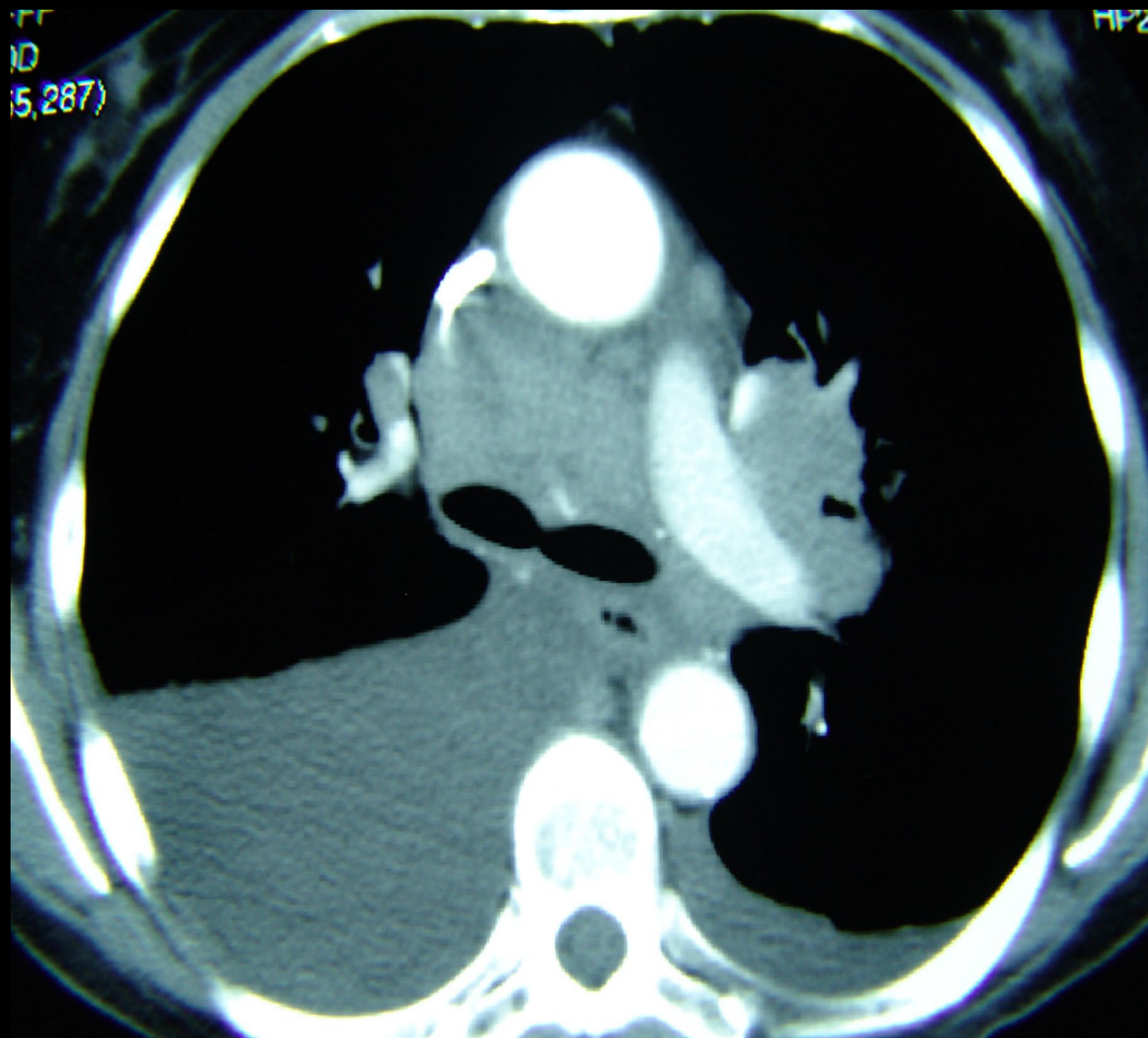


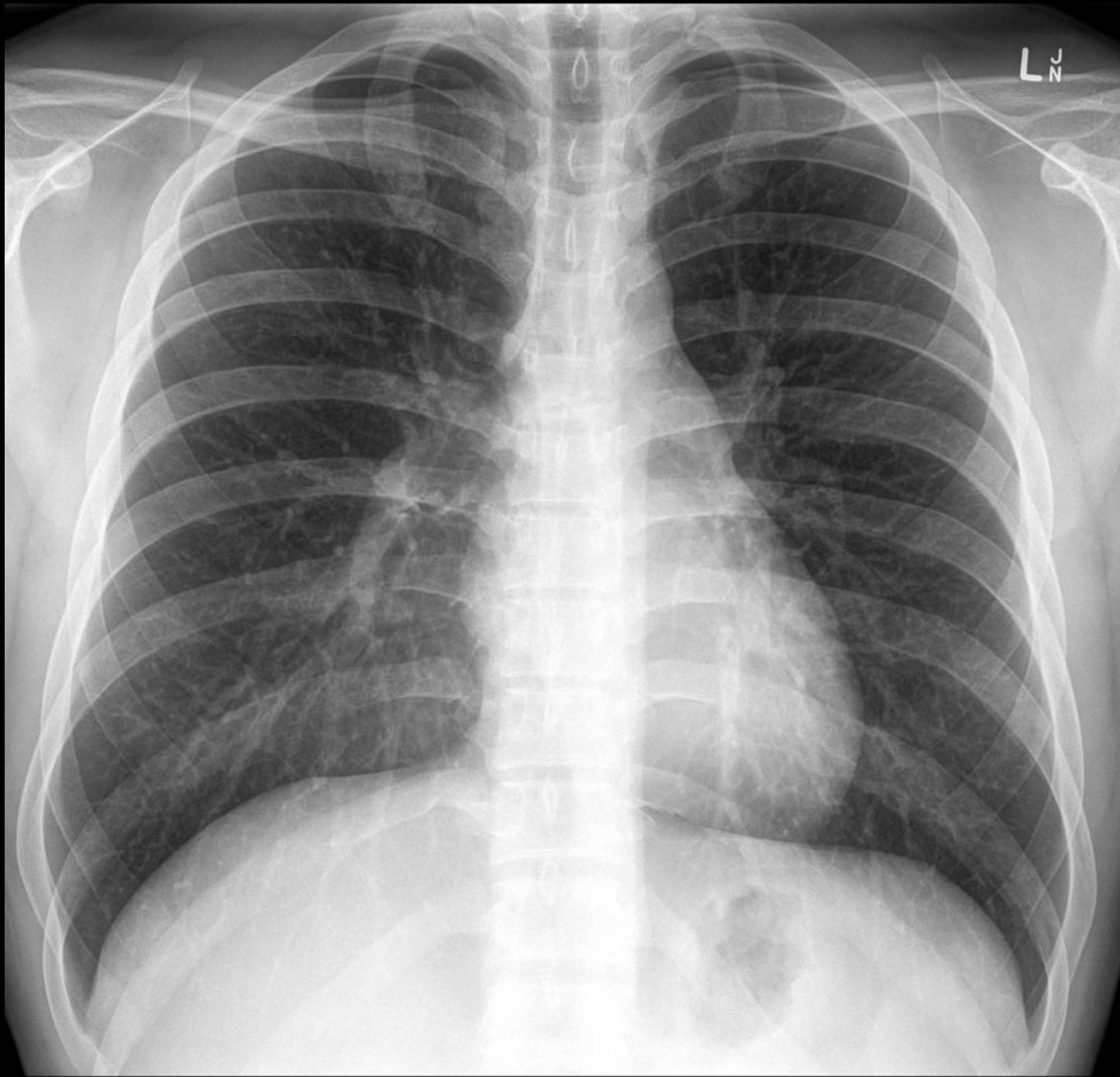






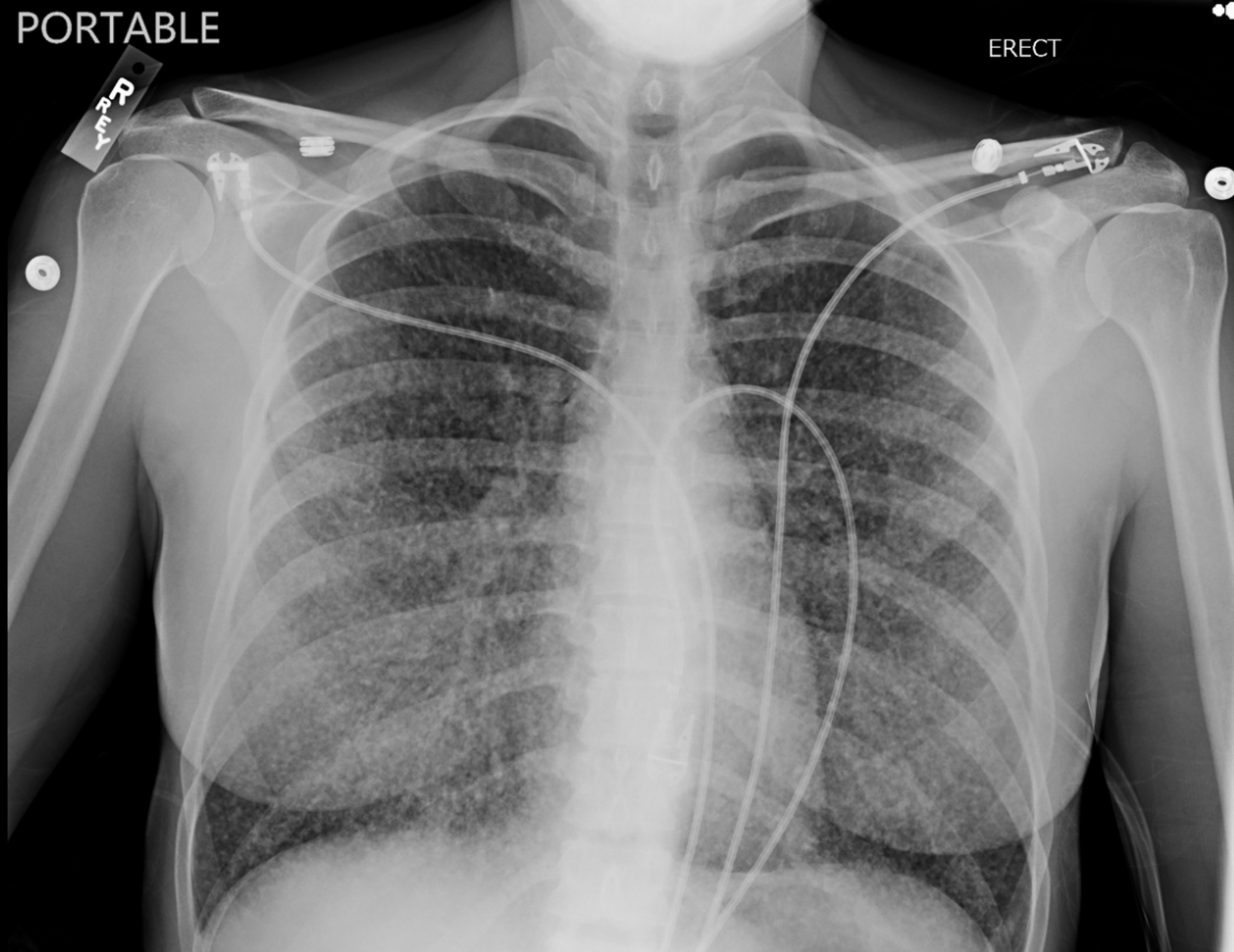


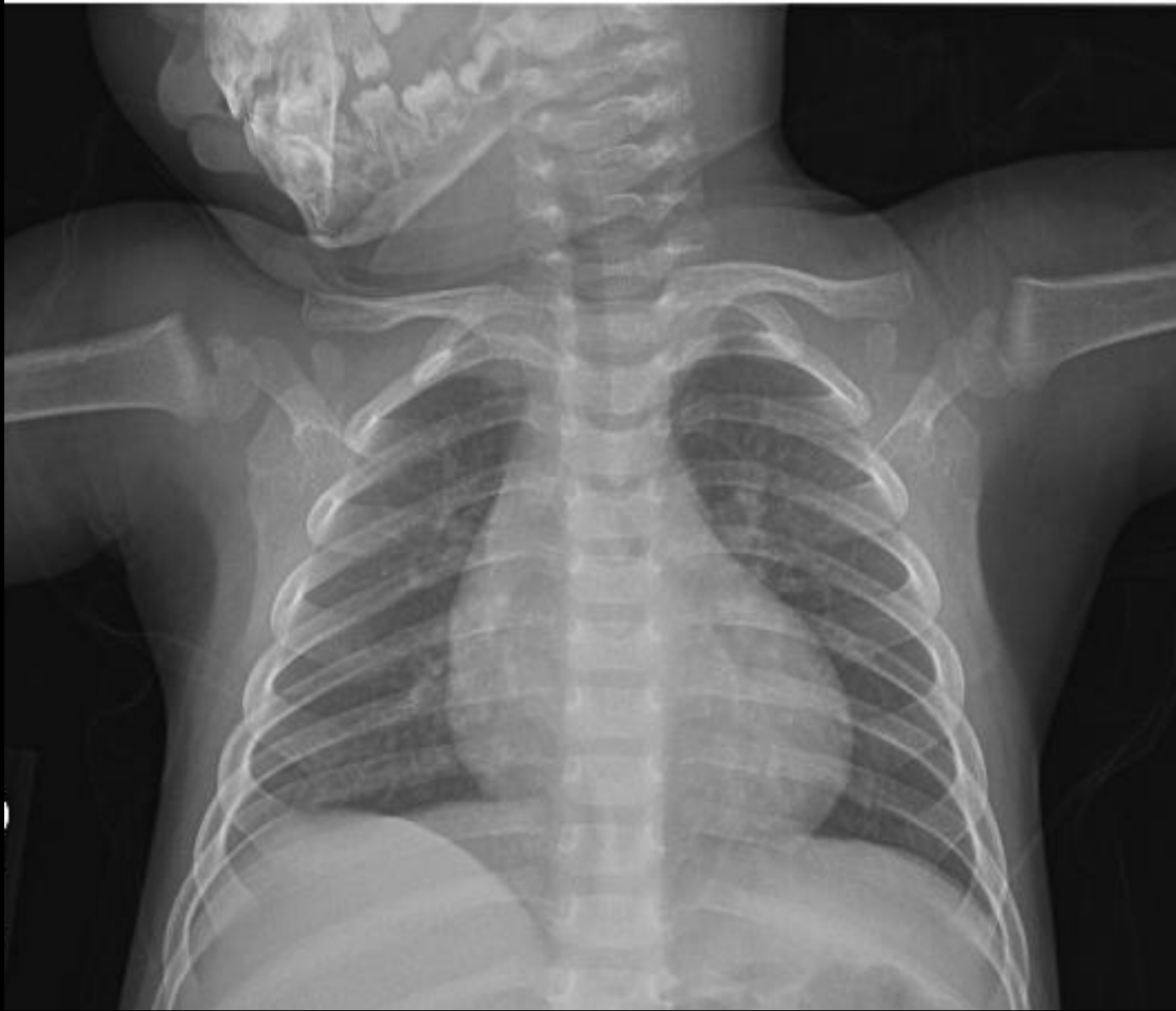



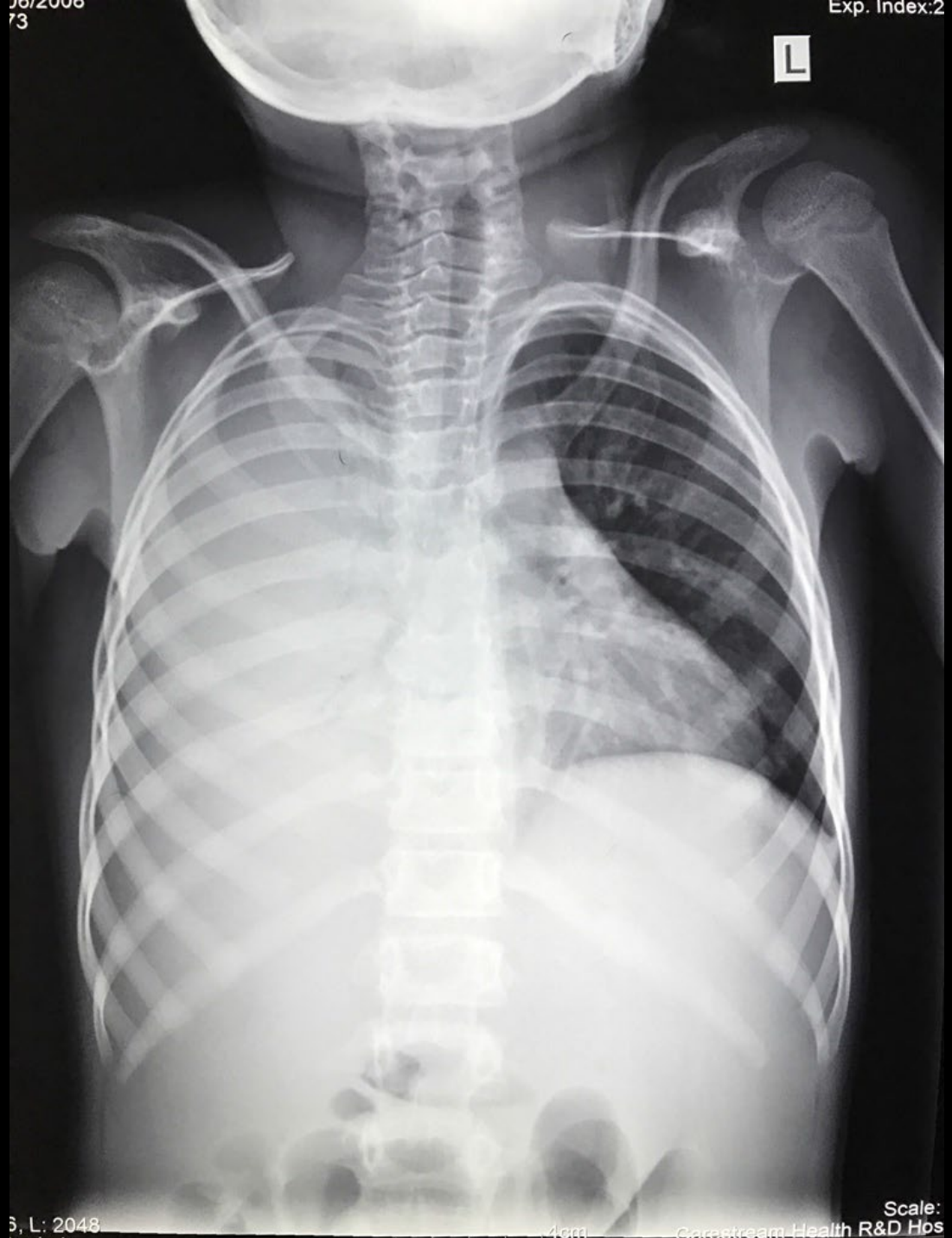PORTABLE

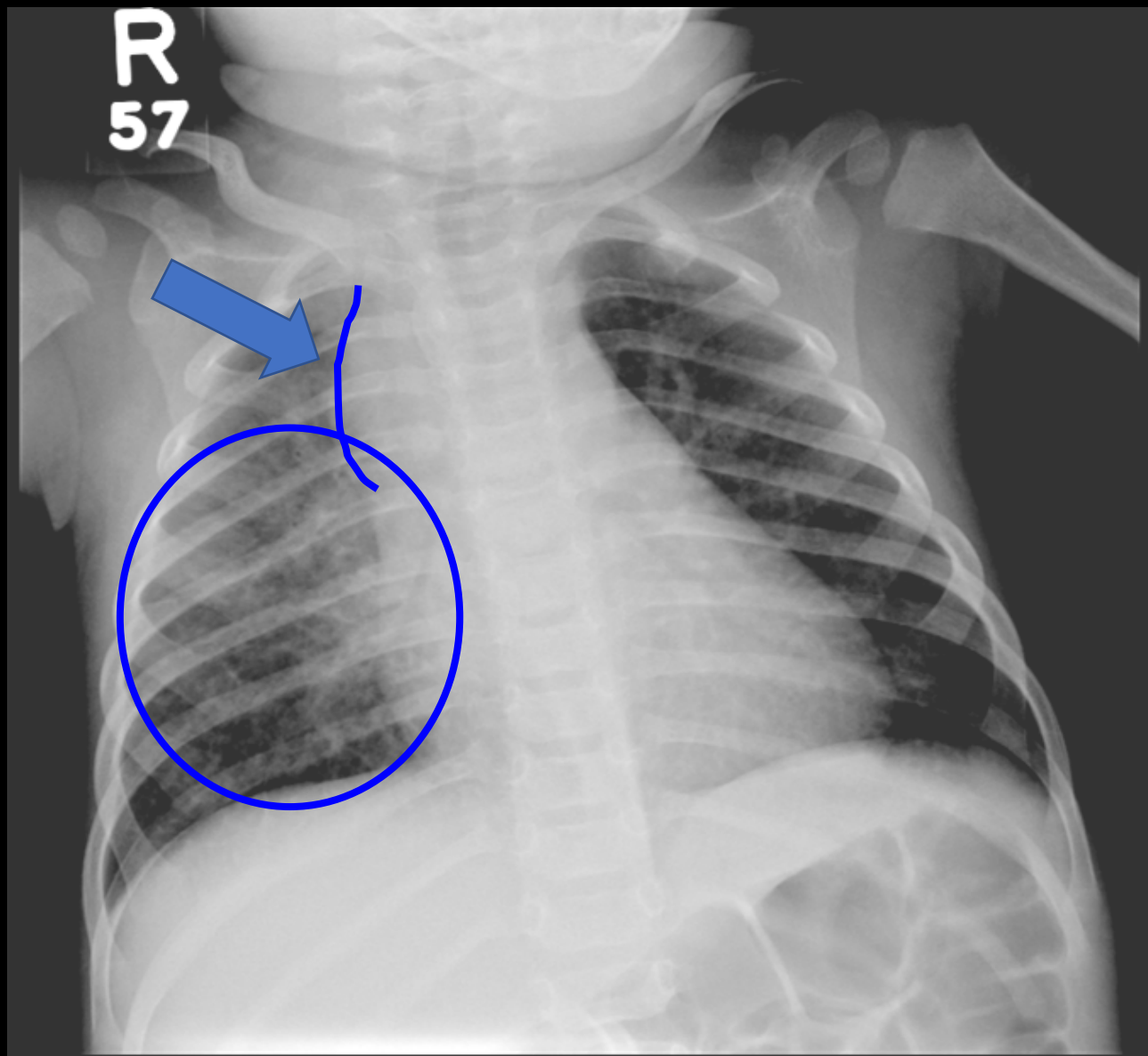
ERECT





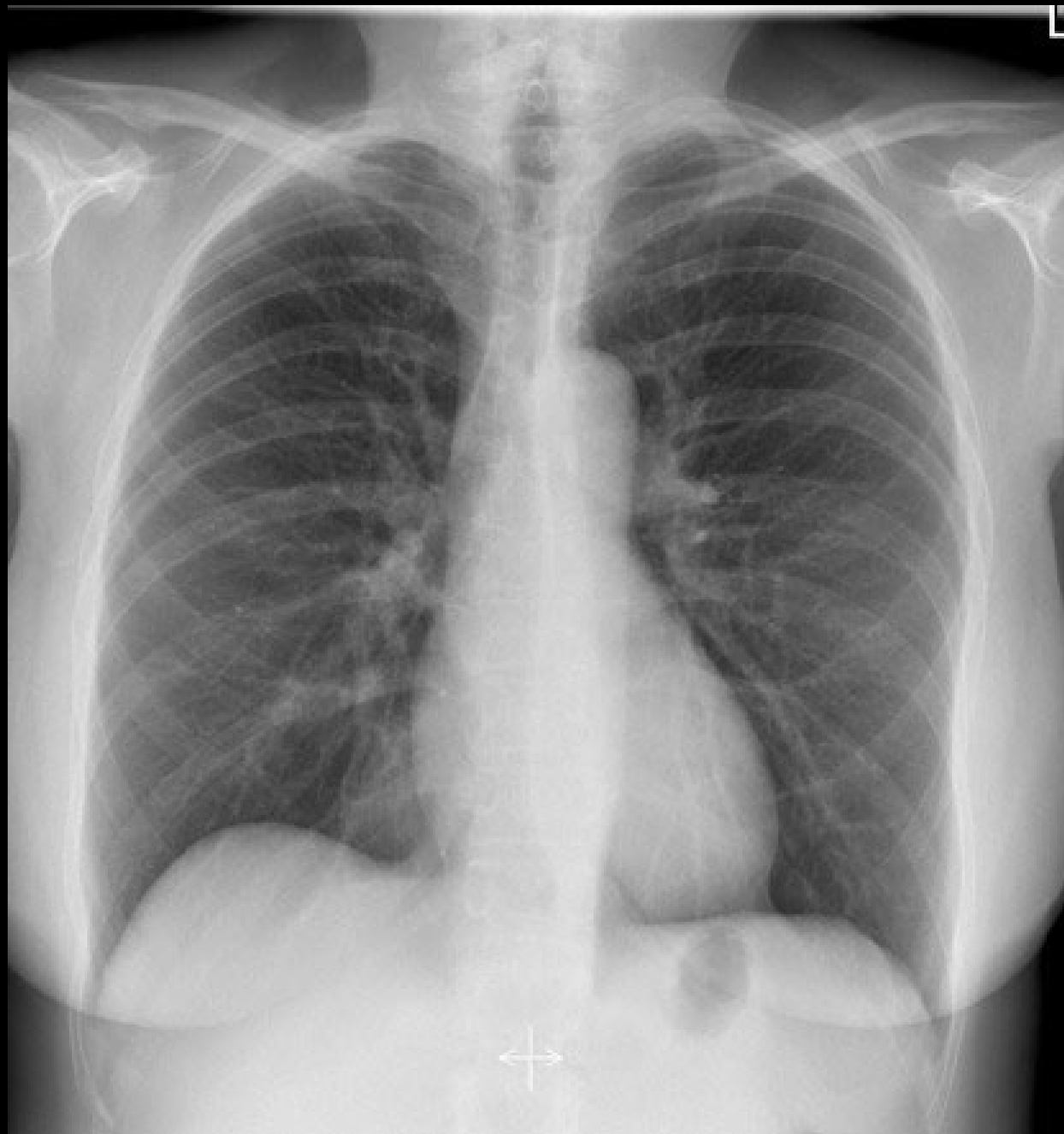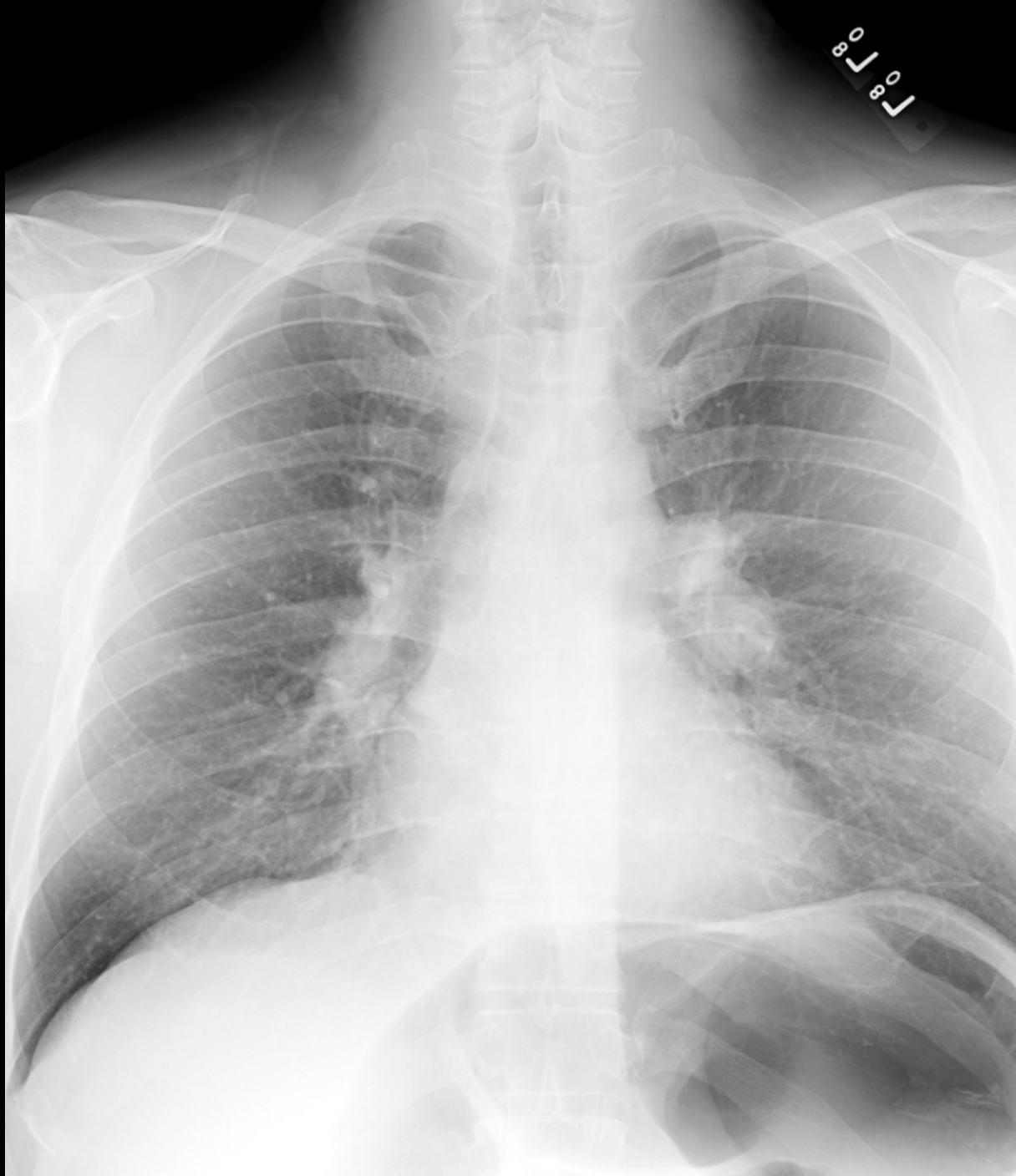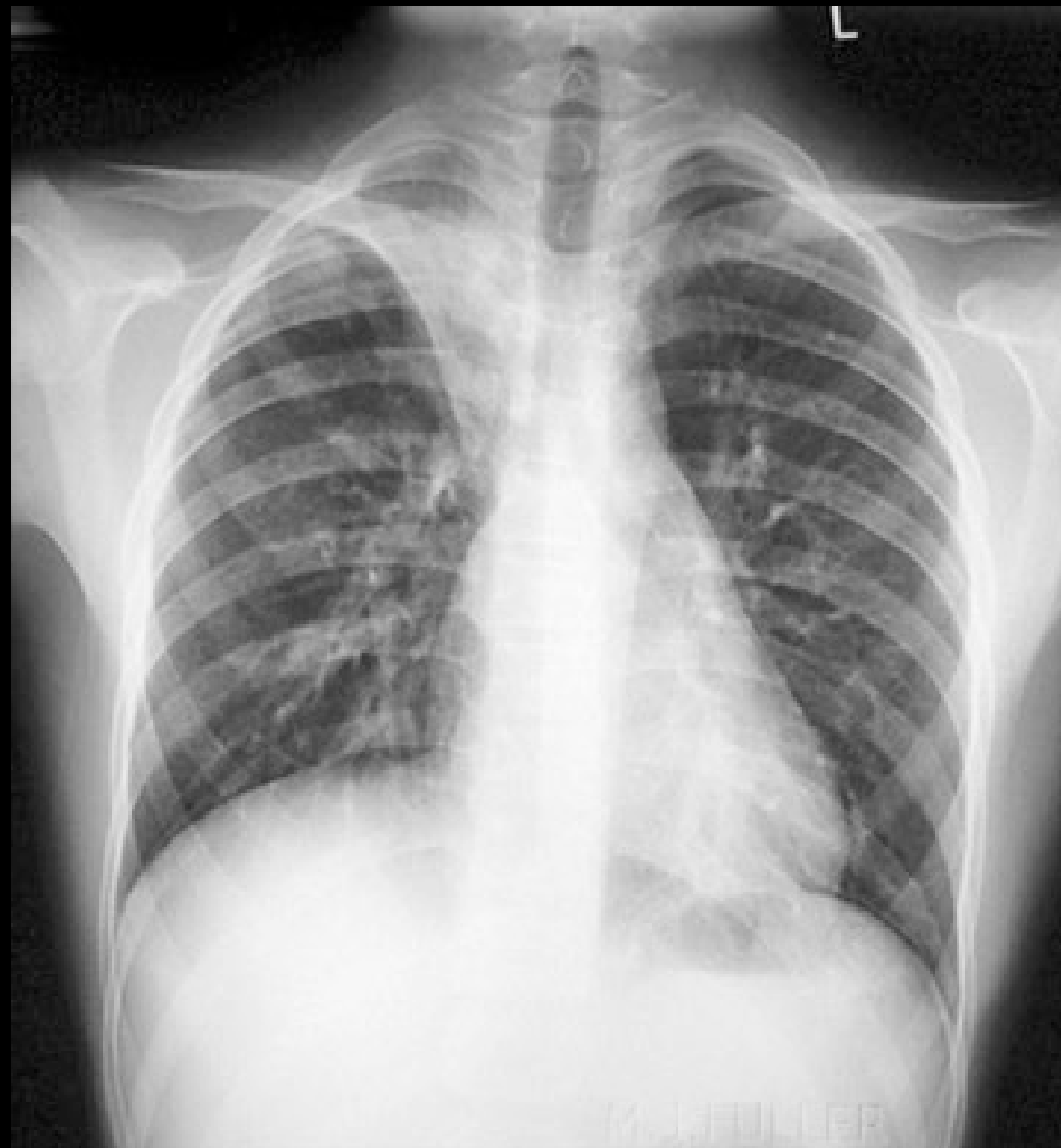
L

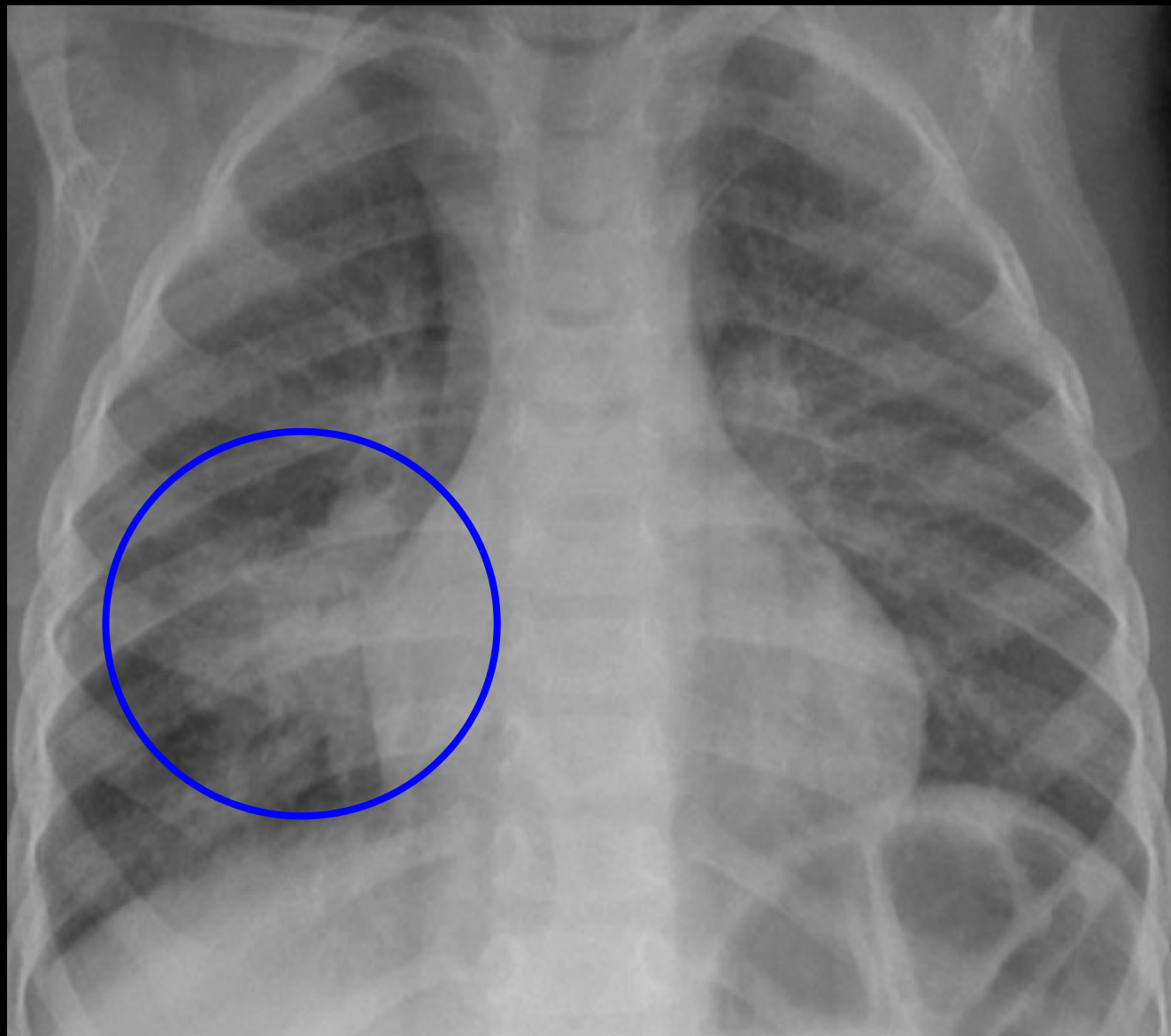


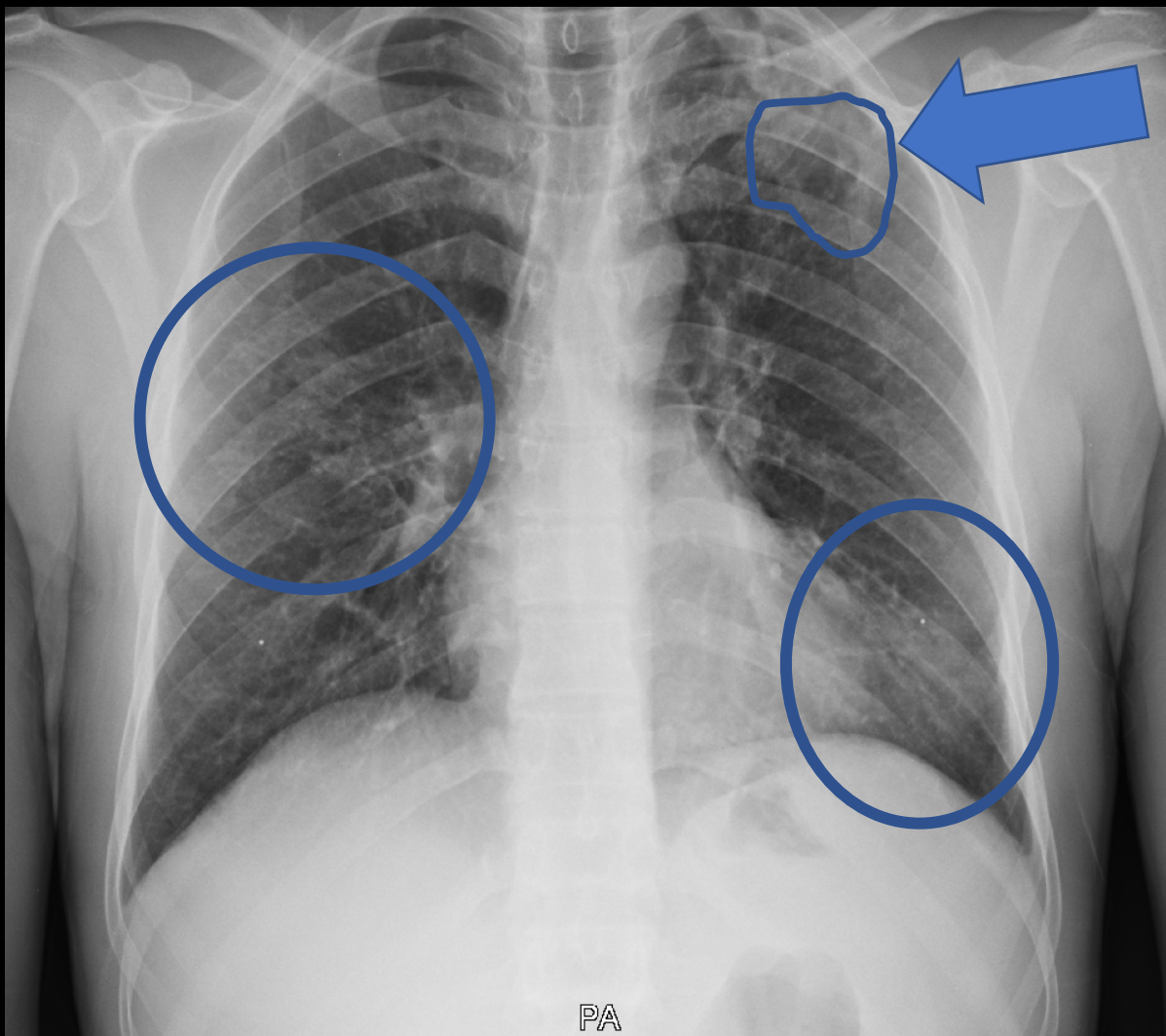






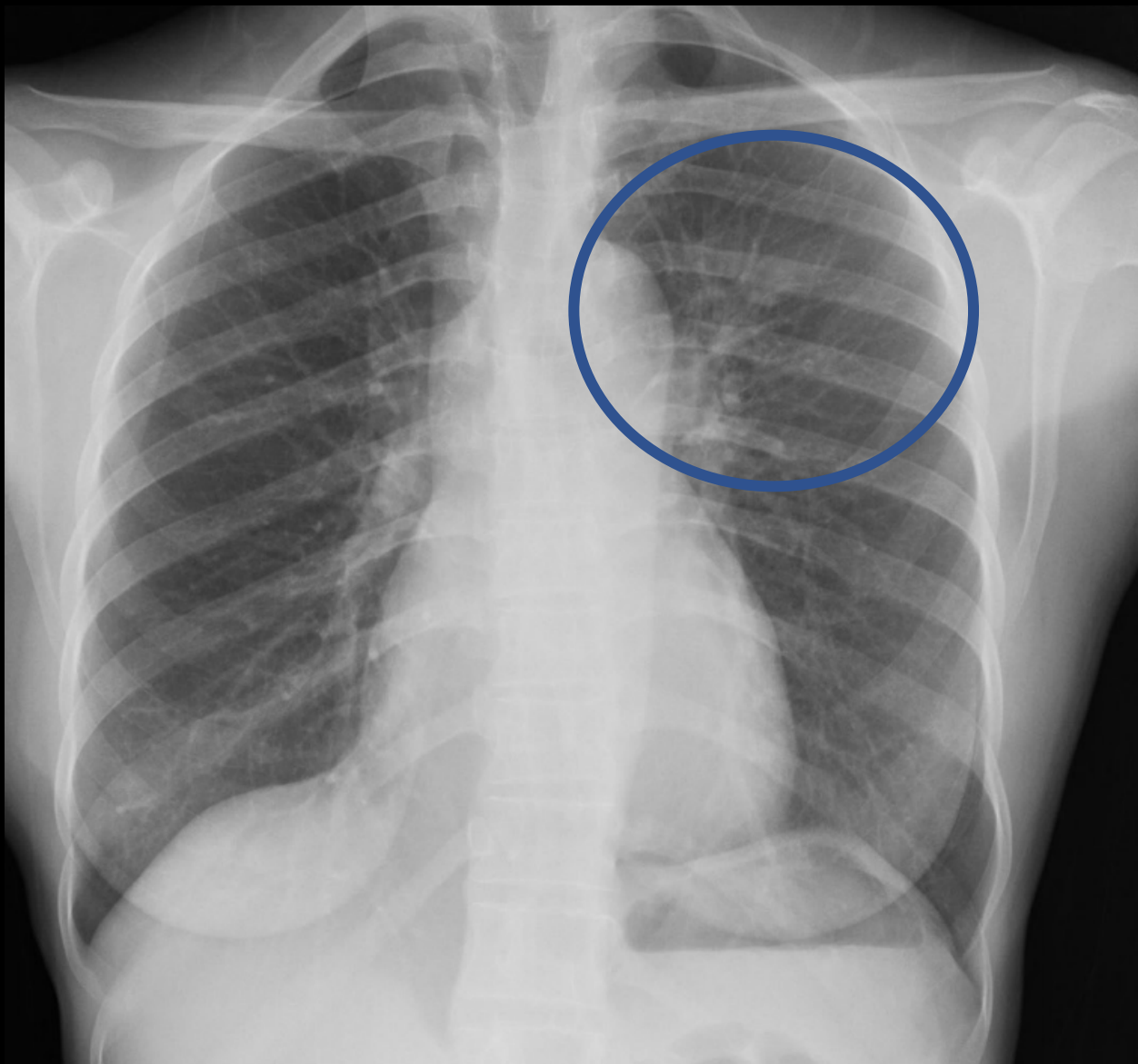






Chest X-ray is one piece of the TB puzzle





Chest Radiology in TB

- Interpretation of a chest radiograph is pattern recognition that requires clinical correlation for true diagnosis



Thank you

Heartland National TB Center

