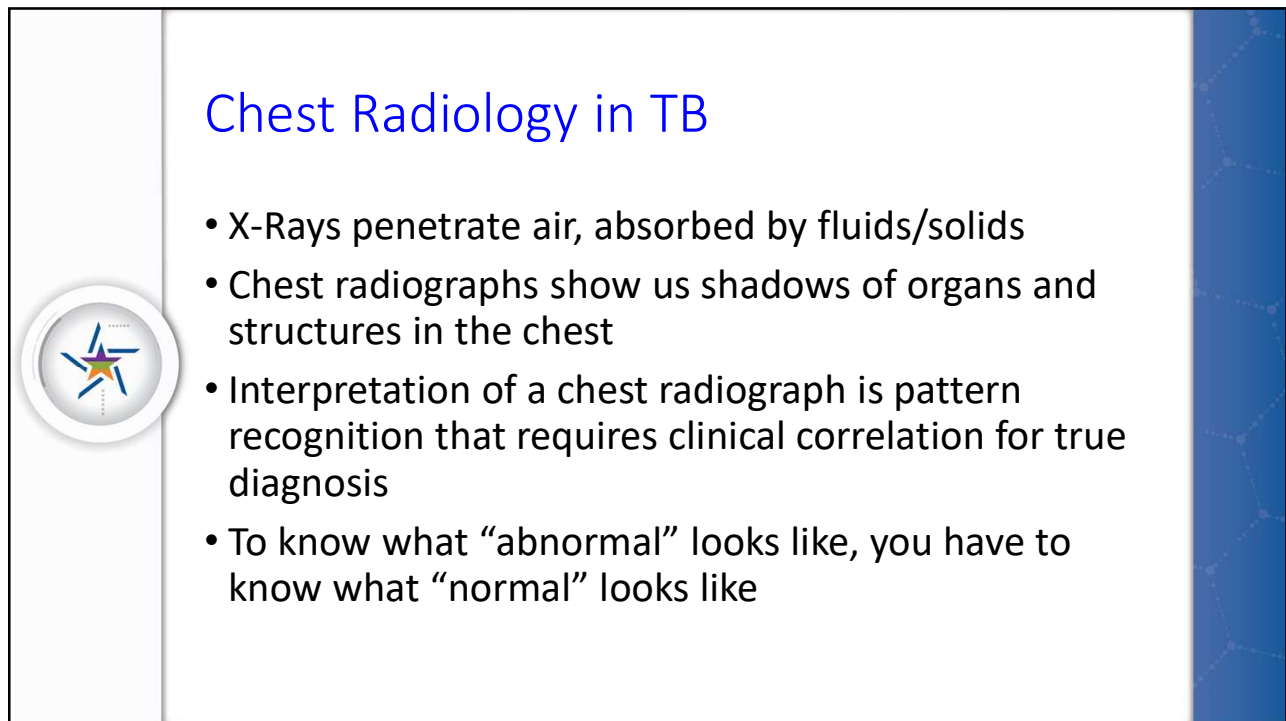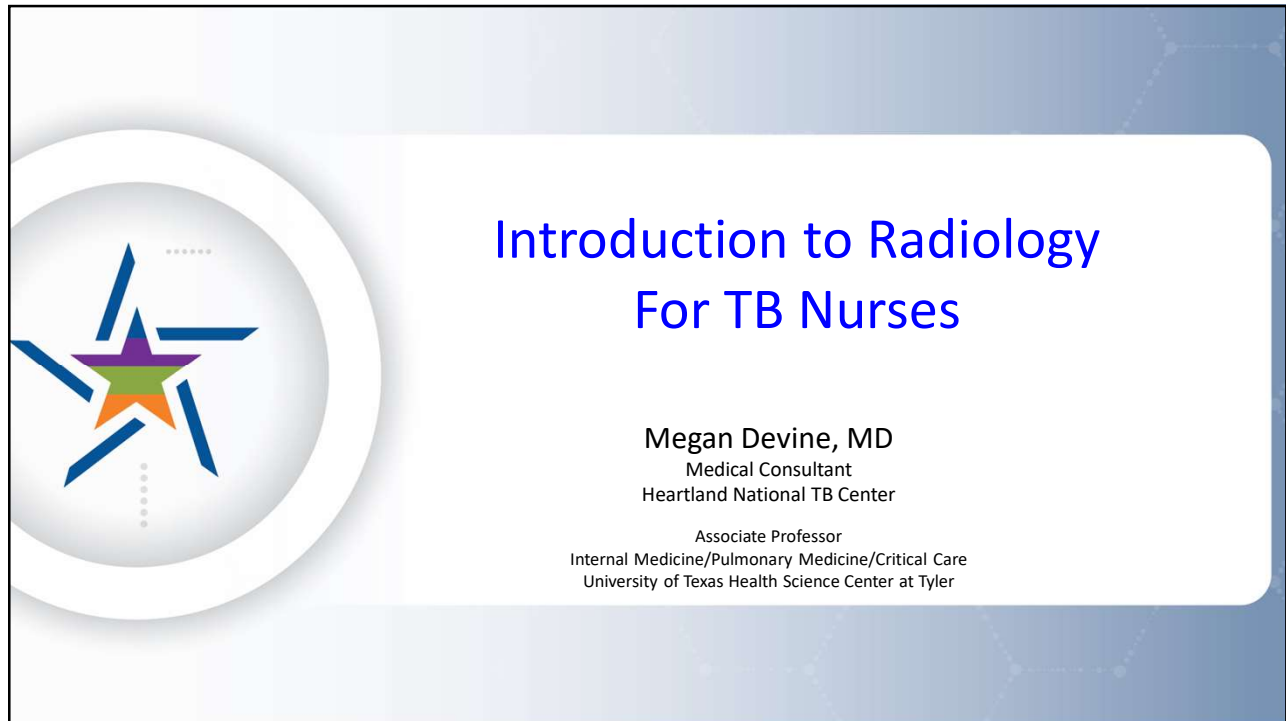




1

This is a presentation slide with a light blue background and a subtle geometric pattern. On the left side, there is a large white circle containing a stylized star logo with blue, green, and orange segments. The main title, "Chest Radiology in TB", is centered in a large blue font. Below the title, there is a bulleted list of four points in black font. The slide is numbered "2" in the bottom left corner.

Chest Radiology in TB

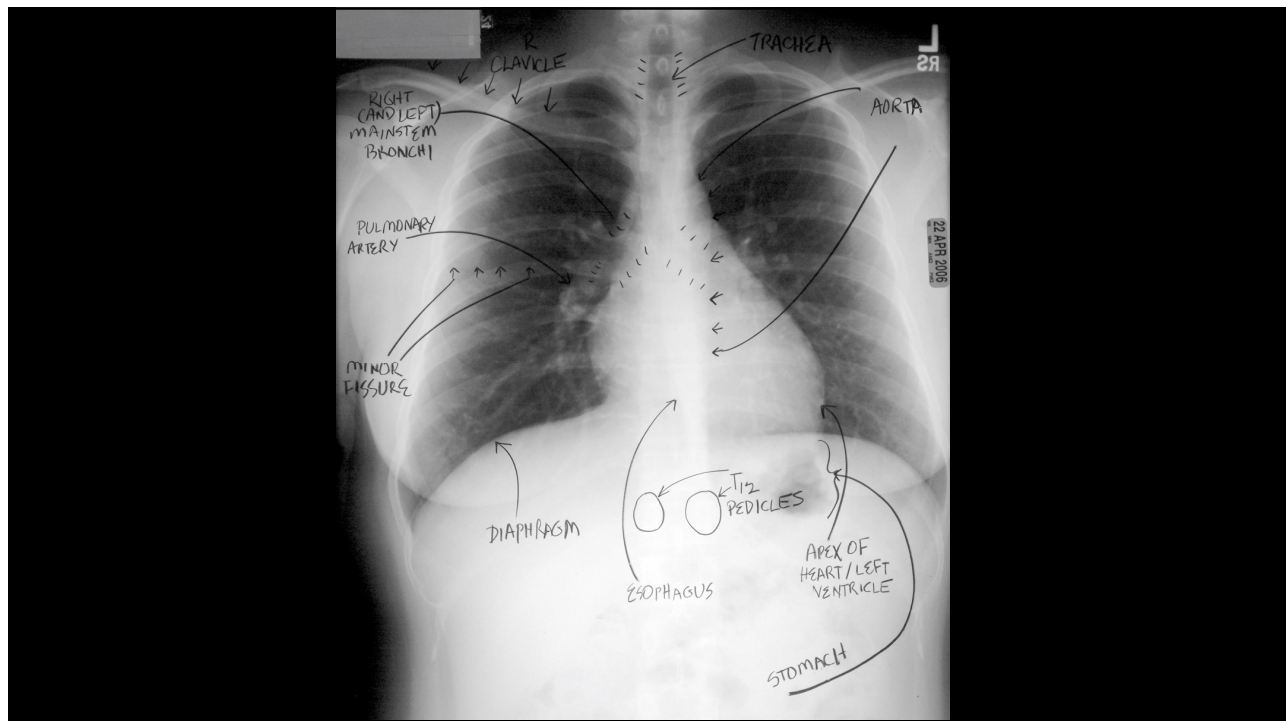
- X-Rays penetrate air, absorbed by fluids/solids
- Chest radiographs show us shadows of organs and structures in the chest
- Interpretation of a chest radiograph is pattern recognition that requires clinical correlation for true diagnosis
- To know what "abnormal" looks like, you have to know what "normal" looks like

2

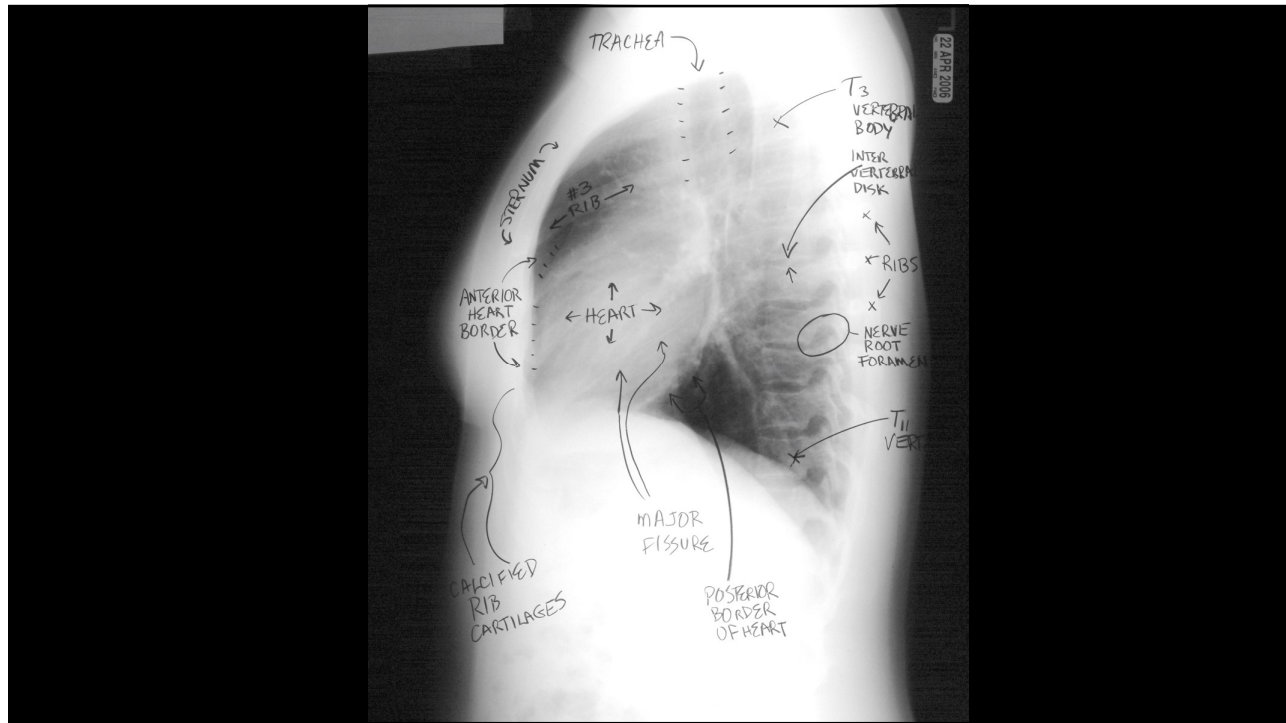
Chest Radiology Basics

- Dark/black = Air
- Dense White = Calcium (Bone Density)
- White = Water Density (Everything else)
 - Water
 - Blood
 - Fat
 - Tissue
 - Pus

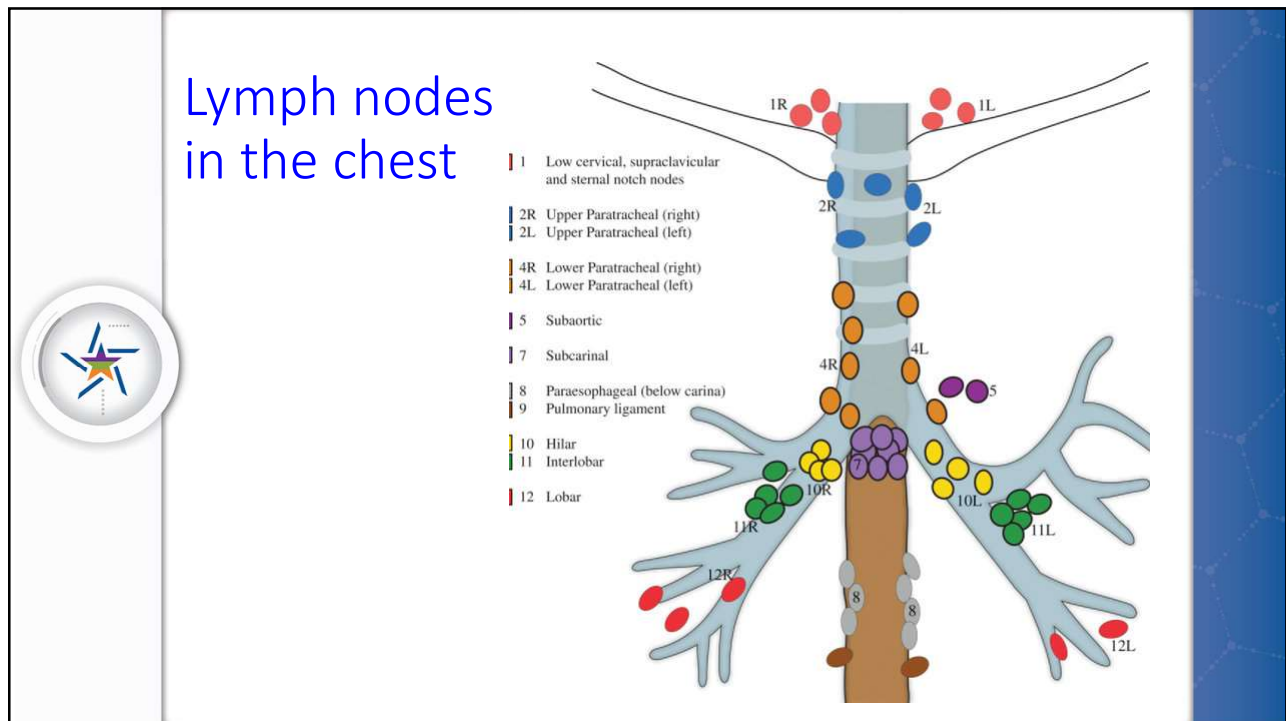
3



4

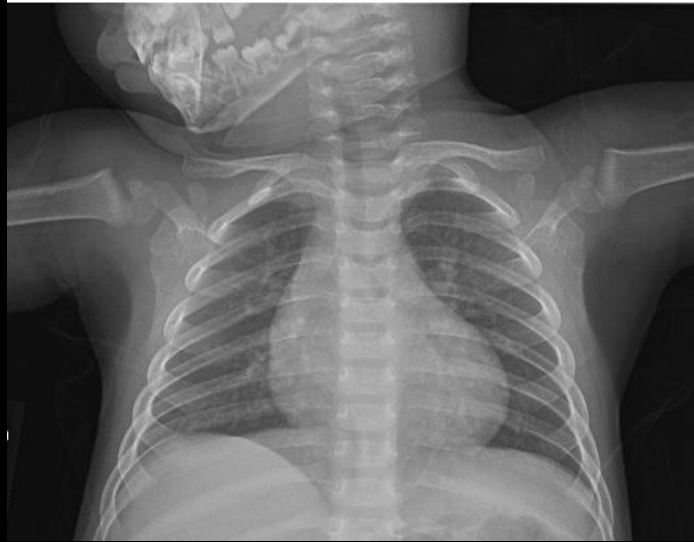

5



6

Normal CXR Child



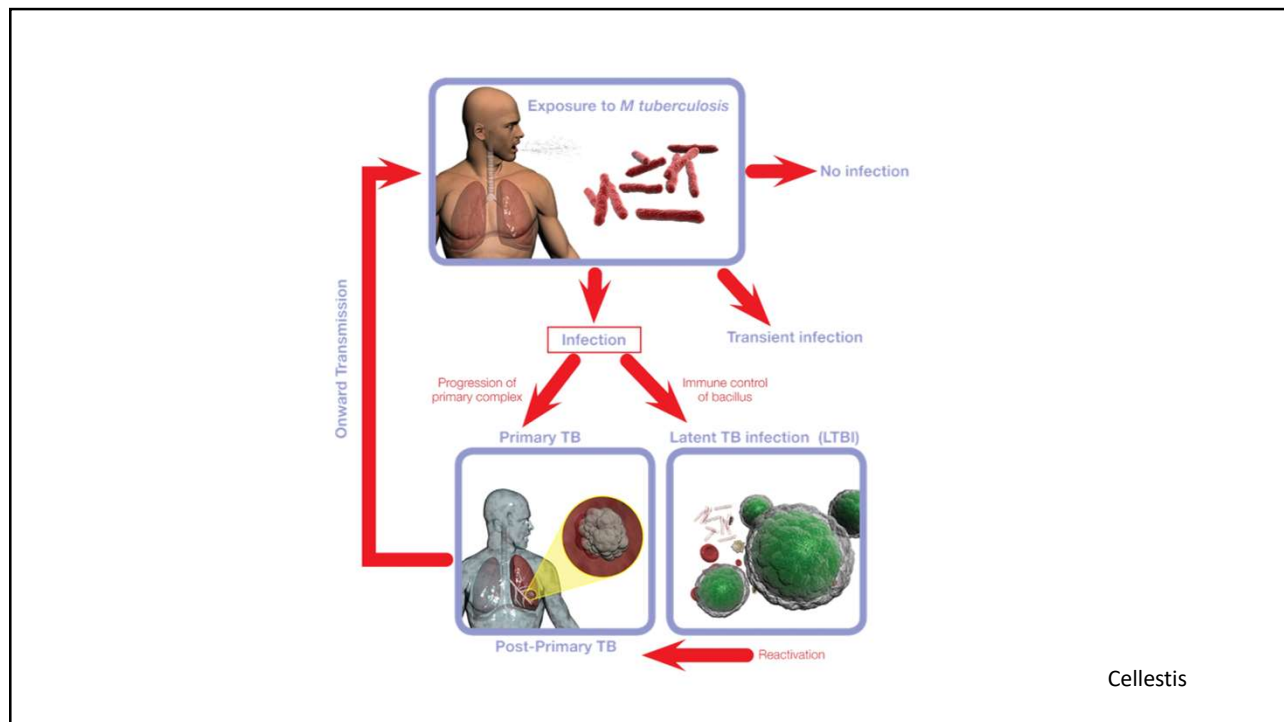
7

Role of CT in the Diagnosis of TB

- CT is not the primary radiologic diagnostic test for TB (CT is overused in the US)
- Usually don't need CT for cavitory consolidation
- If TB is a possible diagnosis, sputum for AFB should be obtained prior to CT
- In most instances, CT should be reserved for patients in whom the diagnosis is unclear



8

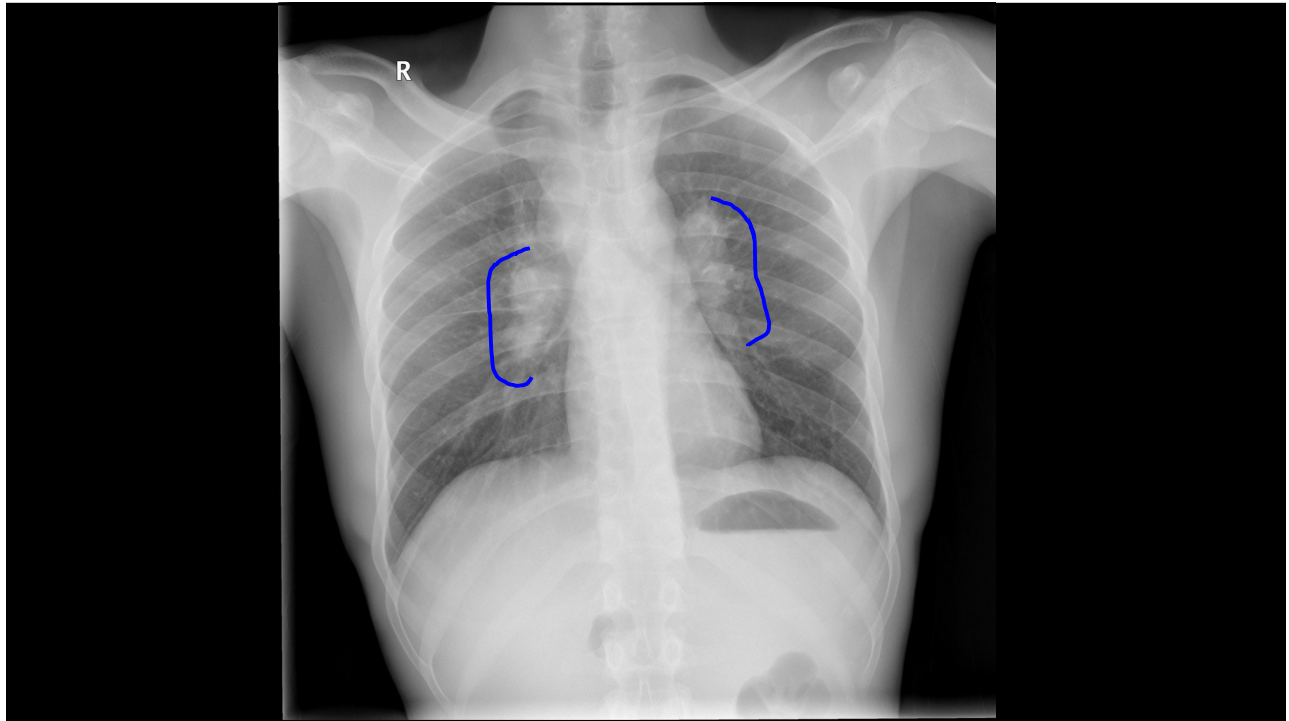


9

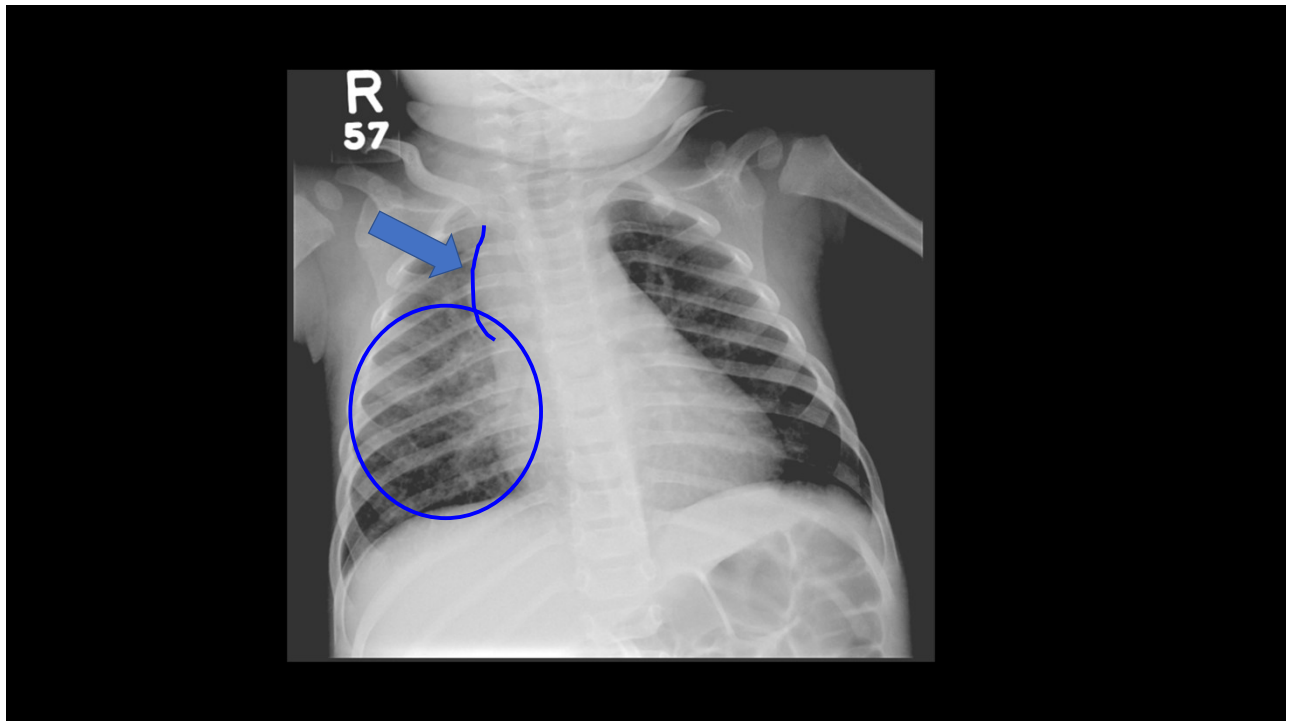
Primary Tuberculosis

- Most commonly in children and immune compromised patients
- Opacities are seen the in middle and lower lungs; commonly unilateral, bilateral 15%
- Hilar or paratracheal lymphadenopathy with or without infiltrates is characteristic.
- Lymph node enlargement may cause bronchial compression
- Pleural effusion (25% can occur in primary disease)

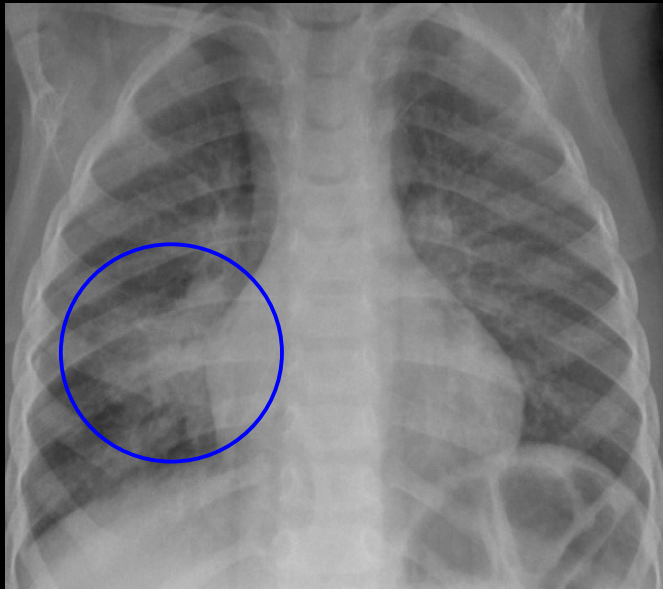
10



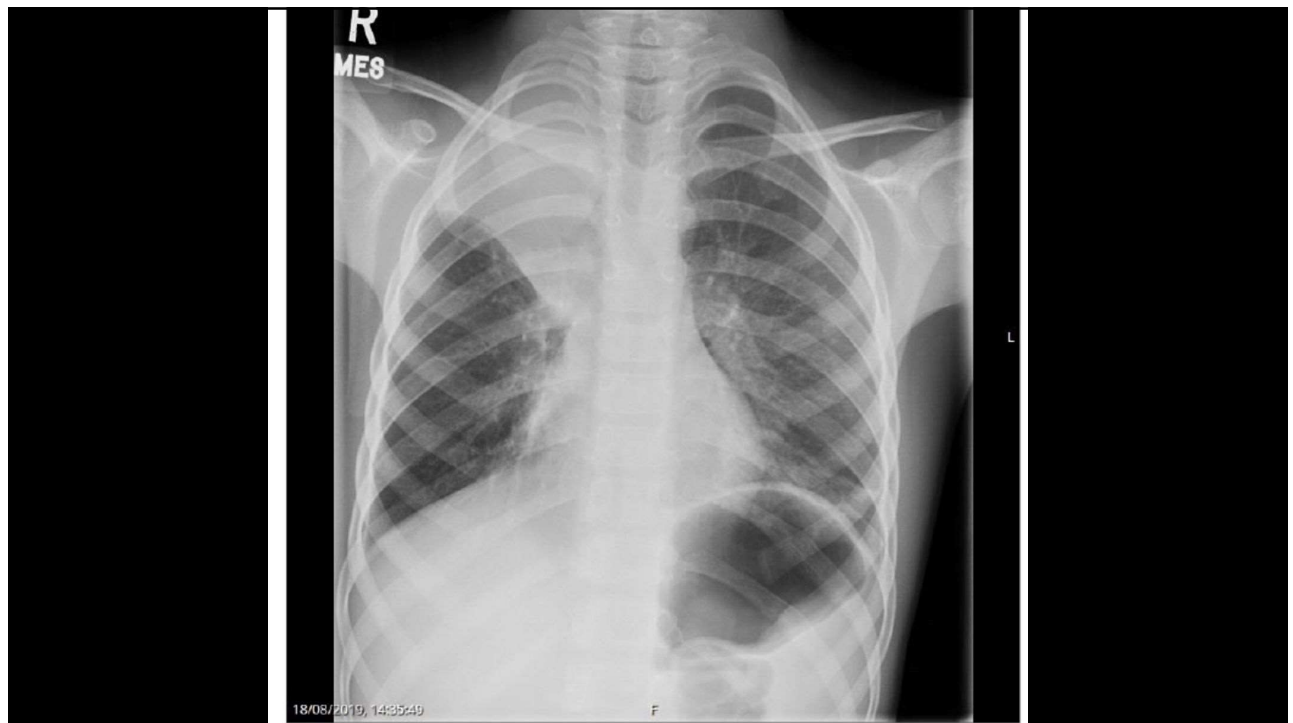11



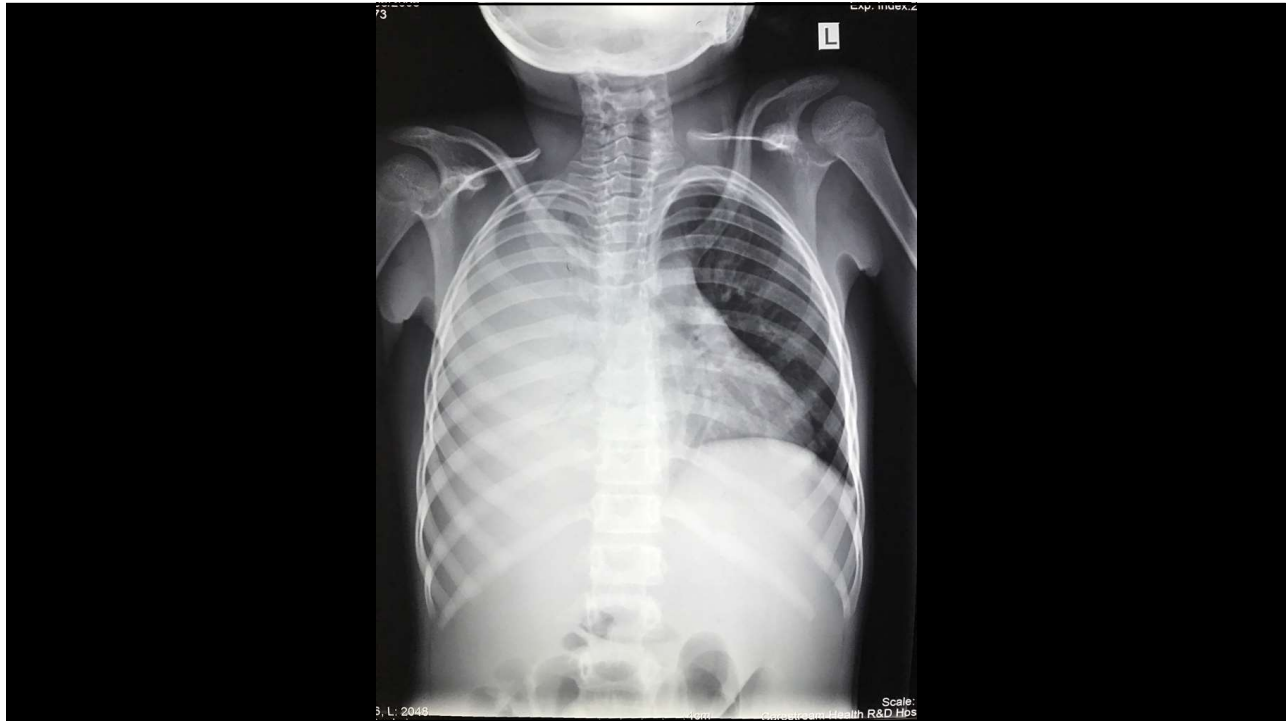12



13



14



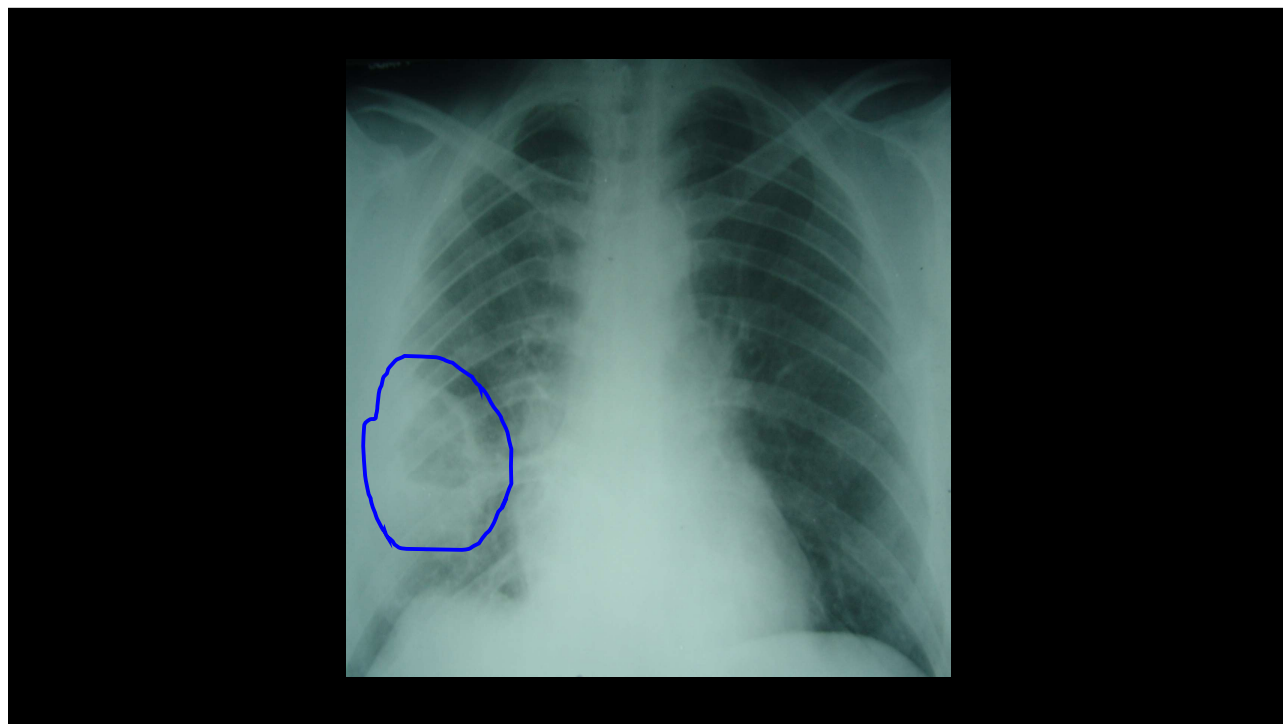
15

Post Primary, Reactivation Tuberculosis

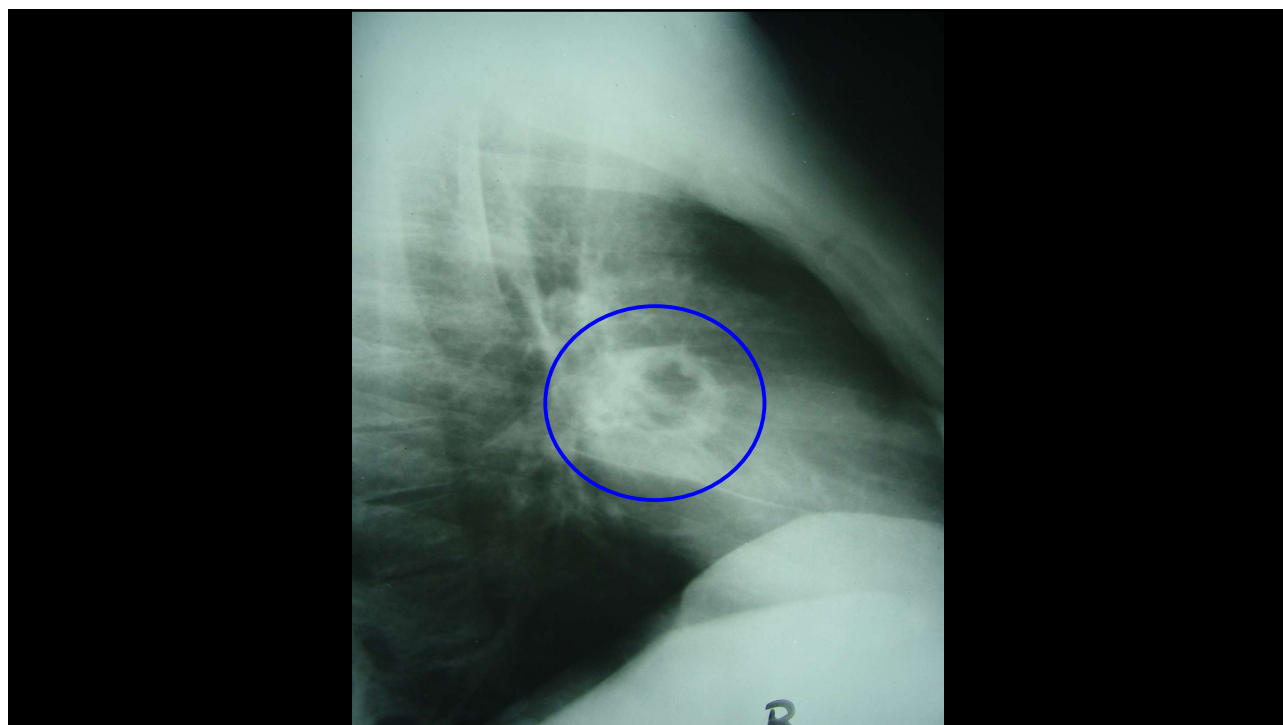
- Characterized by upper lobe predilection, cavitation and absence of lymphadenopathy.
- Cavitation is the hallmark; can also see parenchymal disease (consolidation), hematogenous dissemination (miliary), bronchogenic spread (tree-in-bud) and pleural disease.
- Fibrosis and calcification are seen after healing.



16



17



18

Millet Seeds



Slender plant, 1-15 feet

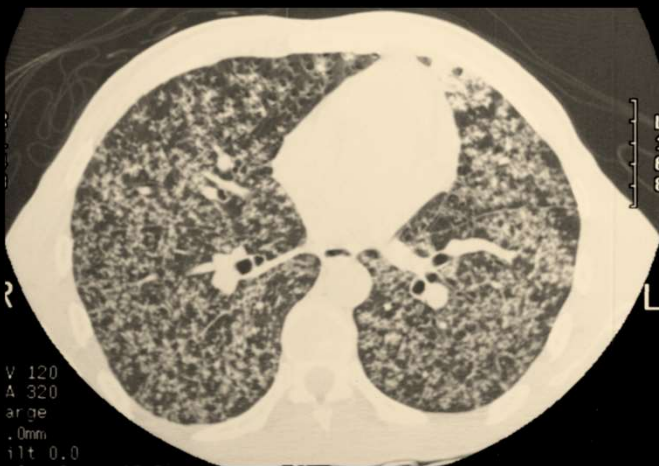Seeds ~ 2-3 mm in diameter

Africa and India

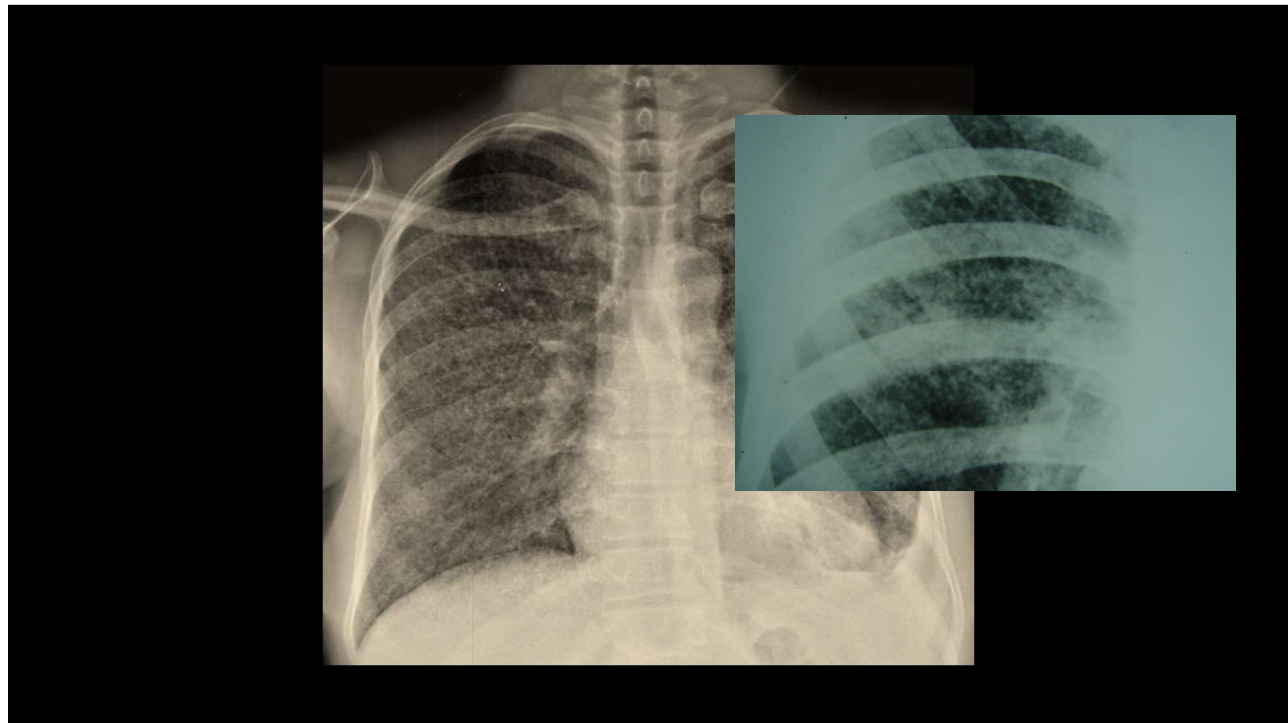


19

Milliary TB



20



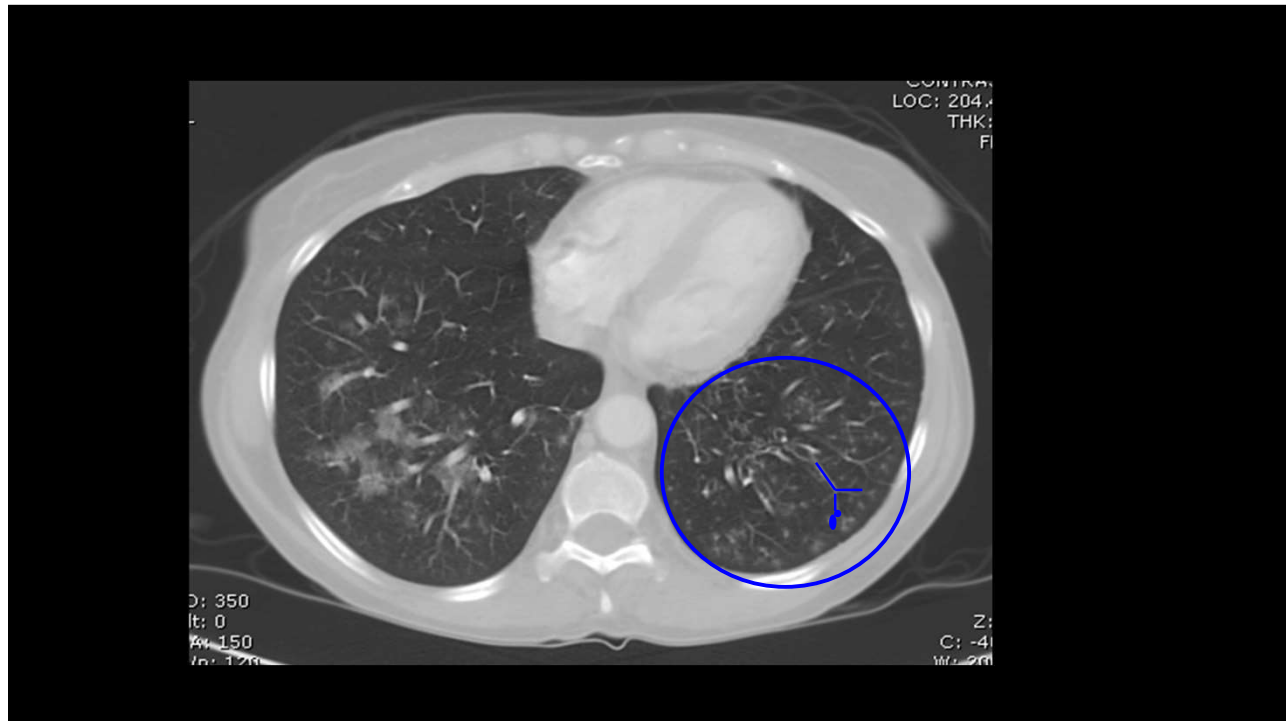21

Tree in Bud.....



<http://www.jellosalad.com/pic/favorites/index.html>

22



23

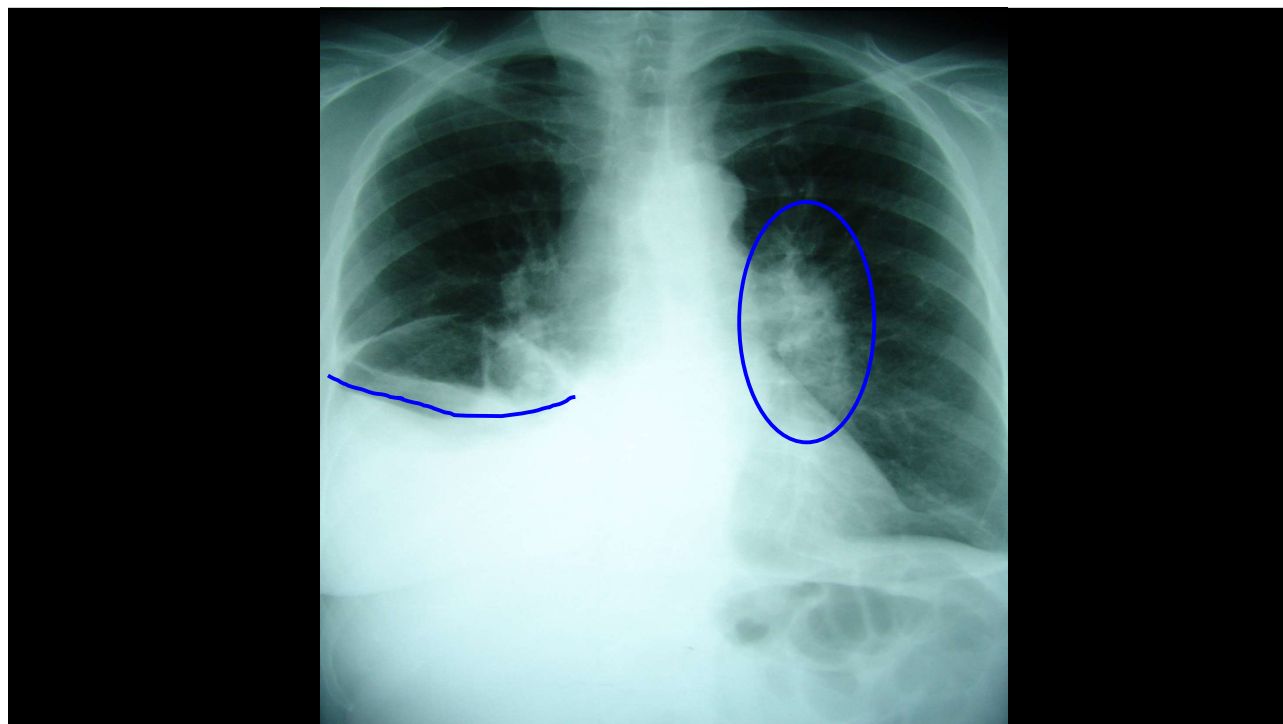
Pleural Effusions

- Primary TB (25%)
- Hypersensitivity reaction to TB proteins
- Organisms uncommonly isolated from fluid
- May not be associated with obvious parenchymal disease on CXR

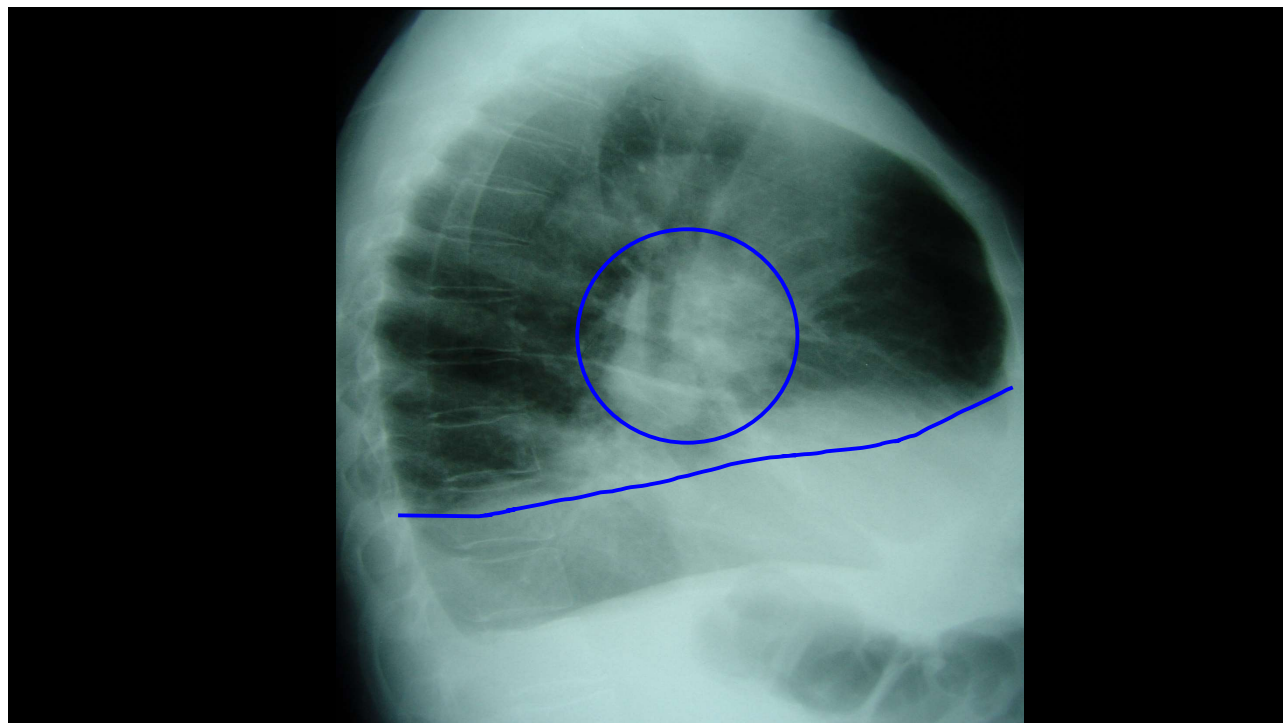


24

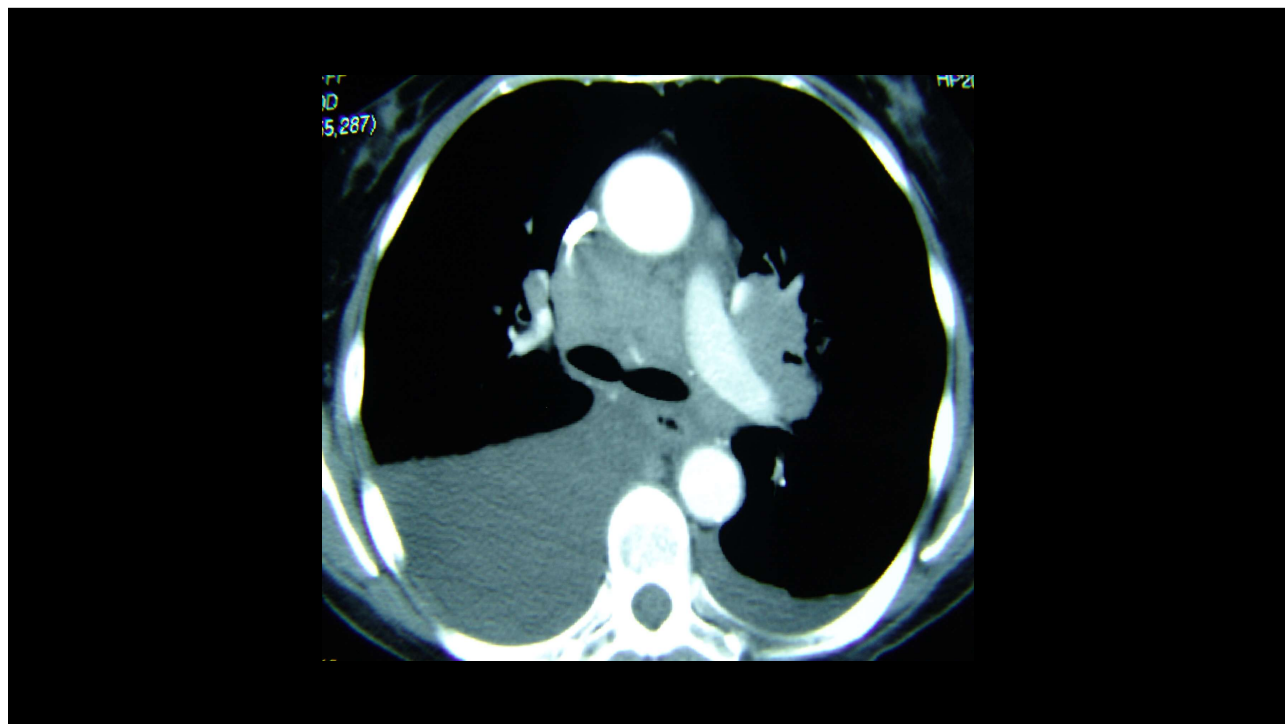
24



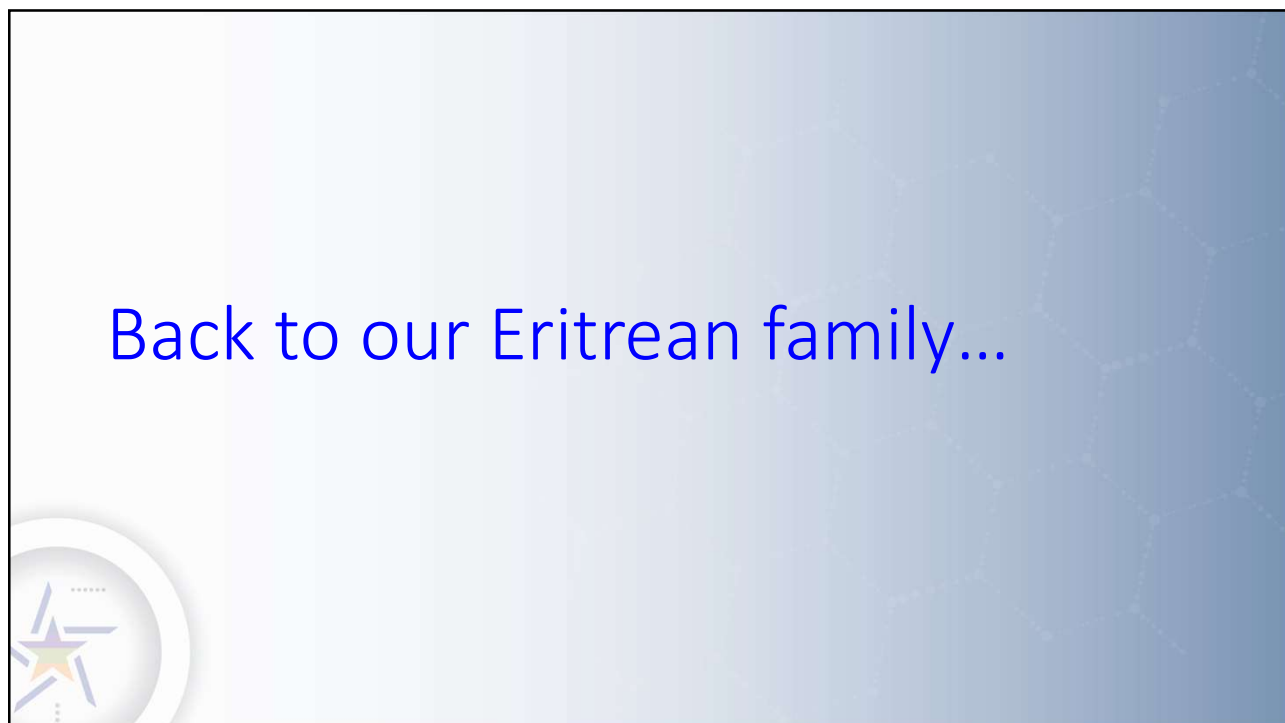25



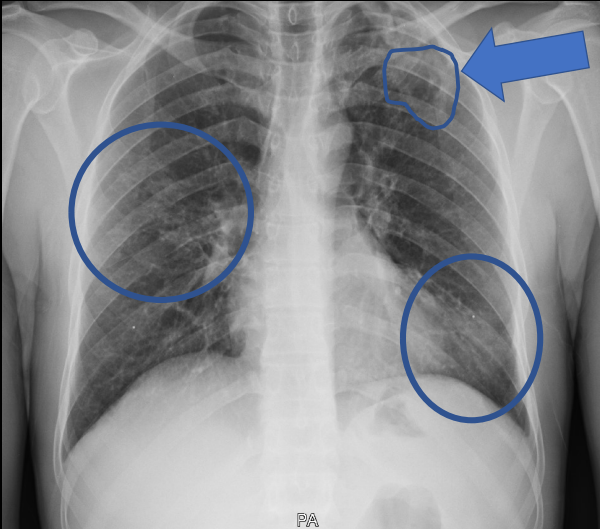
26



27



28





May 2019

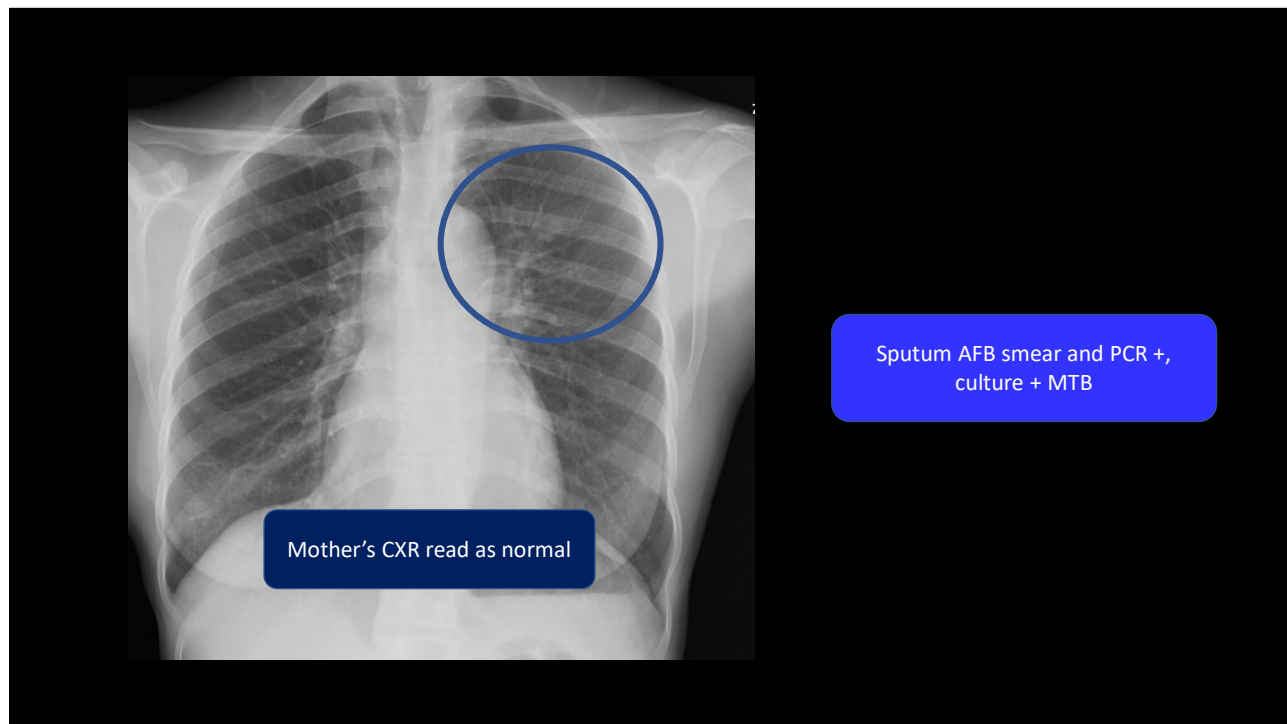
37 year old African man
4 months of cough, weight
loss, and poor energy

29

Chest xray is one piece of the TB puzzle




30



31

Chest Radiology in TB

- Interpretation of a chest radiograph is pattern recognition that requires clinical correlation for true diagnosis



32

