



Introduction to Radiology For TB Nurses

Megan Devine, MD

February 18, 2025

Essentials of TB Nurse Case Management Online • Tuesdays, February 11 – March 4, 2025 • Online

Megan Devine, MD

Has the following disclosures to make:

- No conflict of interests
- No relevant financial relationships with any commercial companies pertaining to this educational activity





Introduction to Radiology For TB Nurses

Megan Devine, MD

Medical Consultant
Heartland National TB Center

Associate Professor
Internal Medicine/Pulmonary Medicine/Critical Care
University of Texas Health Science Center at Tyler

Chest Radiology in TB

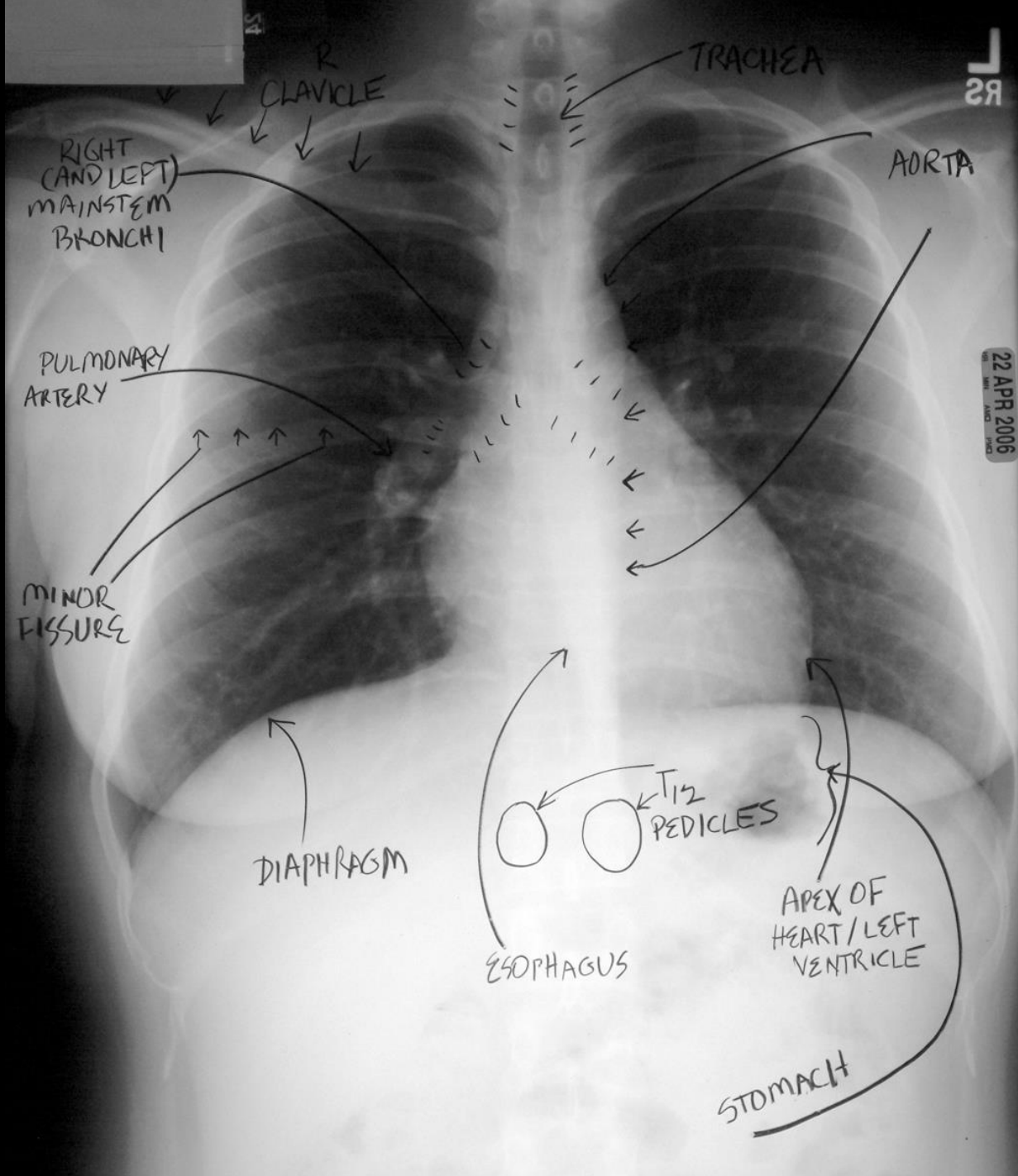
- X-Rays penetrate air, absorbed by fluids/solids
- Chest radiographs show us shadows of organs and structures in the chest
- Interpretation of a chest radiograph is pattern recognition that requires clinical correlation for true diagnosis
- To know what “abnormal” looks like, you have to know what “normal” looks like



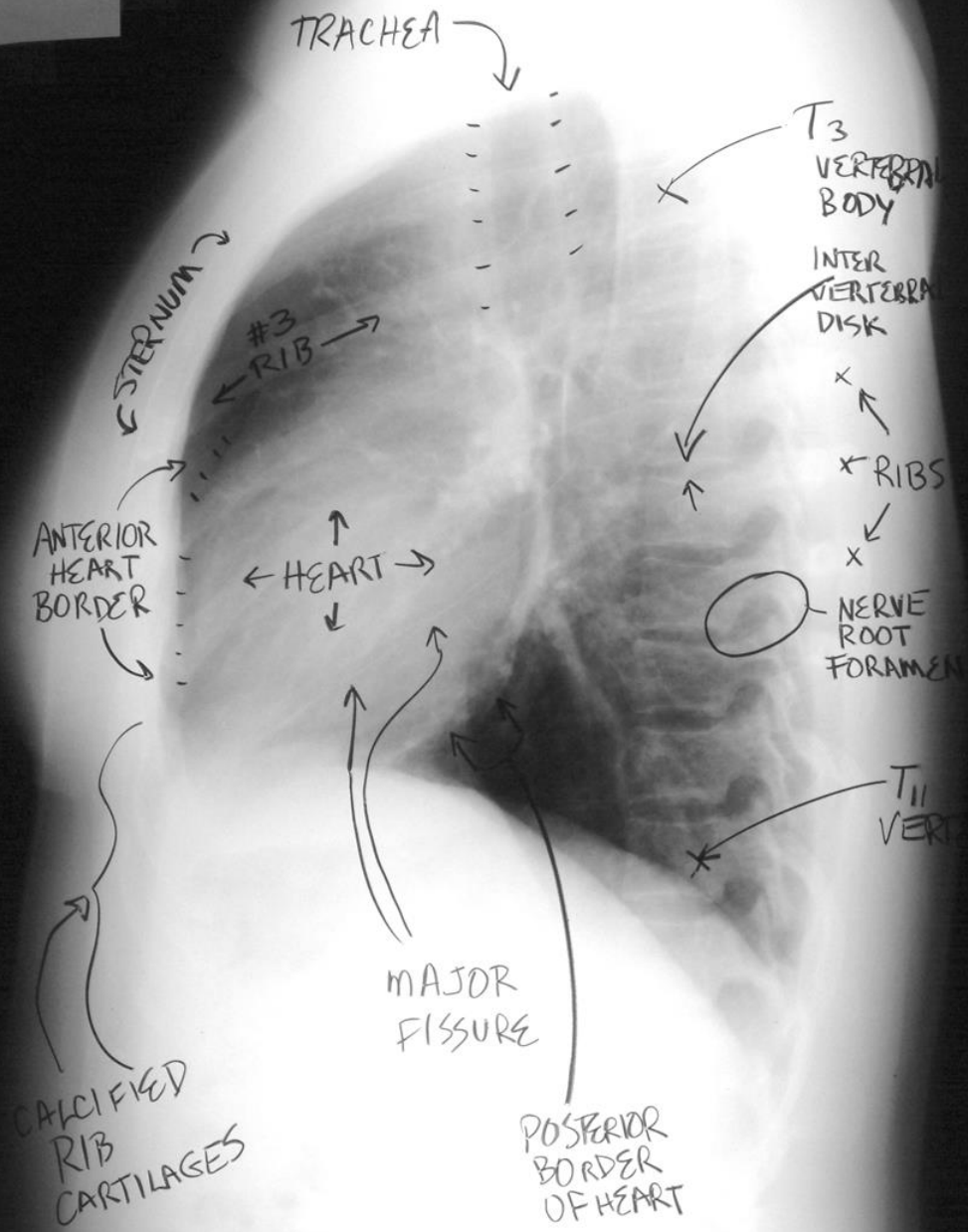
Chest Radiology Basics

- Dark/black = Air
- Dense White = Calcium (Bone Density)
- White = Water Density (Everything else)
 - Water
 - Blood
 - Fat
 - Tissue
 - Pus

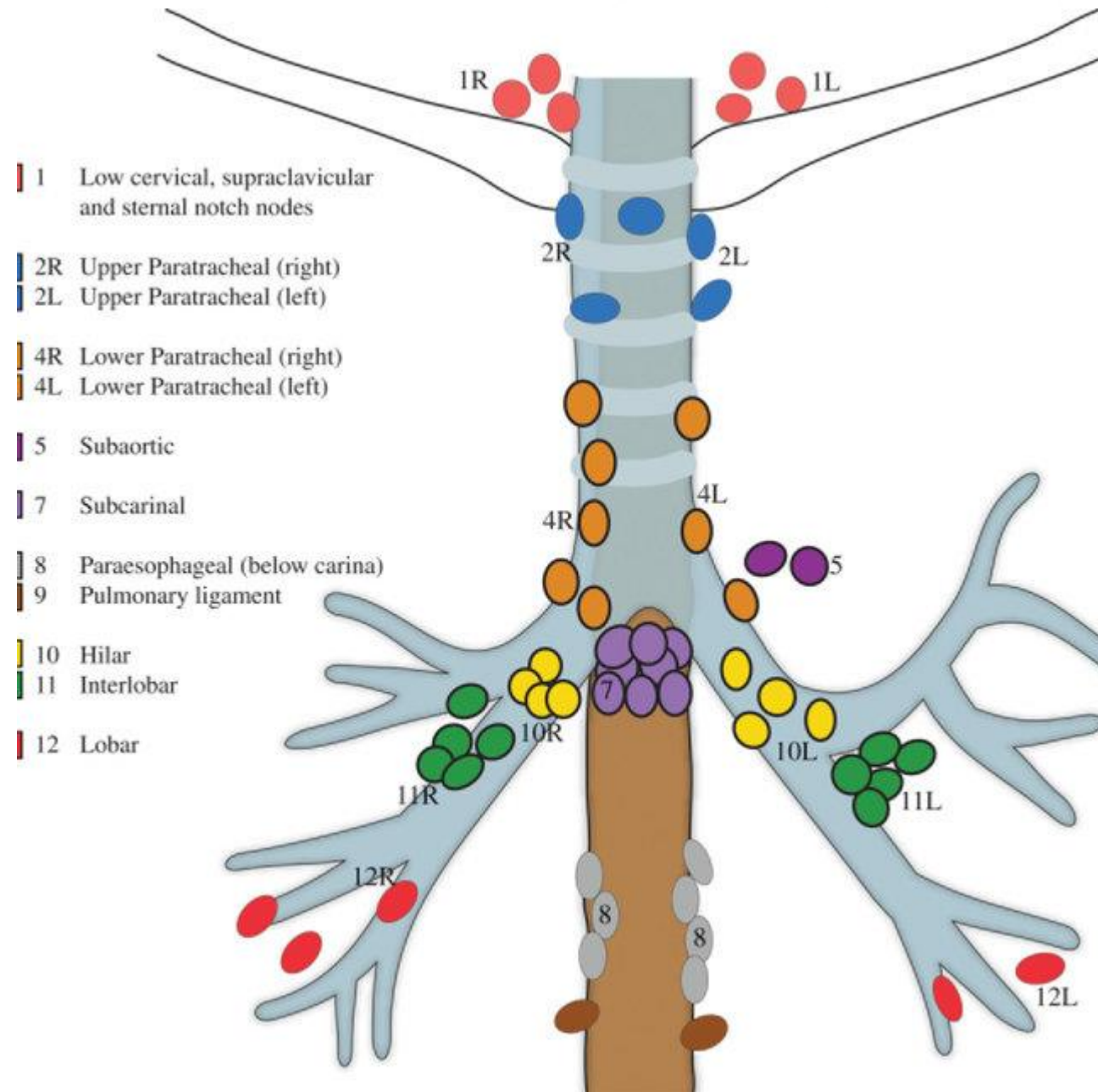




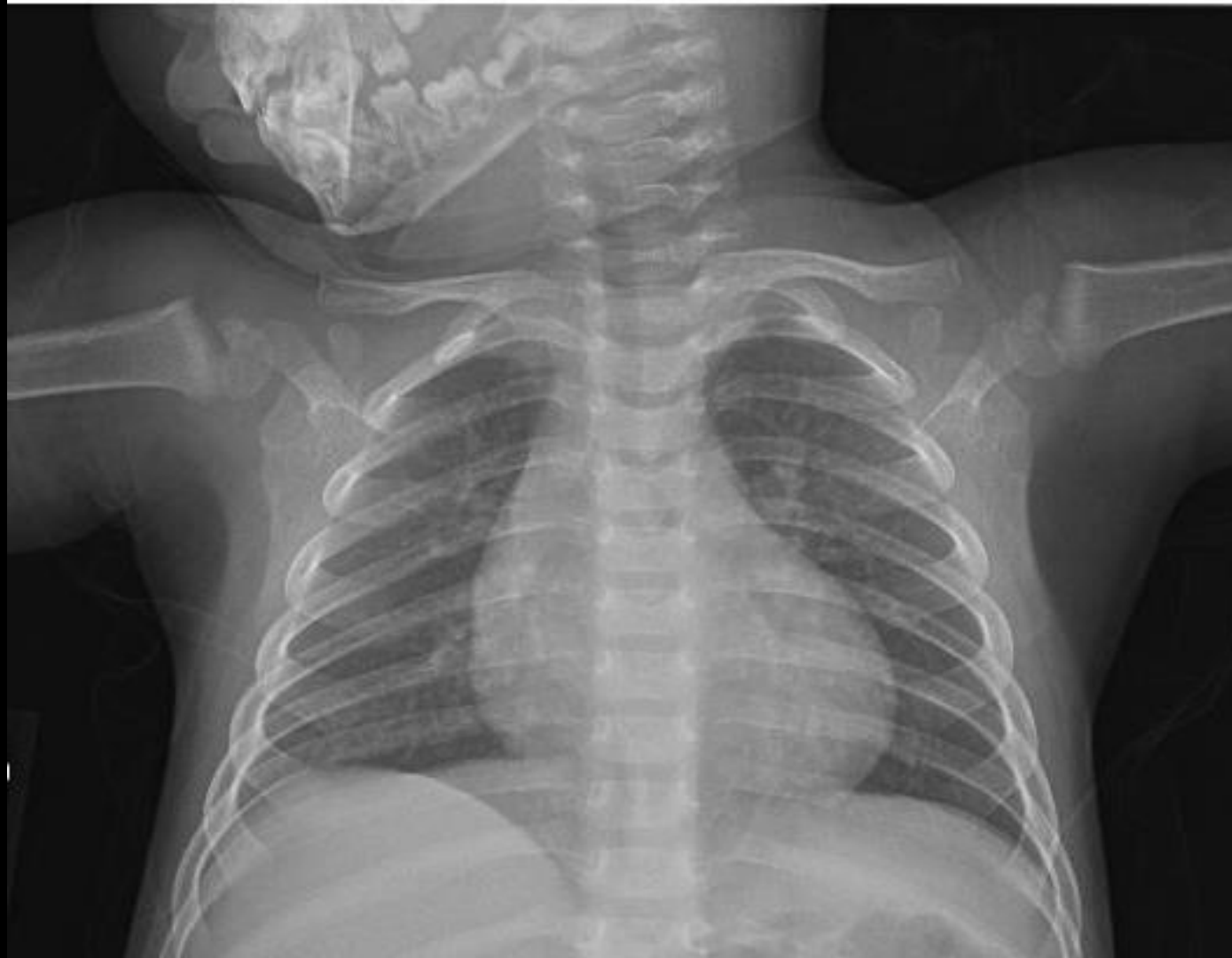22 APR 2006



Lymph nodes in the chest



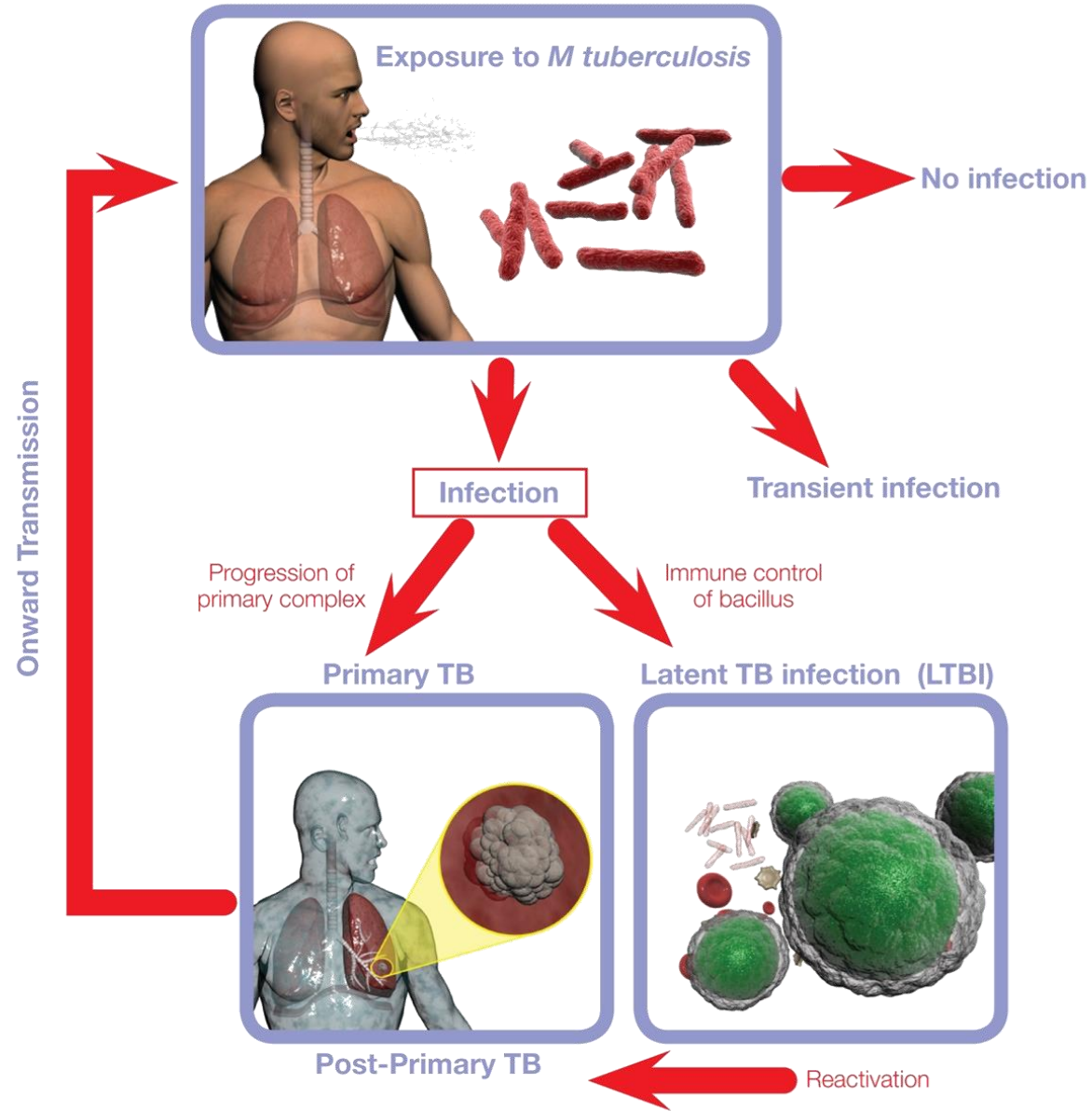
Normal CXR Child



Role of CT in the Diagnosis of TB

- CT is not the primary radiologic diagnostic test for TB (CT is overused in the US)
- Usually don't need CT for cavitory consolidation
- If TB is a possible diagnosis, sputum for AFB should be obtained prior to CT
- In most instances, CT should be reserved for patients in whom the diagnosis is unclear

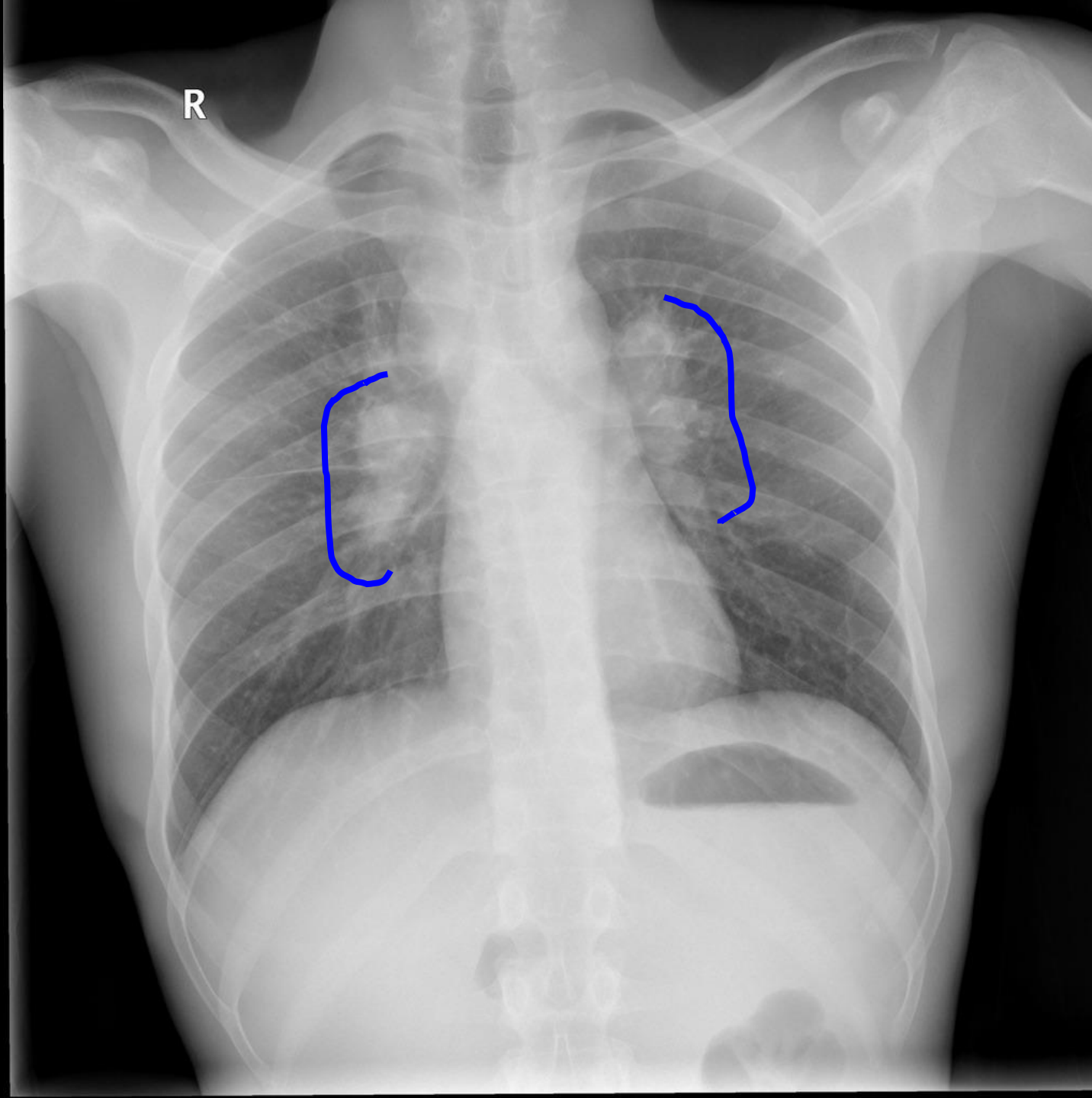


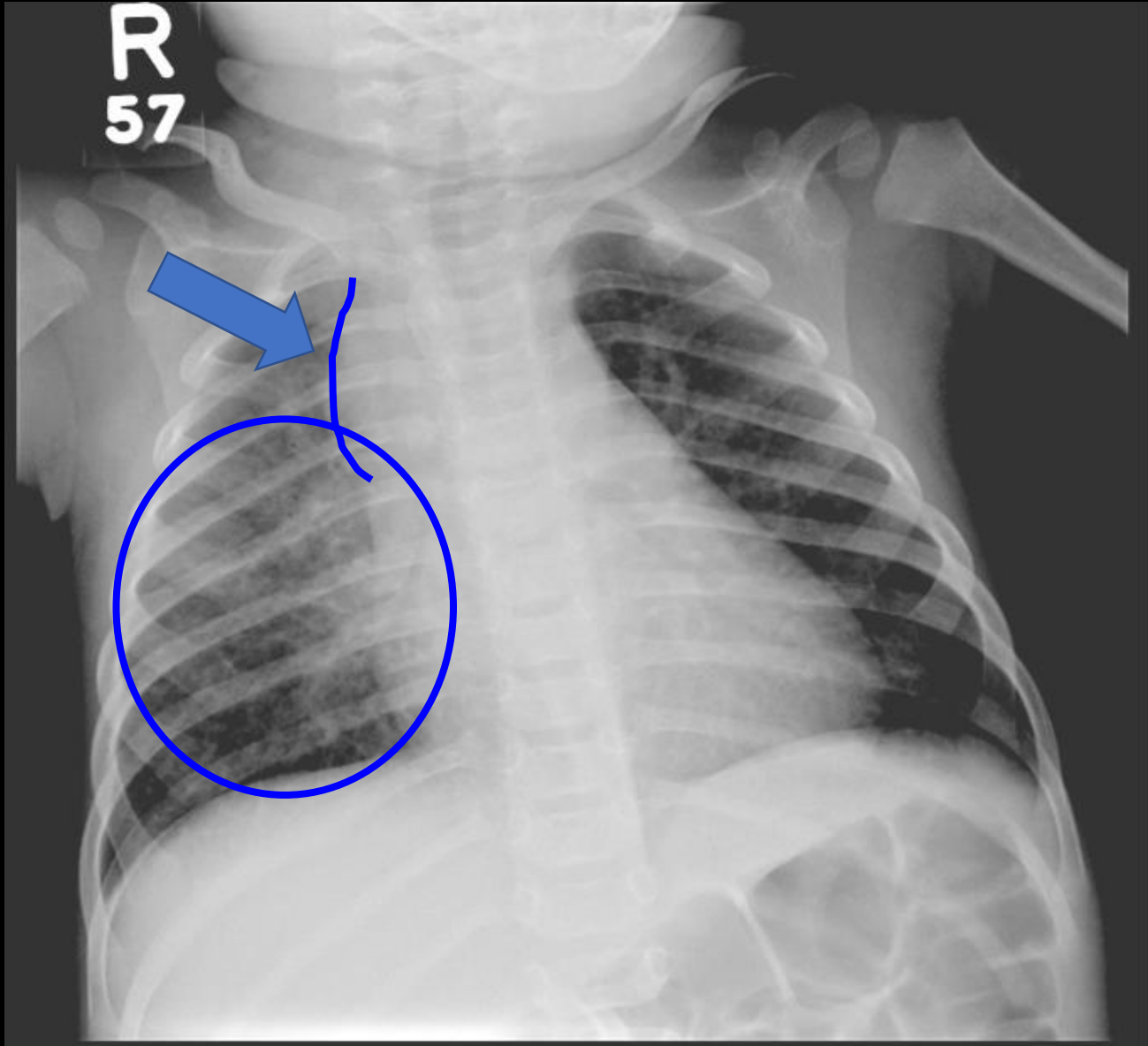


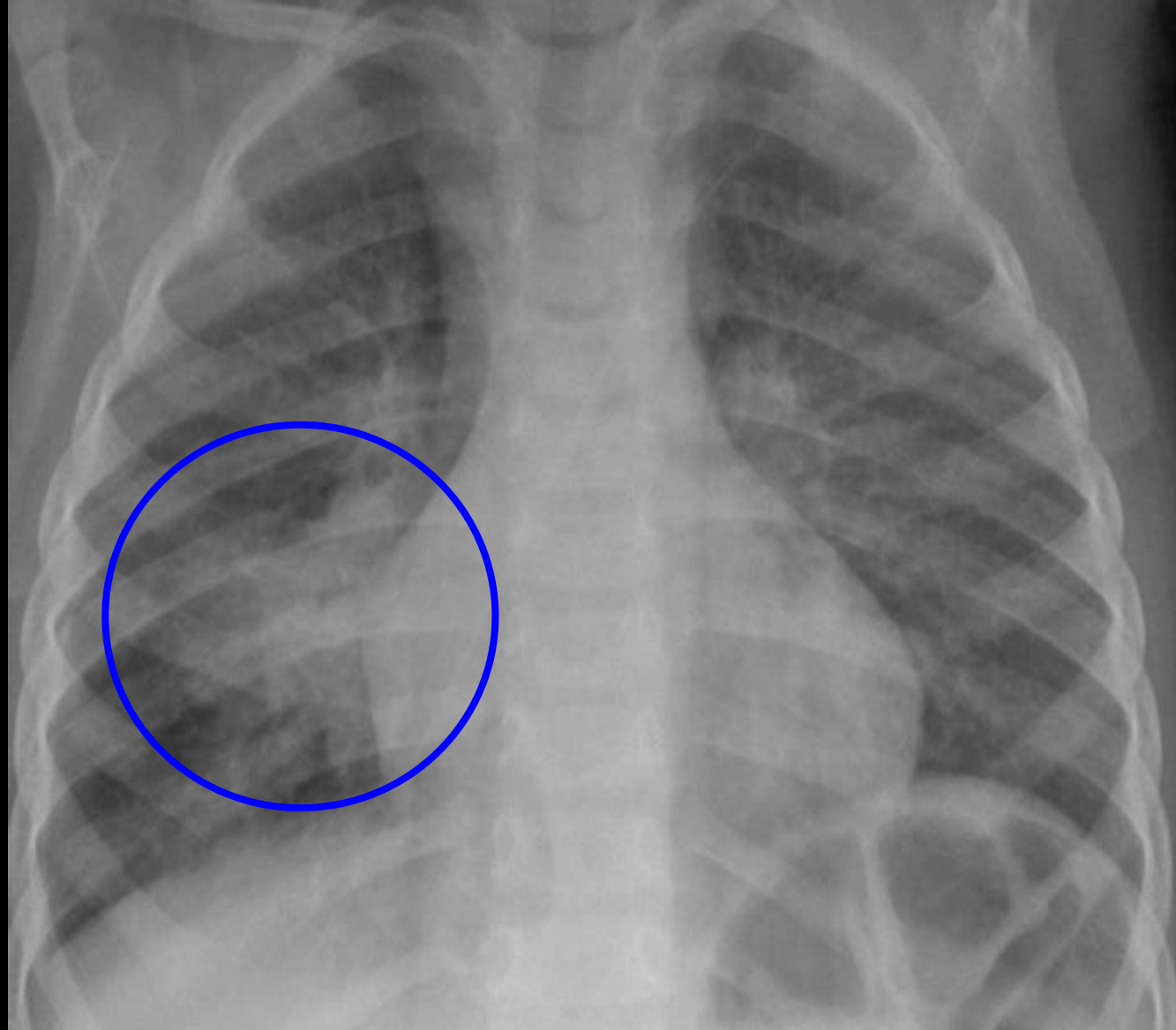
Primary Tuberculosis

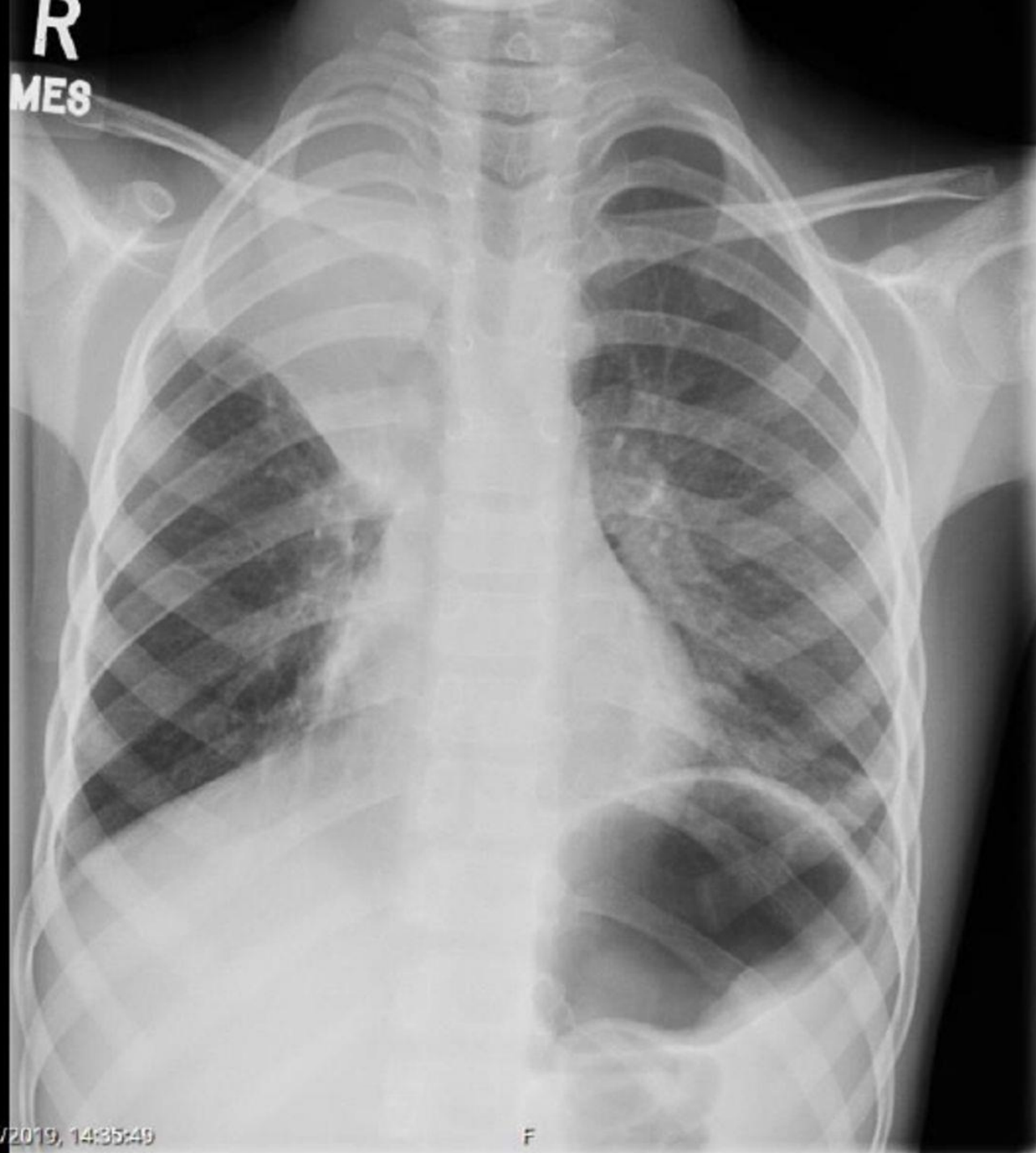
- Most commonly in children and immune compromised patients
- Opacities are seen the in middle and lower lungs; commonly unilateral, bilateral 15%
- Hilar or paratracheal lymphadenopathy with or without infiltrates is characteristic.
- Lymph node enlargement may cause bronchial compression
- Pleural effusion (25% can occur in primary disease)









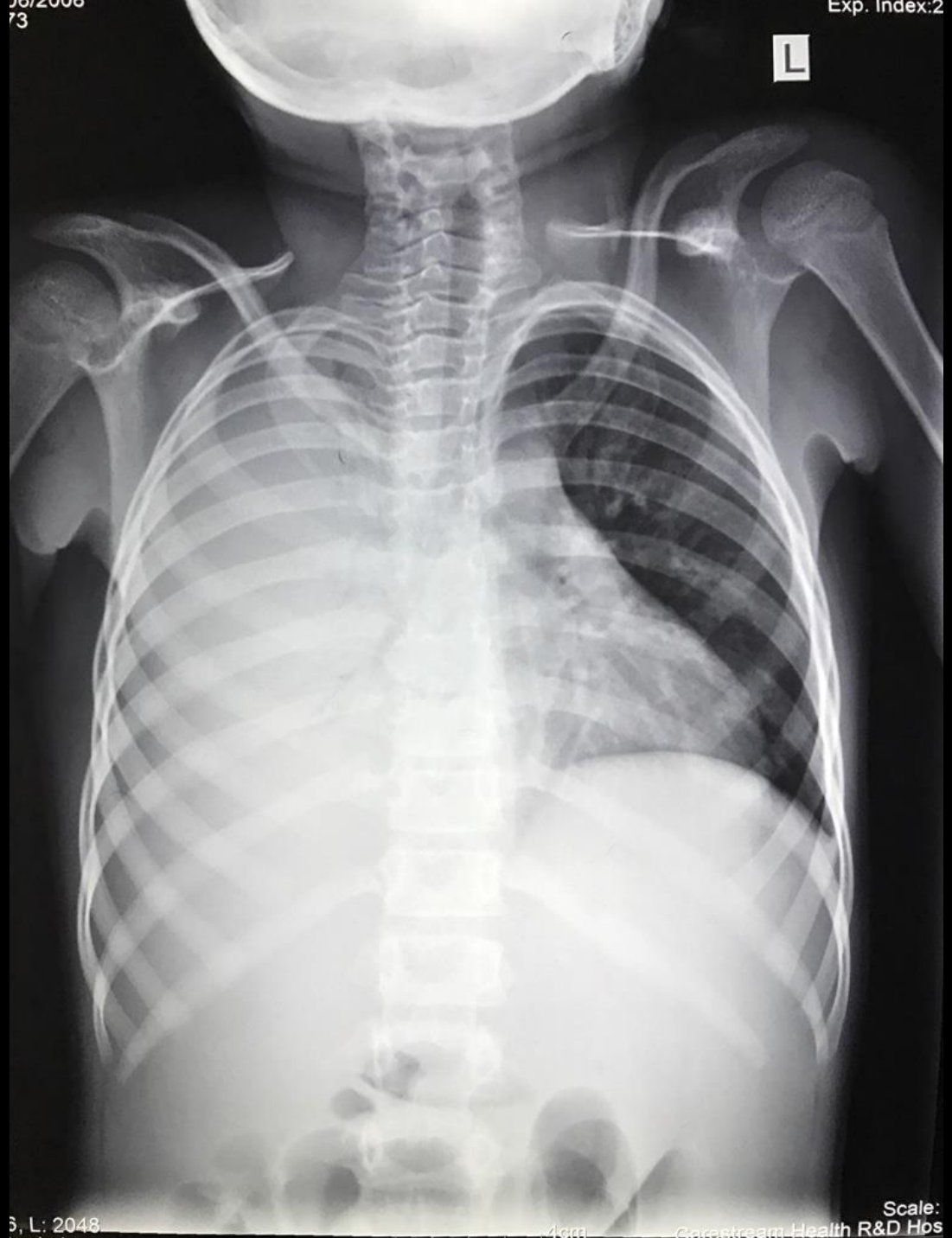

R
MES

L

18/08/2019, 14:35:49

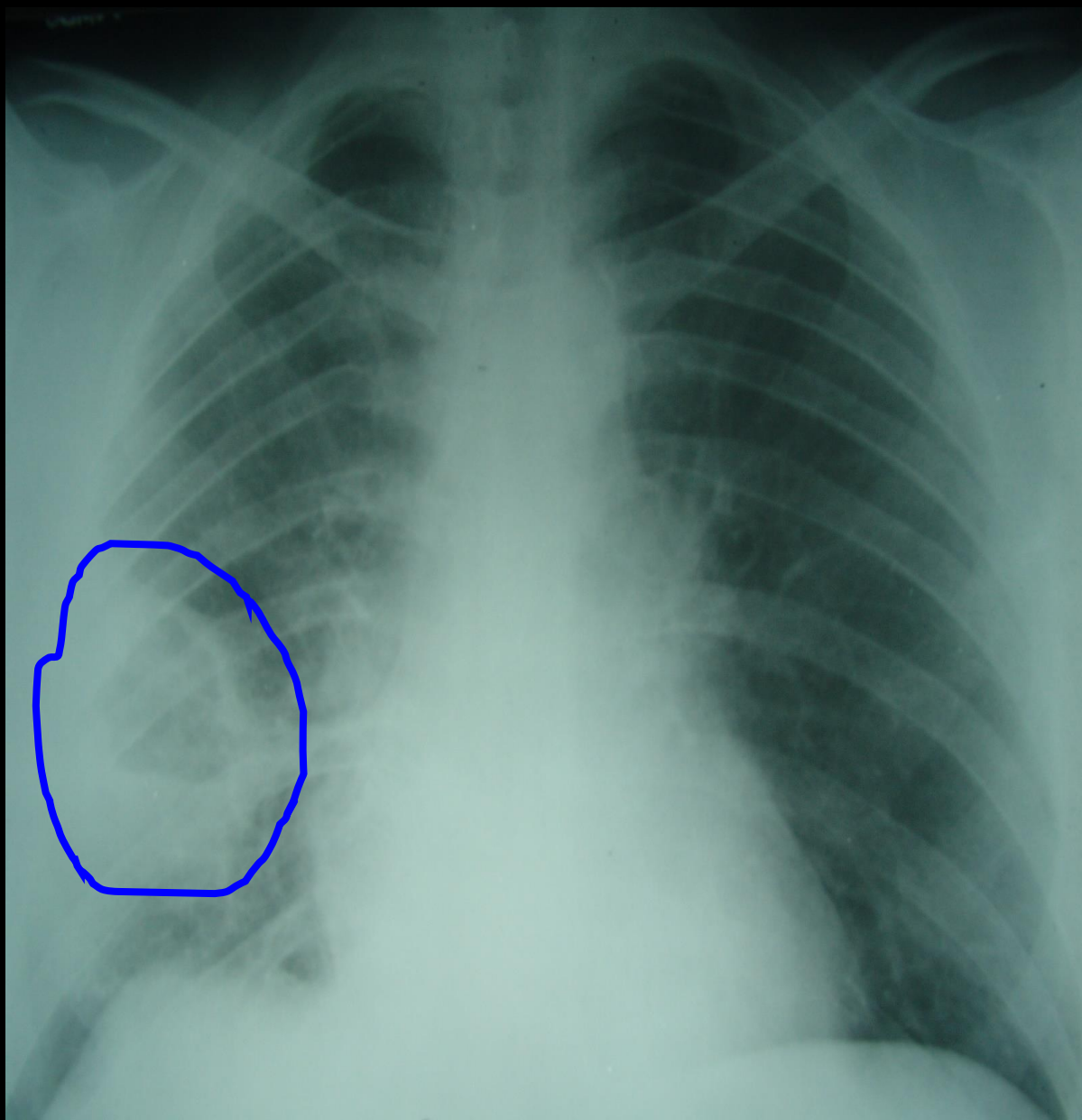
F

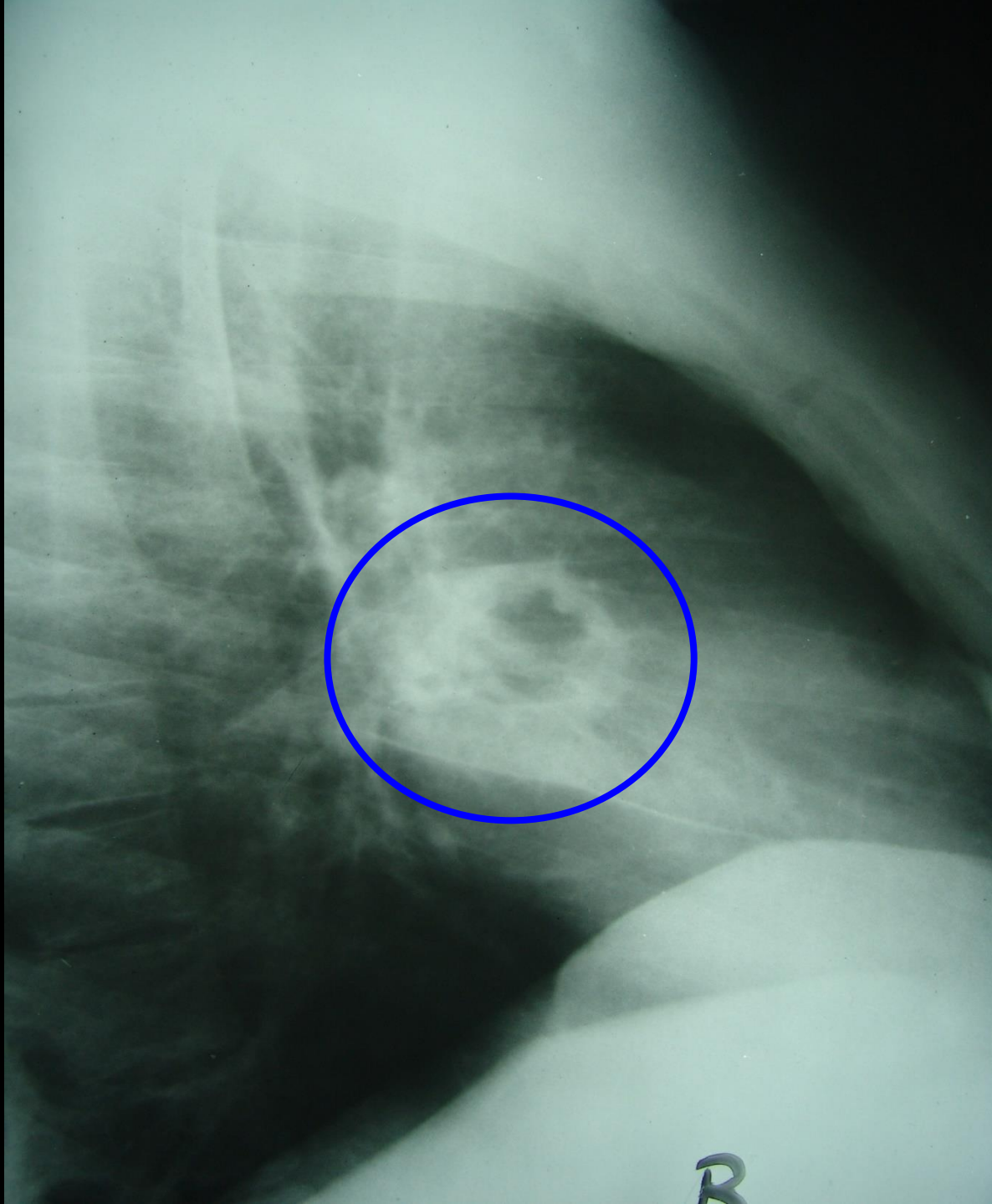


Post Primary, Reactivation Tuberculosis

- Characterized by upper lobe predilection, cavitation and absence of lymphadenopathy.
- Cavitation is the hallmark; can also see parenchymal disease (consolidation), hematogenous dissemination (miliary), bronchogenic spread (tree-in-bud) and pleural disease.
- Fibrosis and calcification are seen after healing.







Millet Seeds

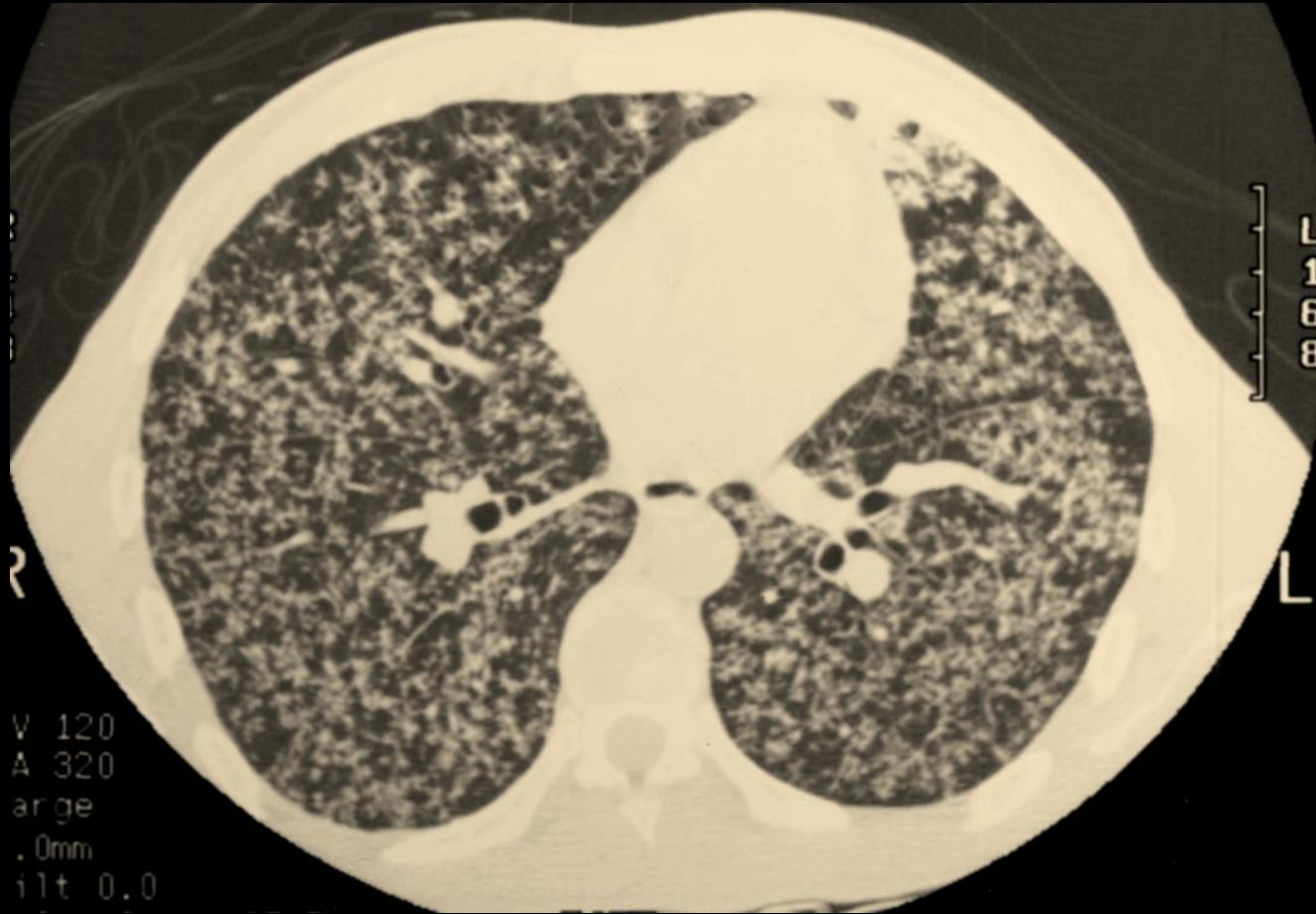Slender plant, 1-15 feet

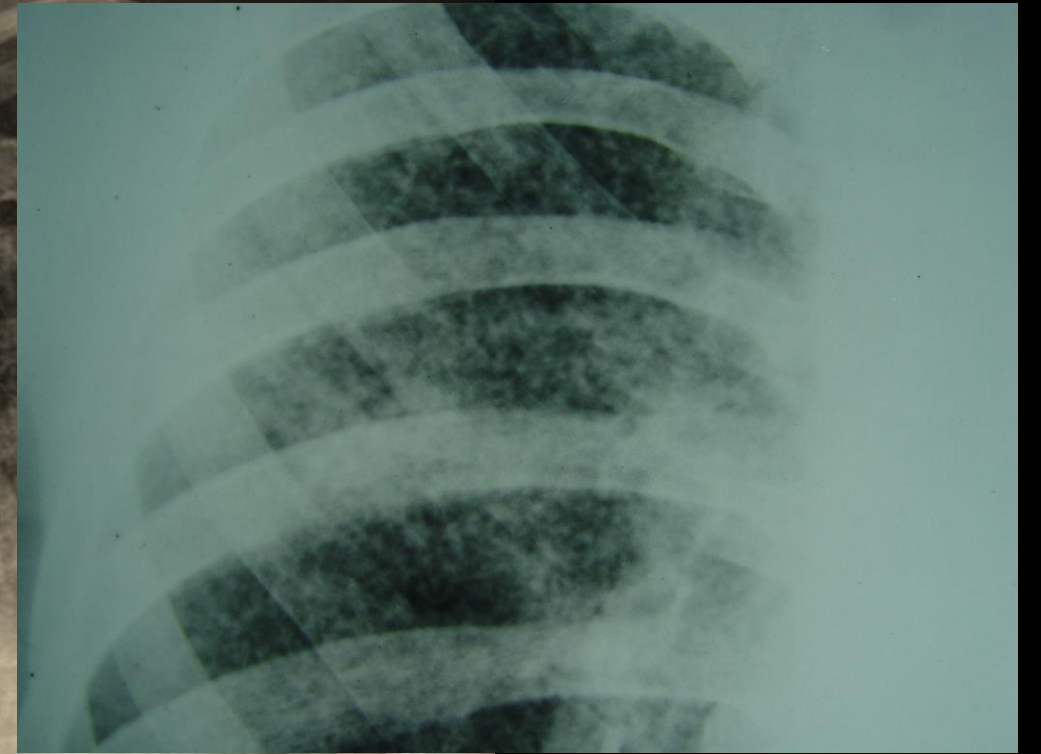
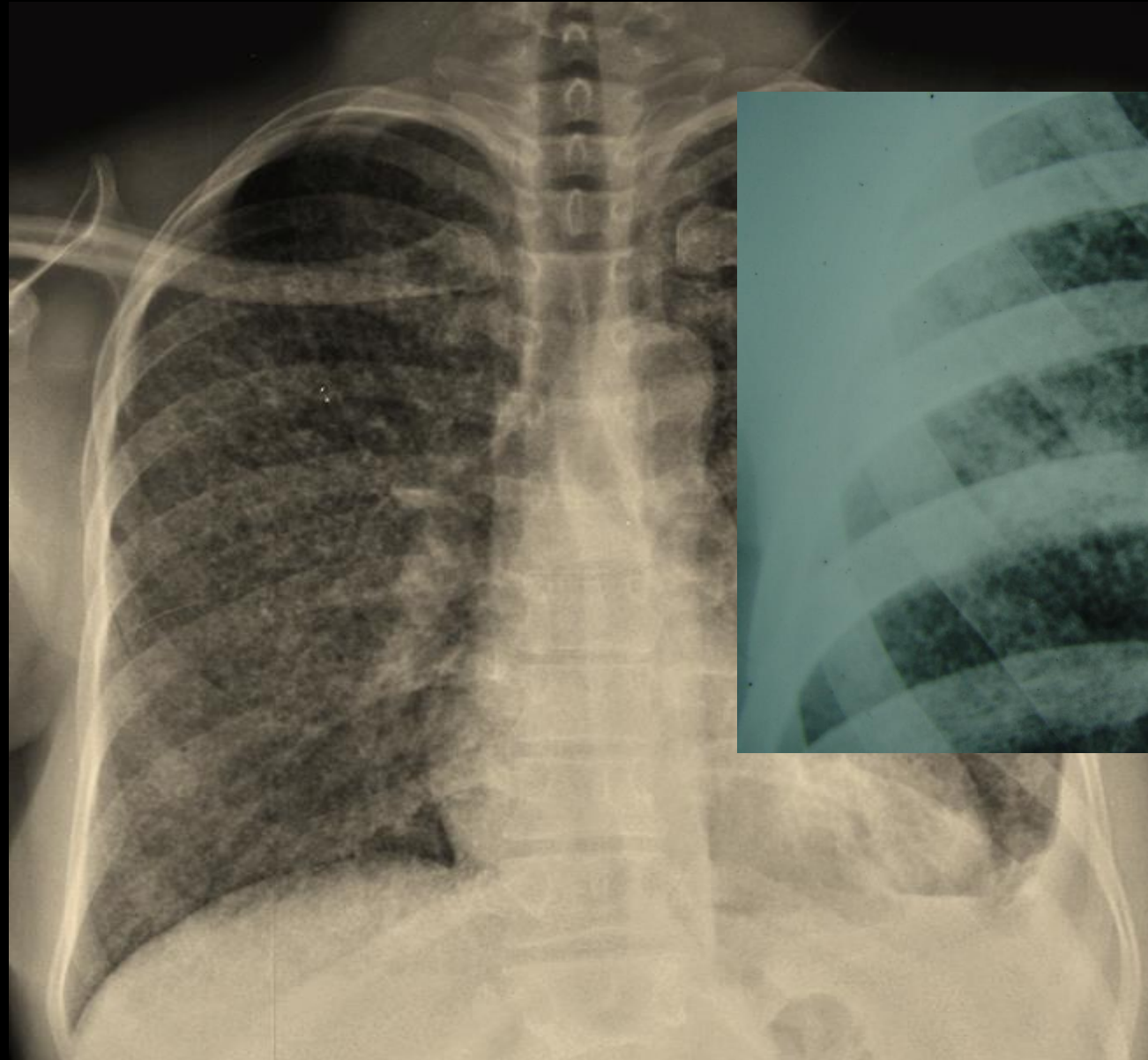
Seeds ~ 2-3 mm in diameter

Africa and India



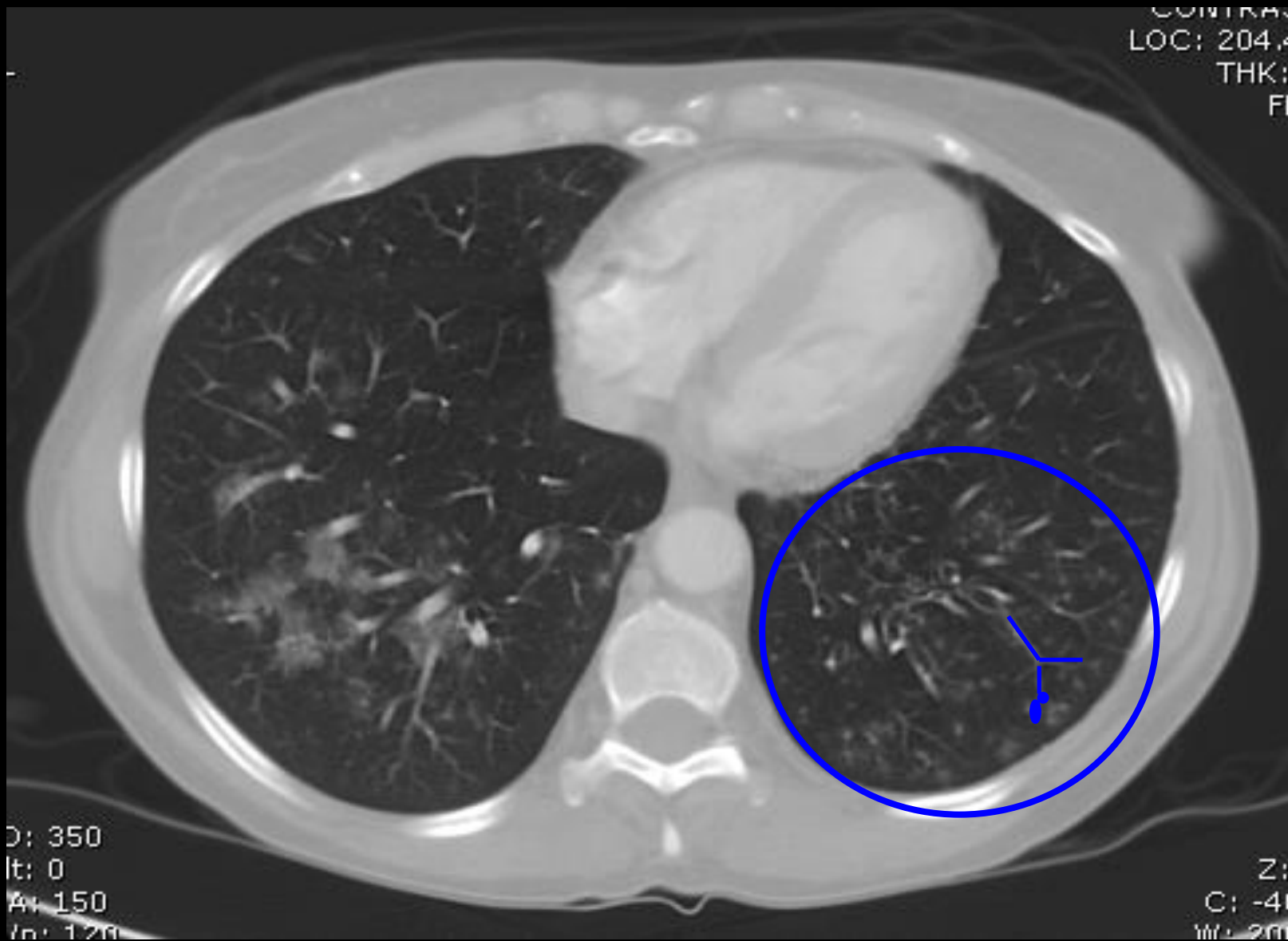
Milliary TB





Tree in Bud.....





CONTRAS
LOC: 204.4
THK:
FI

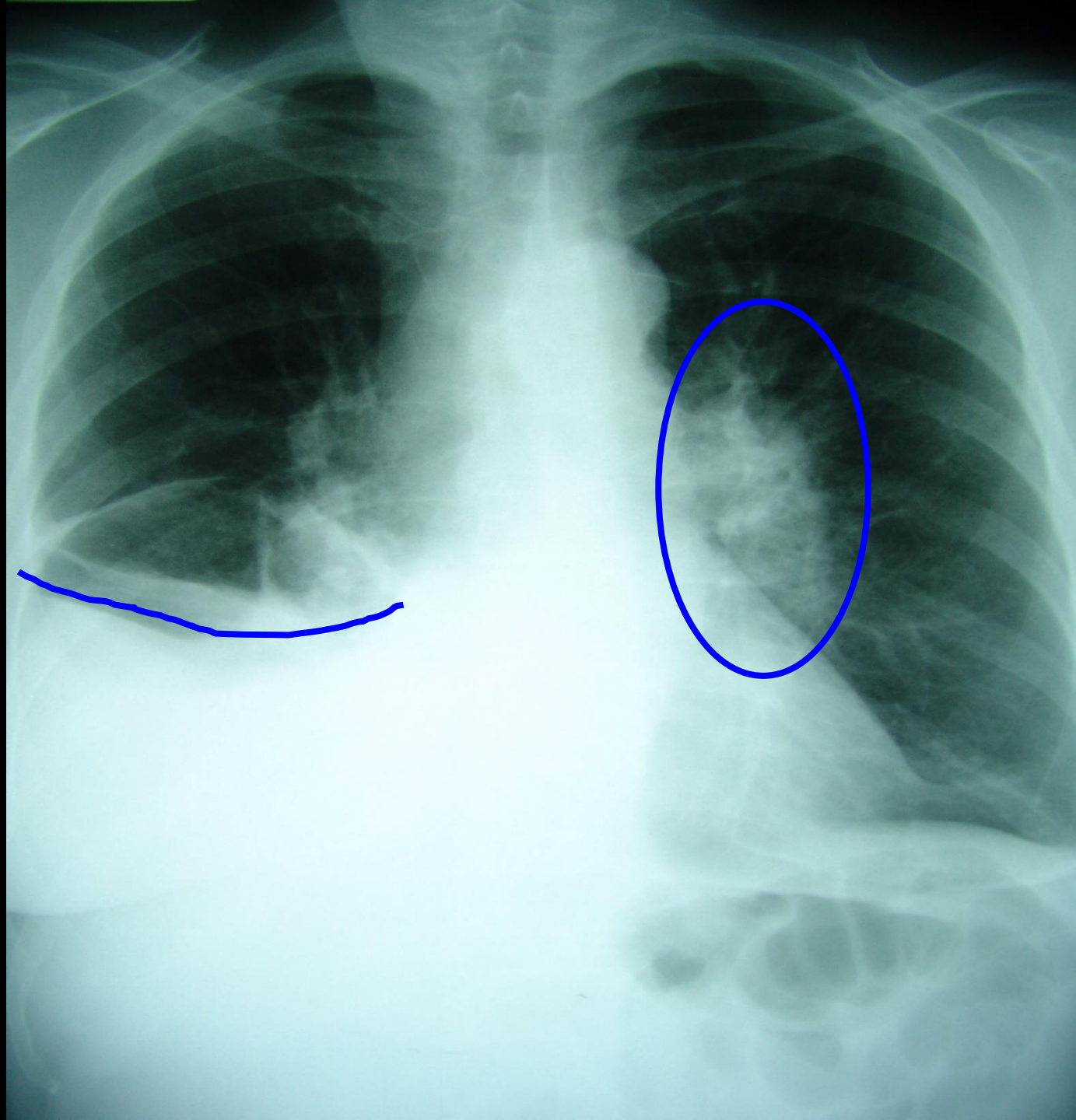
D: 350
It: 0
Av: 150
In: 120

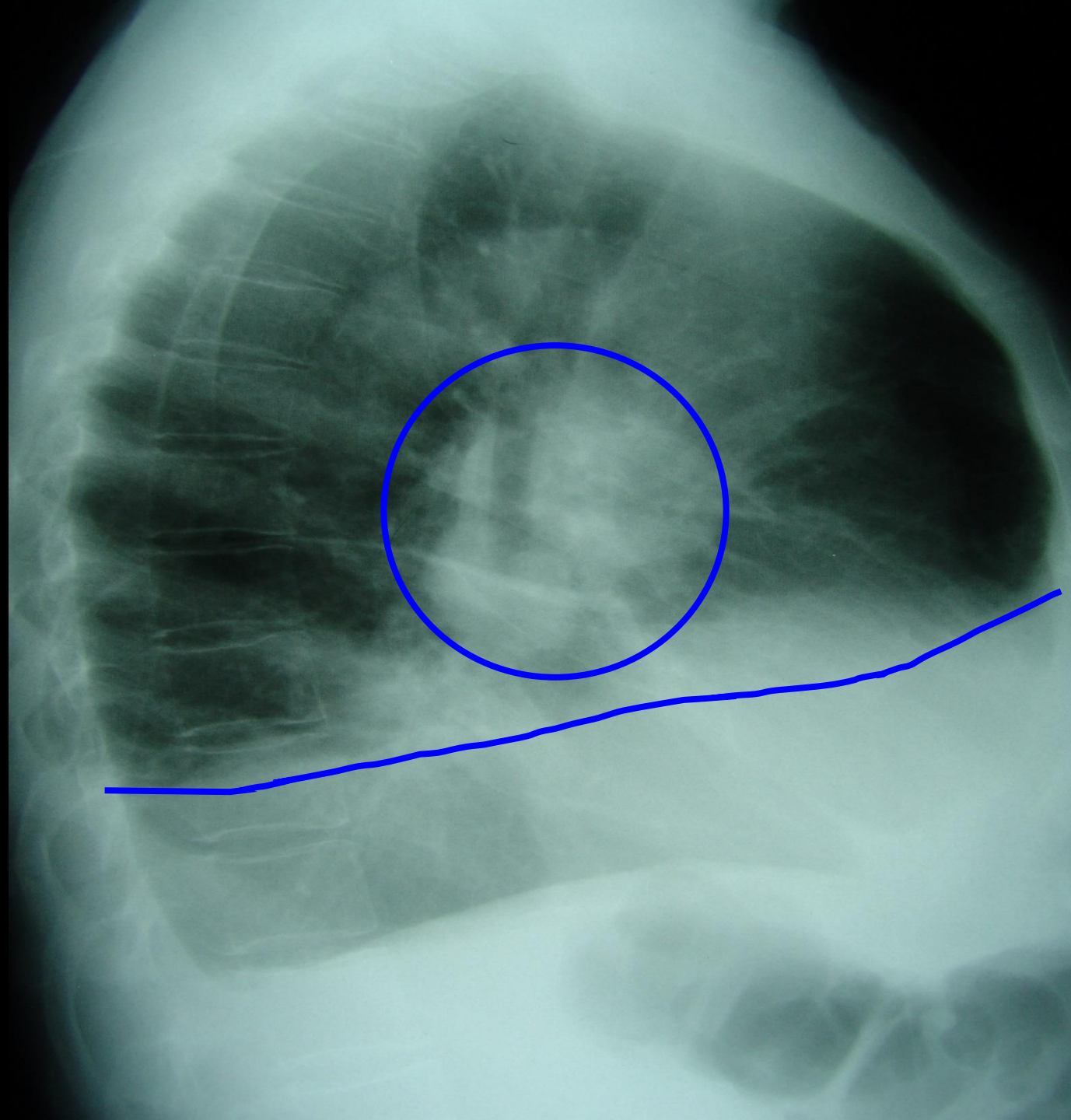
Z:
C: -41
W: 200

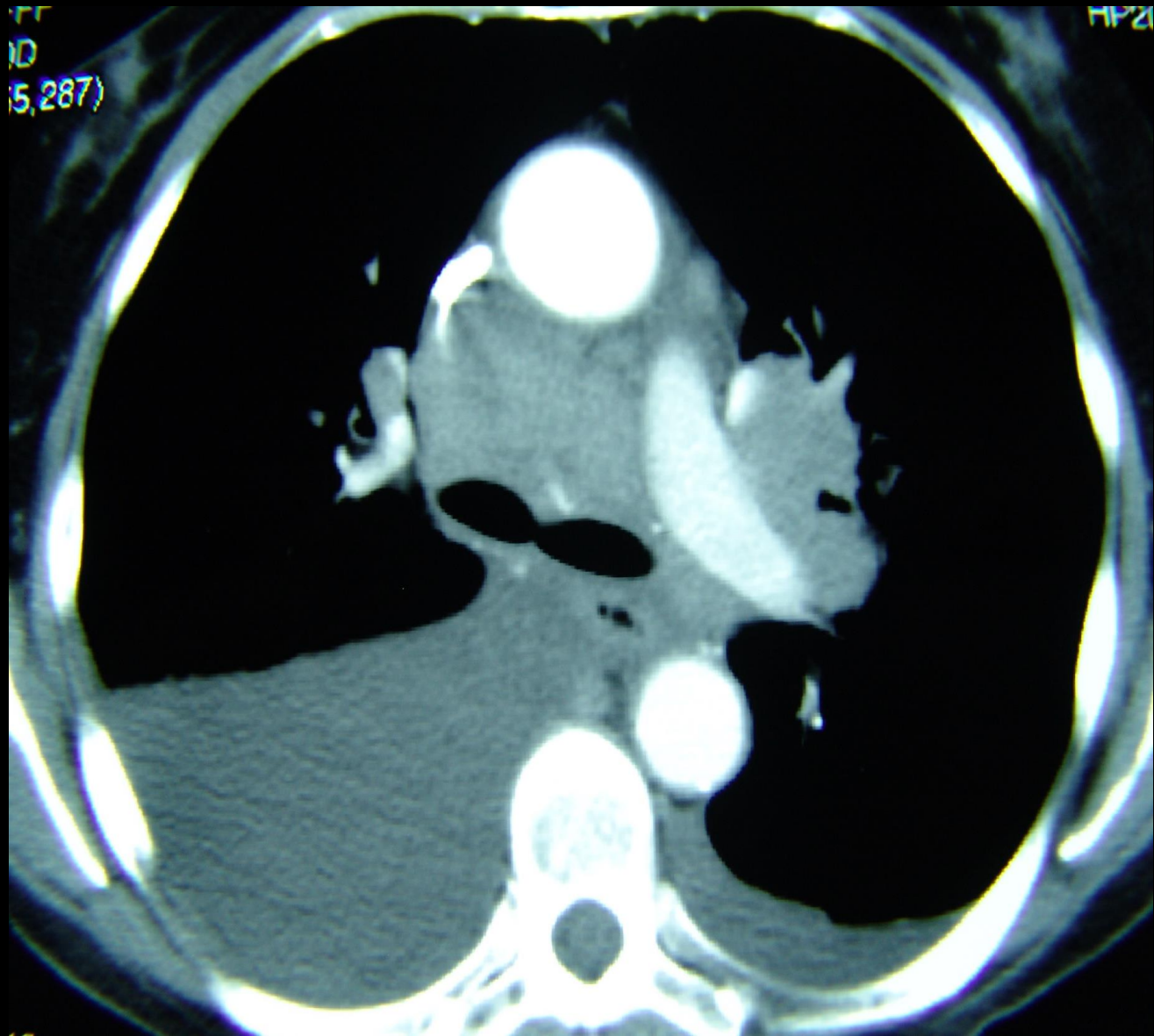
Pleural Effusions

- Primary TB (25%)
- Hypersensitivity reaction to TB proteins
- Organisms uncommonly isolated from fluid
- May not be associated with obvious parenchymal disease on CXR



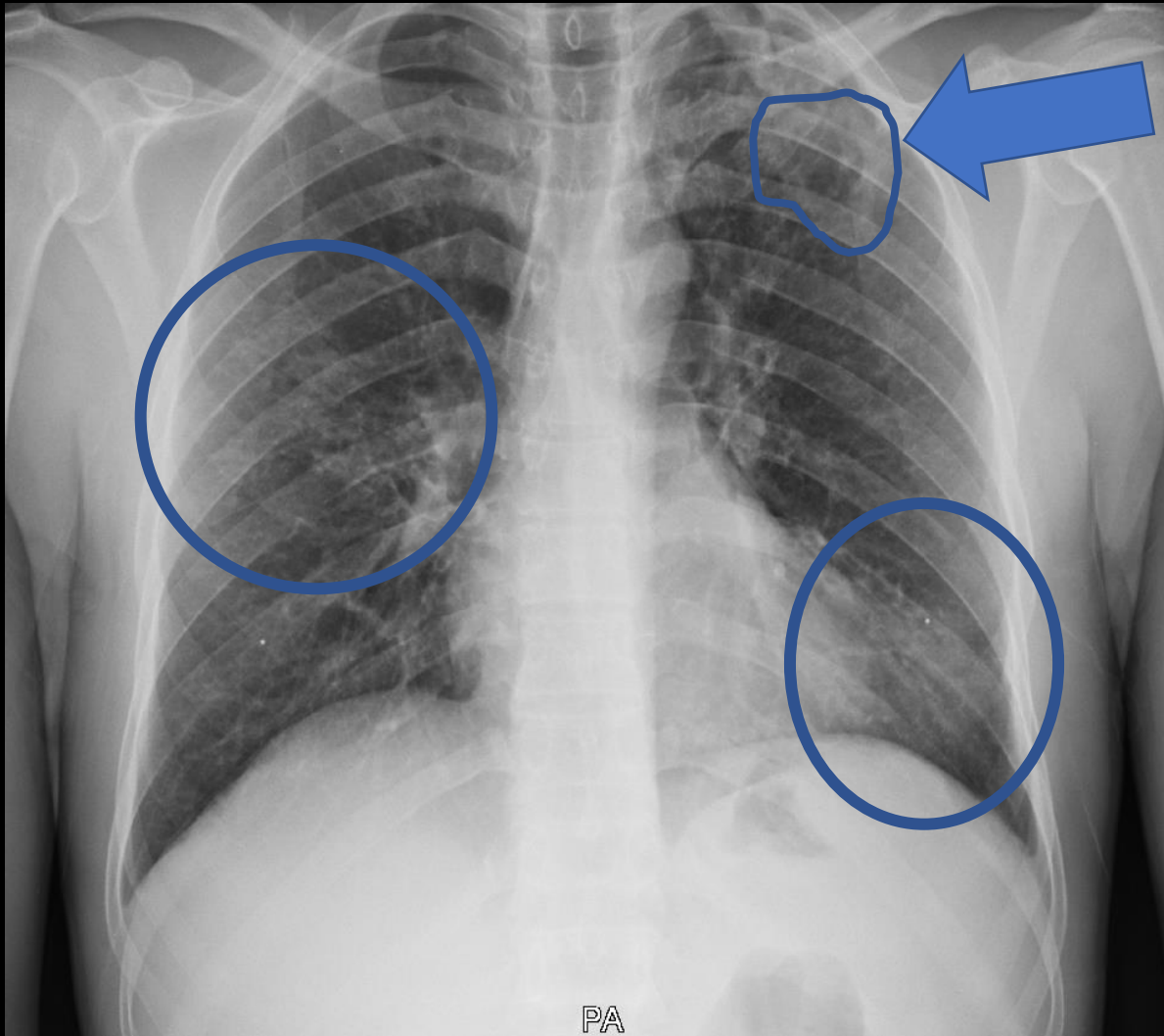






Back to our Eritrean family...




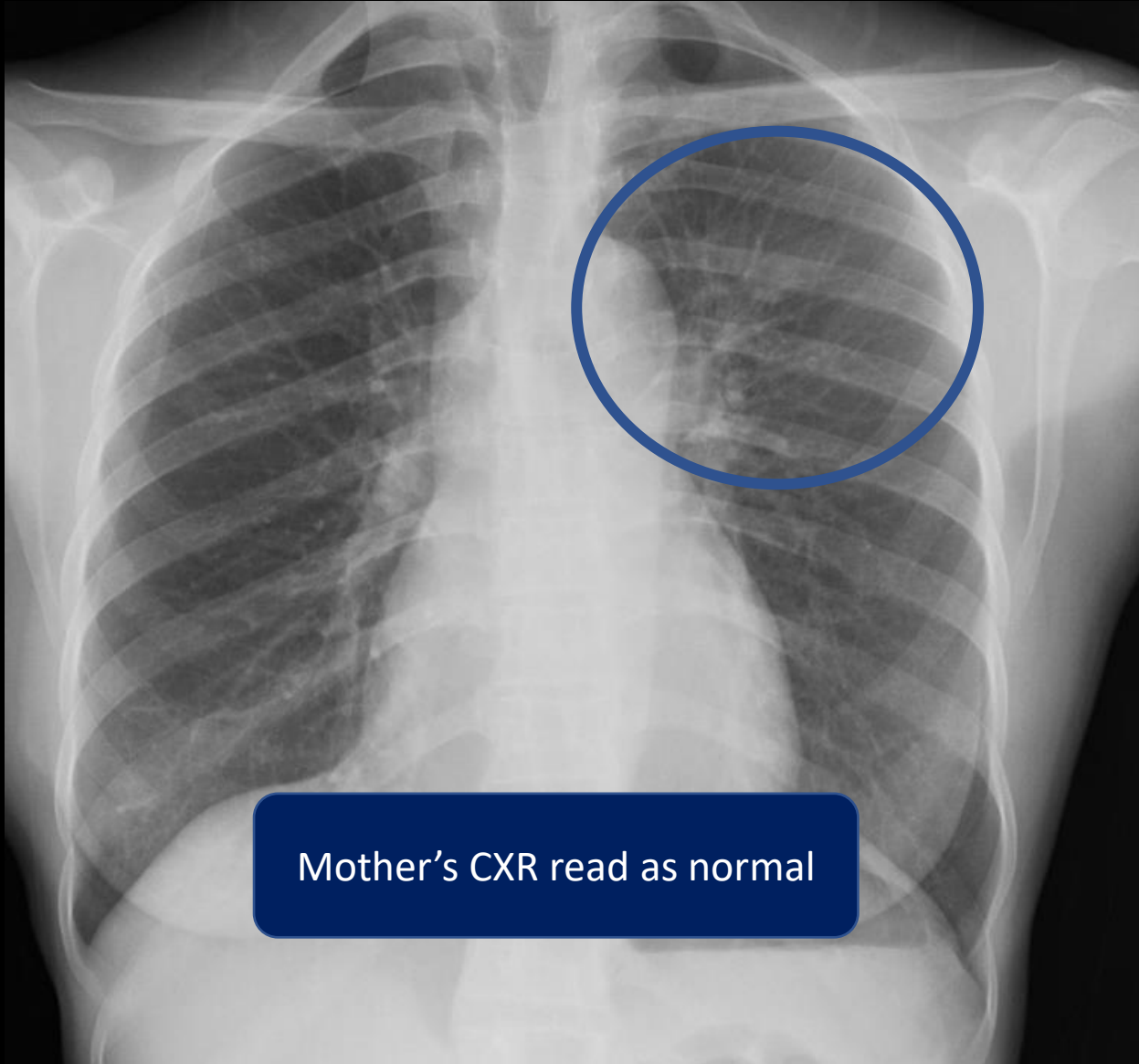


May 2019

37 year old African man
4 months of cough, weight
loss, and poor energy

Chest xray is one piece of the TB puzzle





Mother's CXR read as normal

Sputum AFB smear and PCR +,
culture + MTB

Chest Radiology in TB

- Interpretation of a chest radiograph is pattern recognition that requires clinical correlation for true diagnosis



Thank you

Heartland National TB Center

