



Tuberculosis in Children

Andrea T. Cruz, MD, MPH

May 7, 2025

TB Nurse Case Management • May 6 – 8, 2025 • San Antonio, Texas



Andrea T. Cruz, MD, MPH

Has the following disclosures to make:

- No conflict of interests
- No relevant financial relationships with any commercial companies pertaining to this activity





Tuberculosis in Children

Andrea T. Cruz, MD, MPH

Professor of Pediatrics

Divisions of Infectious Diseases and
Emergency Medicine

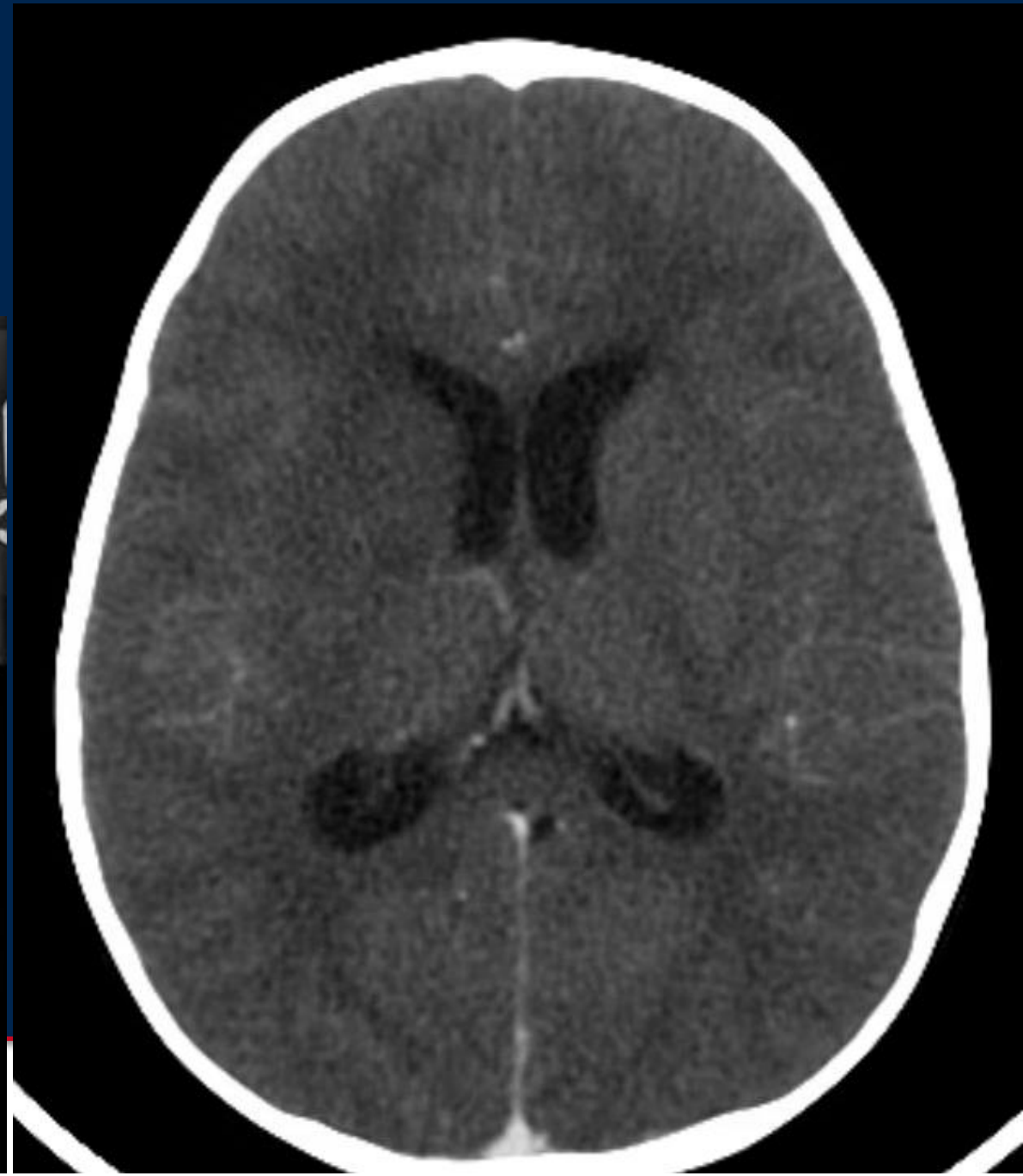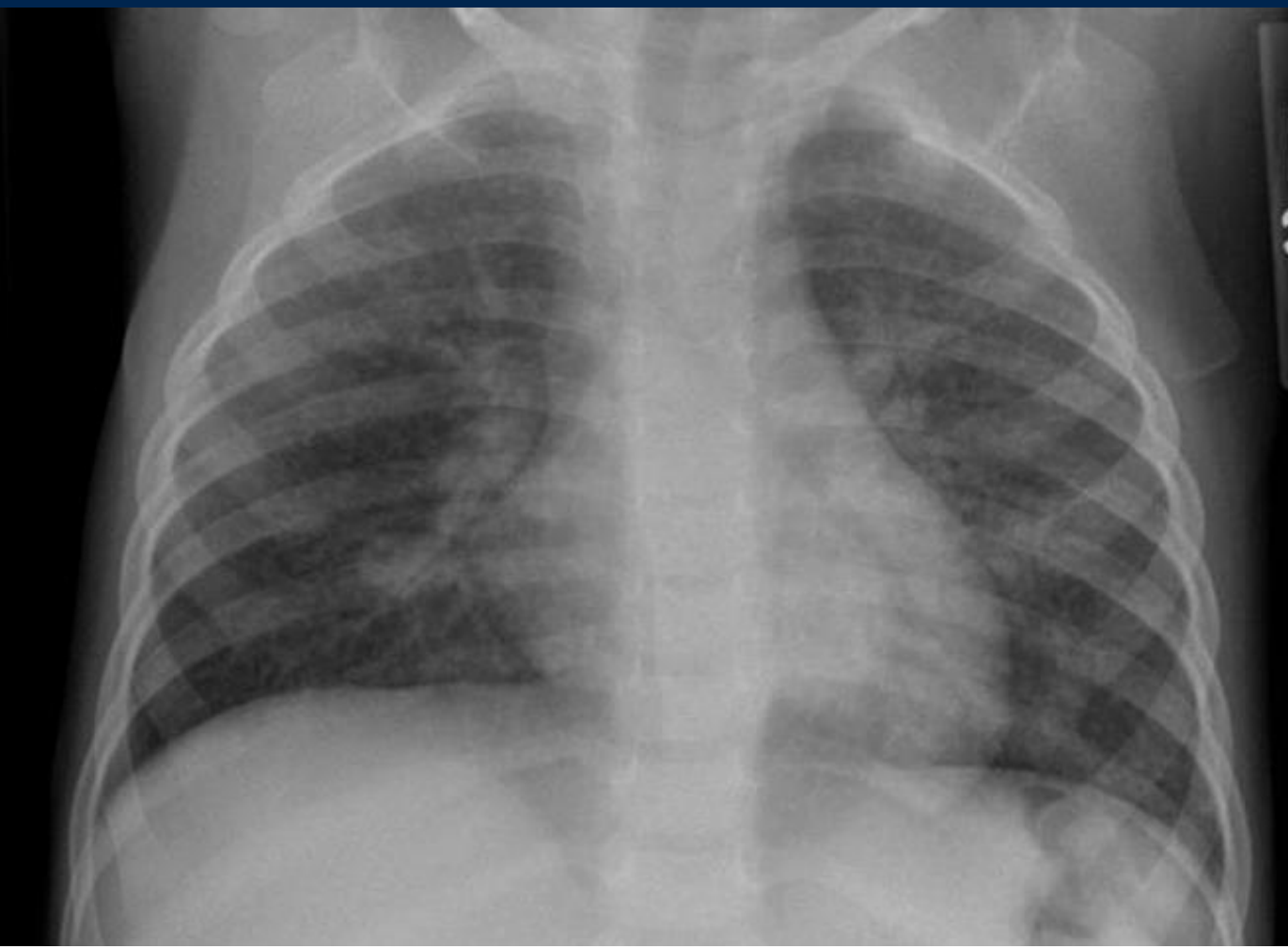Pediatrics

Disclosures

- Levofloxacin is off-label for tuberculosis in children
- Pictures shared with permission of families, who wished to increase TB awareness among clinicians and policymakers

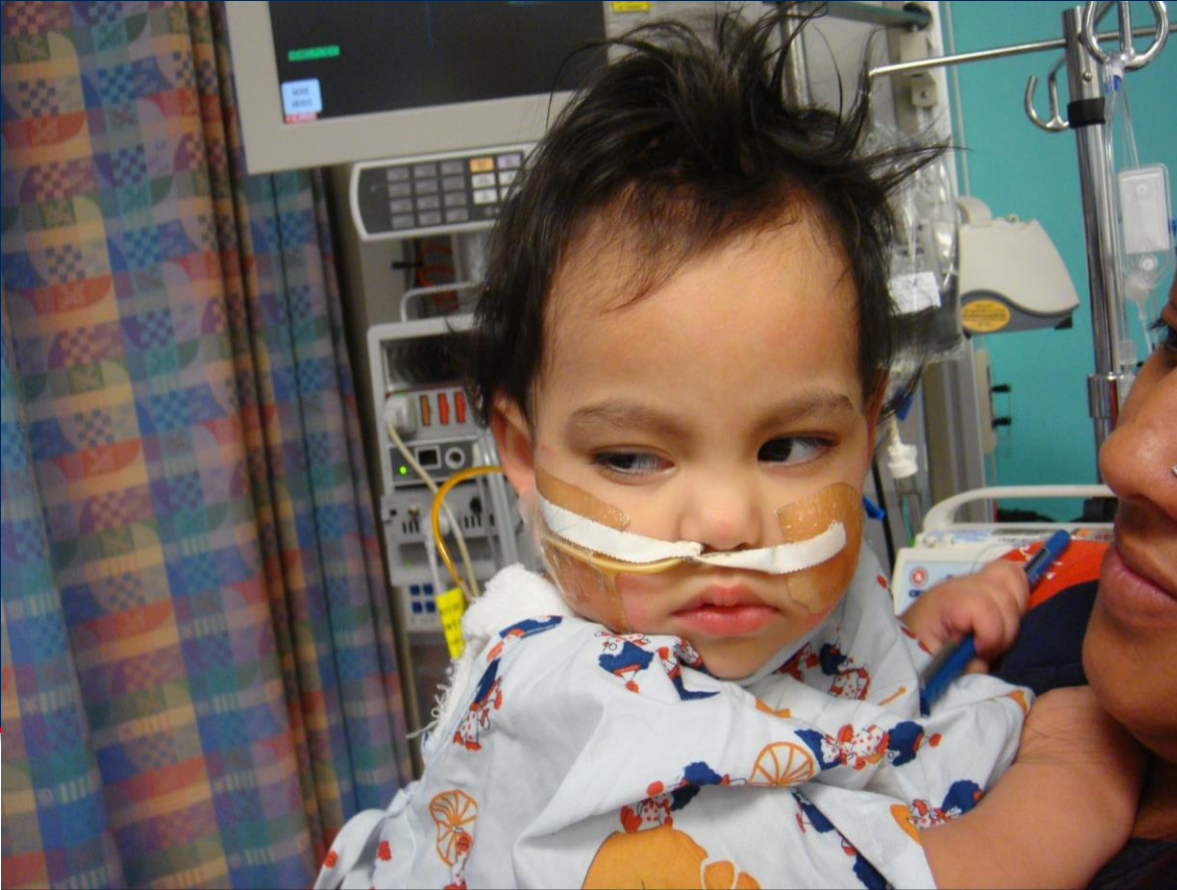Case

- 14-month-old girl, no medical history, presented to ED with seizures, no return to baseline
- Progressively more altered → intubated
- Fever x 2 weeks, vomiting → prior diagnoses of gastroenteritis
- CT brain (uncontrasted): prominent ventricles, hypoattenuation of R basal ganglia
- CSF: 450 WBC, 2 RBC, protein 800, glucose < 20, Gram stain: no organisms seen



Case

- Immediately started on steroids and TB therapy
- Discharged on INH, RIF, PZA, ethionamide + steroids



Breakdowns

Exposed

Failure to screen the mother or diagnose her in a timely fashion

Infected

Failure to identify LTBI in siblings, which would have prompted testing the baby

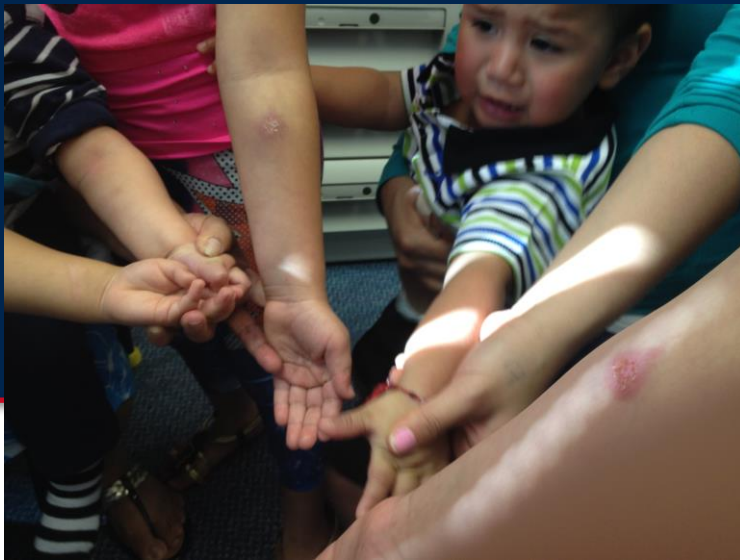Diseased

Sick

Failure to identify early stages of CNS TB

Diagnosed

Treated



Objectives

- To identify when to think about TB
- To recognize potential complications of TB and what forms of TB can result in rapid decompensation
- To formulate a diagnostic and therapeutic treatment plan for children with TB infection

TB Definitions

Class	Sx	Exam	TST/ IGRA	CXR	Contagious	Treatment
Infection	-	-	+	-	Never	Usually 1-2 drugs, given 3-9 months (given by family or health department)
Disease	+	-/+	+/-	+/-	Rarely	Multiple drugs (3-4), given 6-12 months (always given by health department)

TST: tuberculin skin test

IGRA: interferon gamma release assay

US TB Epidemiology: 2024

- 10,347 cases; incidence: 3/100,000
- 76% in the foreign-born
 - Top 5 countries of birth: Mexico (19% of non-US-born persons), Philippines (12%), India (10%), Vietnam (8%), China (6%)
- Largest increases:
 - **Children ≤ 4 y: up by 16%**
 - 15-24y: up by 11%
- 4 states (CA, FL, TX, NY): 50% of US cases

Clinical Manifestations



**Texas Children's
Hospital[®]**

BCM
Baylor College of Medicine

Pediatrics

Risk of Progression from TB Infection to Disease by Age

Age at infection (y)	No disease (%)	Pulmonary TB (%)	CNS/Disseminated TB (%)
<1	50	30-40	10-20
1-2	75-80	10-20	2.5
2-5	95	5	0.5
5-10	98	2	<0.5
>10	80-90	10-20	<0.5

Childhood TB Disease Sites

Site*	% of cases	Median Age (years)
Pulmonary	77.5	6
Lymphatic	13.3	5
Pleural	3.1	16
Meningeal	1.9	2
Bone/joint	1.2	8
Miliary	0.9	1
GU	0.8	16
Peritoneal	0.3	13

*: United States (almost all are immunocompetent)

Signs & Symptoms of Pulmonary TB

Feature		Infant	Child	Adolescent
Symptom	Fever	+++	+	+++
	Cough	+++	+++	+++
	Night sweats	-	-	+
	Hemoptysis	-	-	+
Sign	Rales	+++	-	+
	Wheezing	+++	-	-
	Decreased breath sounds	+++	-	+
Site	Intrathoracic	+++	+++	+++
	Intra + extrathoracic	+++	-	-

When should I suspect TB disease?

- Epidemiology:

- Child has had contact to a person with suspected/confirmed TB

- Symptoms:

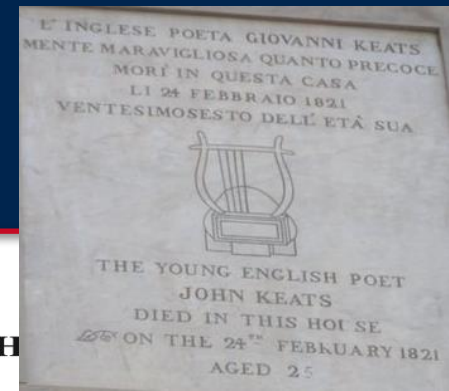- Prolonged symptom duration [> 2 weeks], failed therapy for PNA or adenitis
- Pneumonia + weight loss
- Recurrent or persistent pneumonia
- Referable to a form of extrapulmonary disease

- Lab/Radiology findings:

- Meningitis + abnormal CXR
- CSF pleocytosis with \uparrow protein, \downarrow glucose
- Altered mentation with strokes and/or new-onset hydrocephalus
- Certain radiographic patterns

What will kill a child?

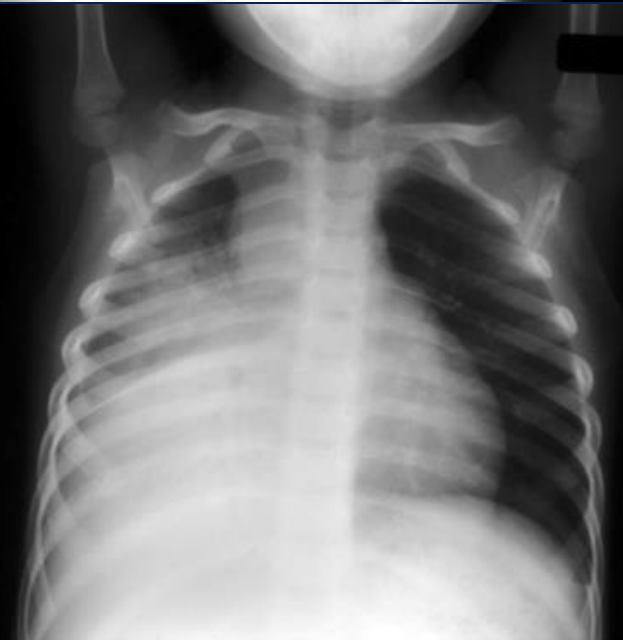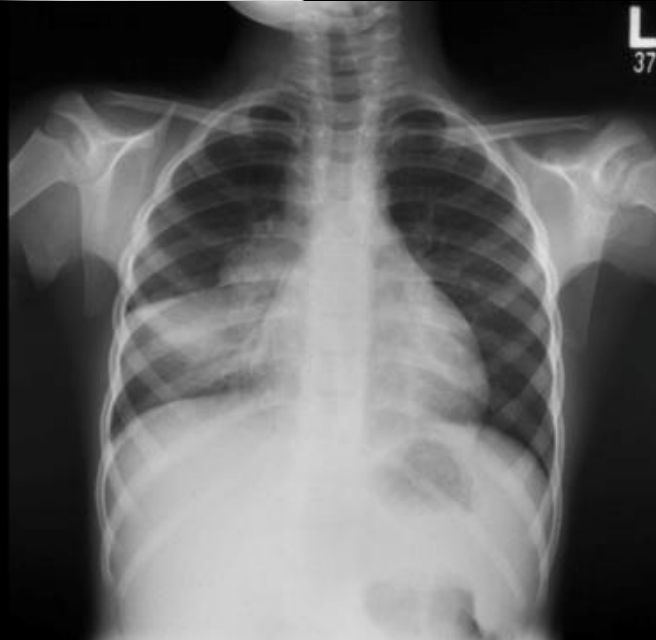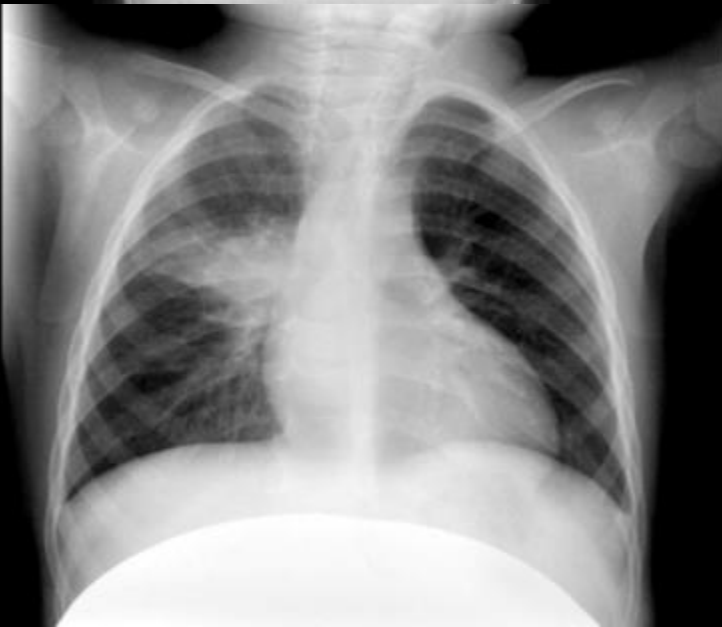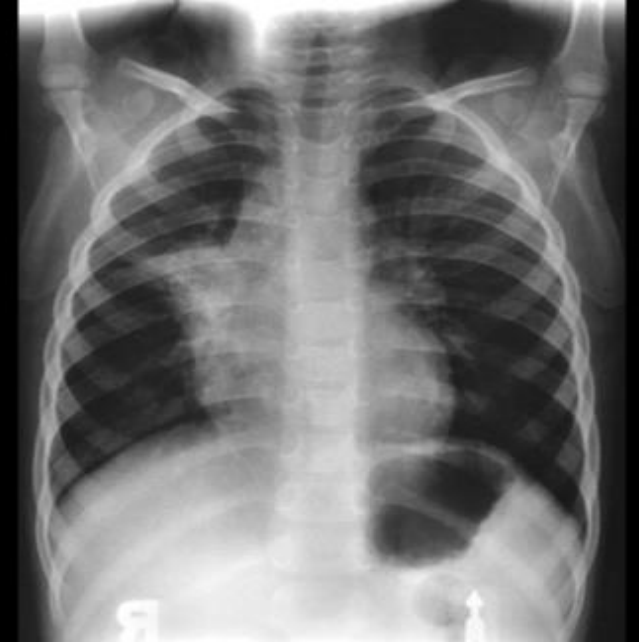
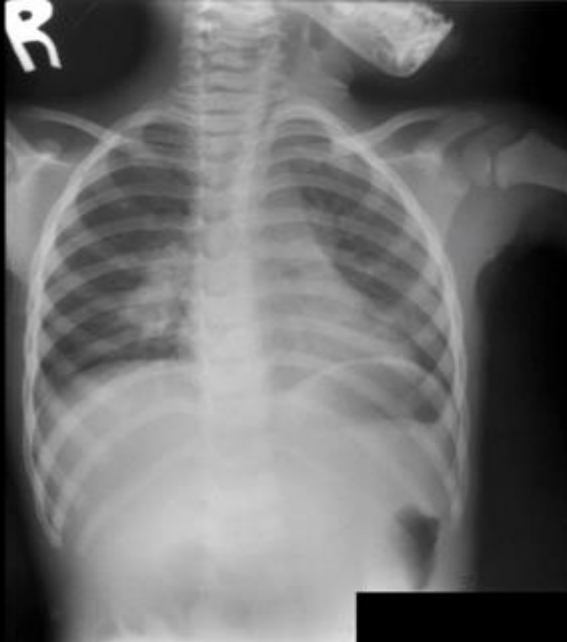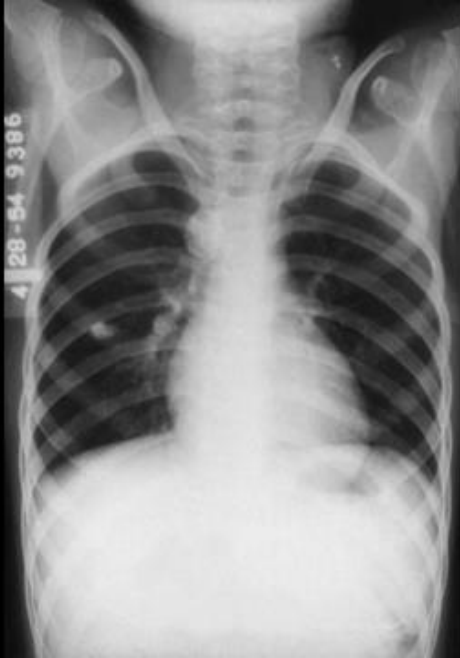- TB meningitis: increased ICP
- Miliary TB: tension pneumothorax (early), bronchiolitis obliterans (late)
- Lymphadenopathy: airway compression
- Pericarditis
- Myocarditis: predilection for the conducting system
- Hemorrhage: erosion of cavity into vessel
- Congenital TB



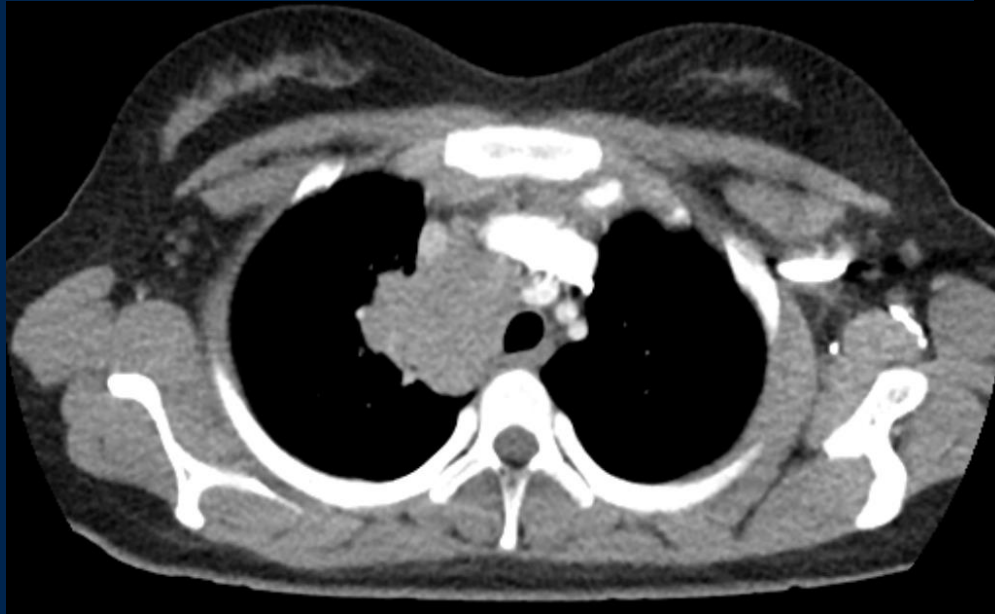
CXR Findings in Pediatric TB

- Hilar or mediastinal adenopathy
- Segmental/lobar infiltrates
- Calcifications (seen in 75-80% of children with pulmonary TB)
- Pleural effusions
- Miliary disease

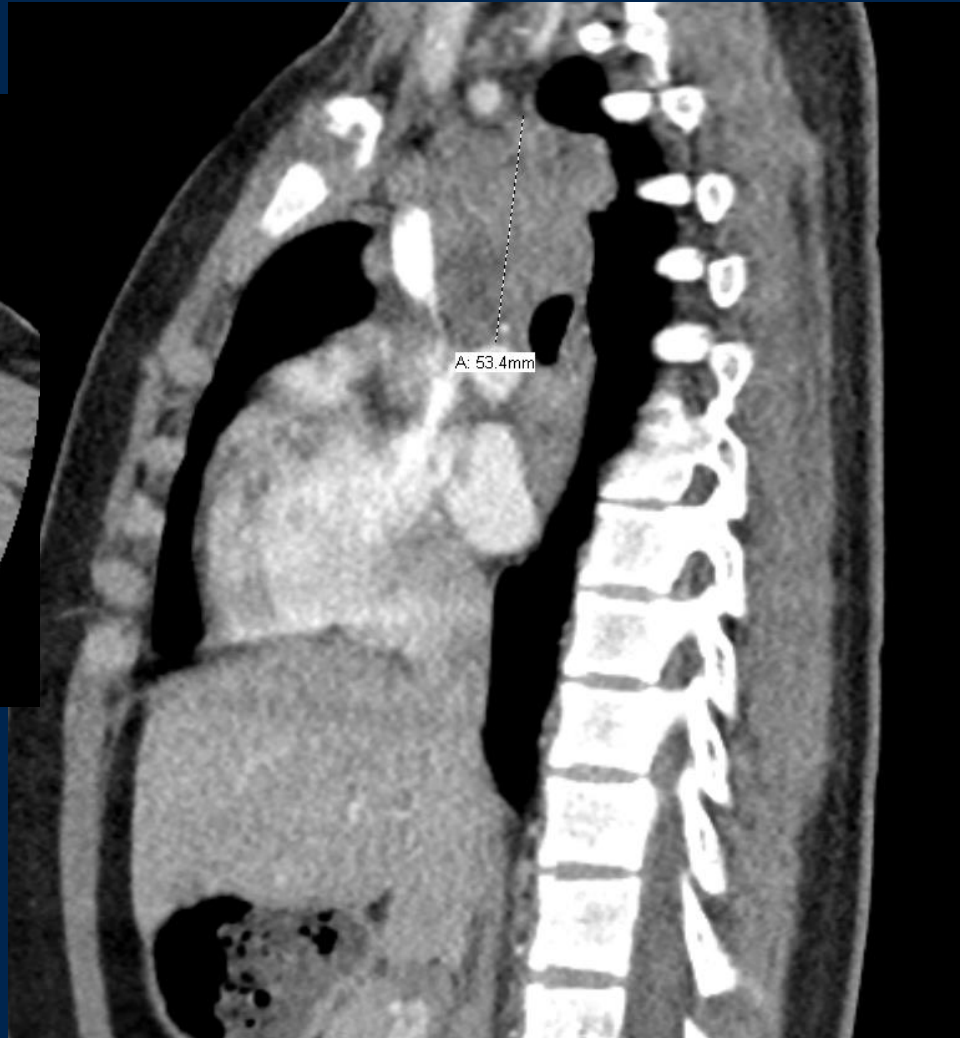
Except for CNS disease, the CXR often looks sicker than the patient



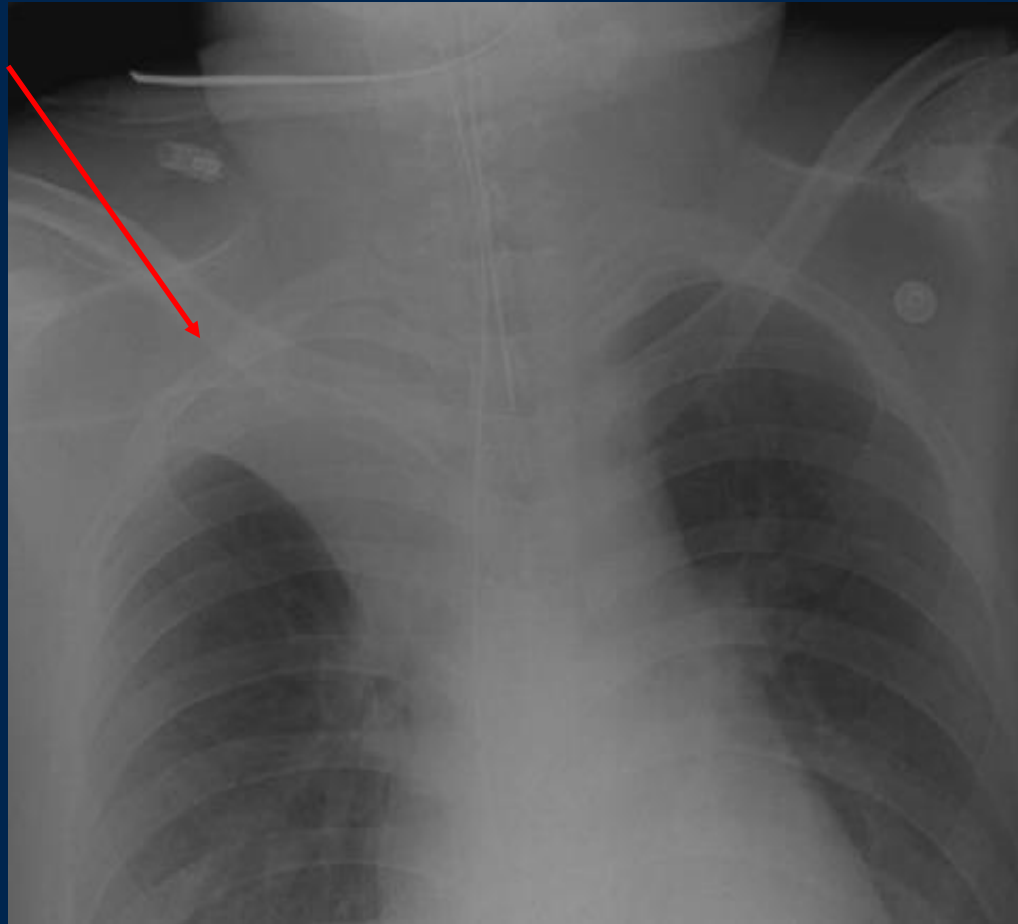
Intrathoracic Lymphadenopathy



13yo F, + IGRA, asymptomatic
Imaging: focal intrathoracic adenopathy
Biopsy: necrotizing granulomas

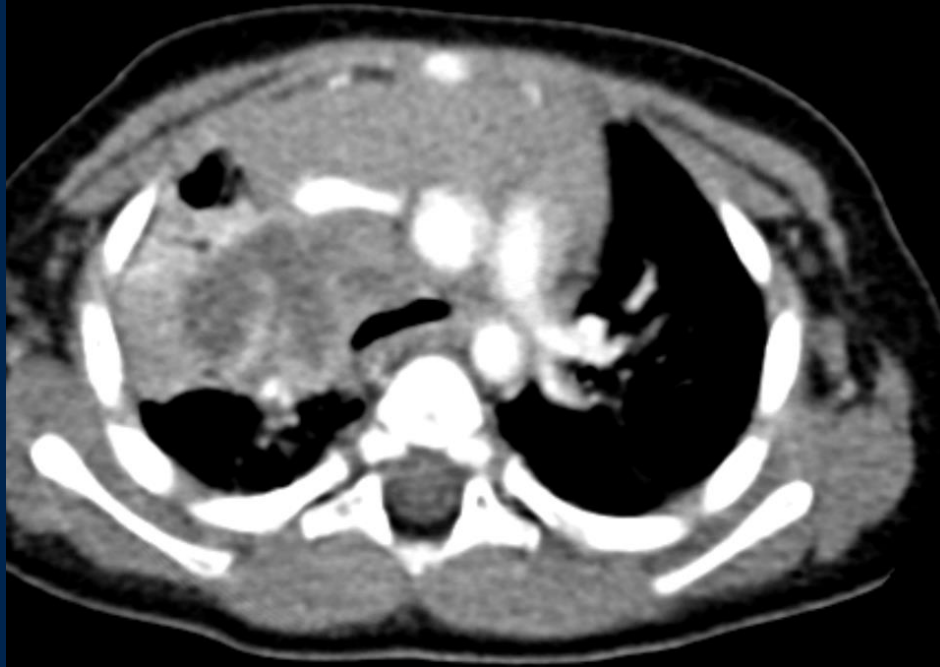
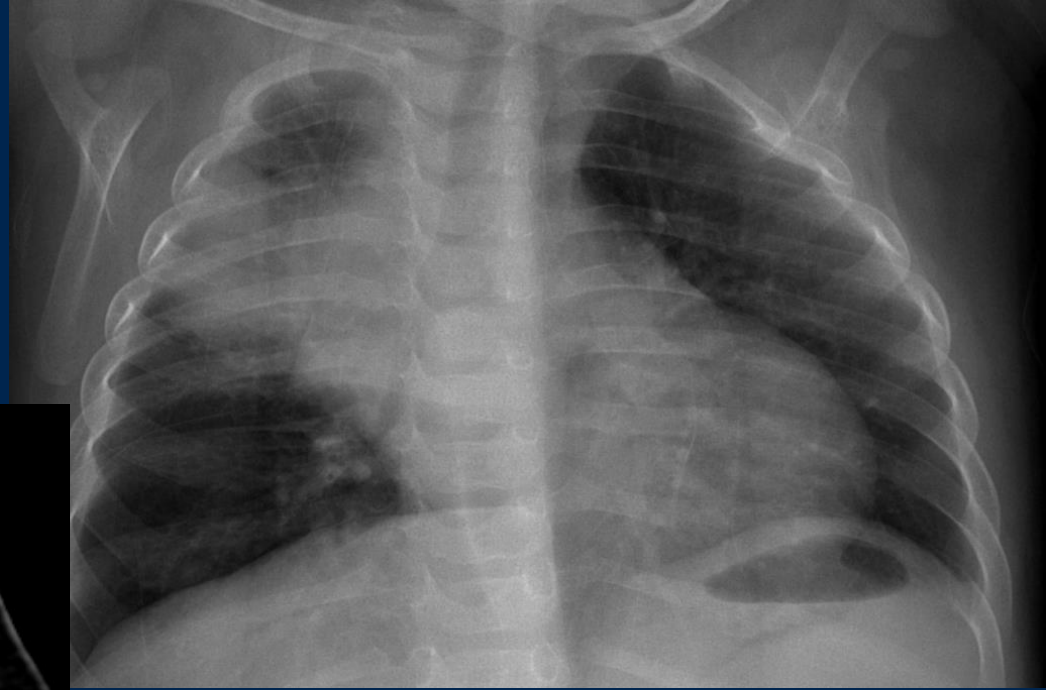
Collapse/Consolidation Pattern



Lymph node collapses a bronchus, leading to distal atelectasis

Lobar Infiltrates

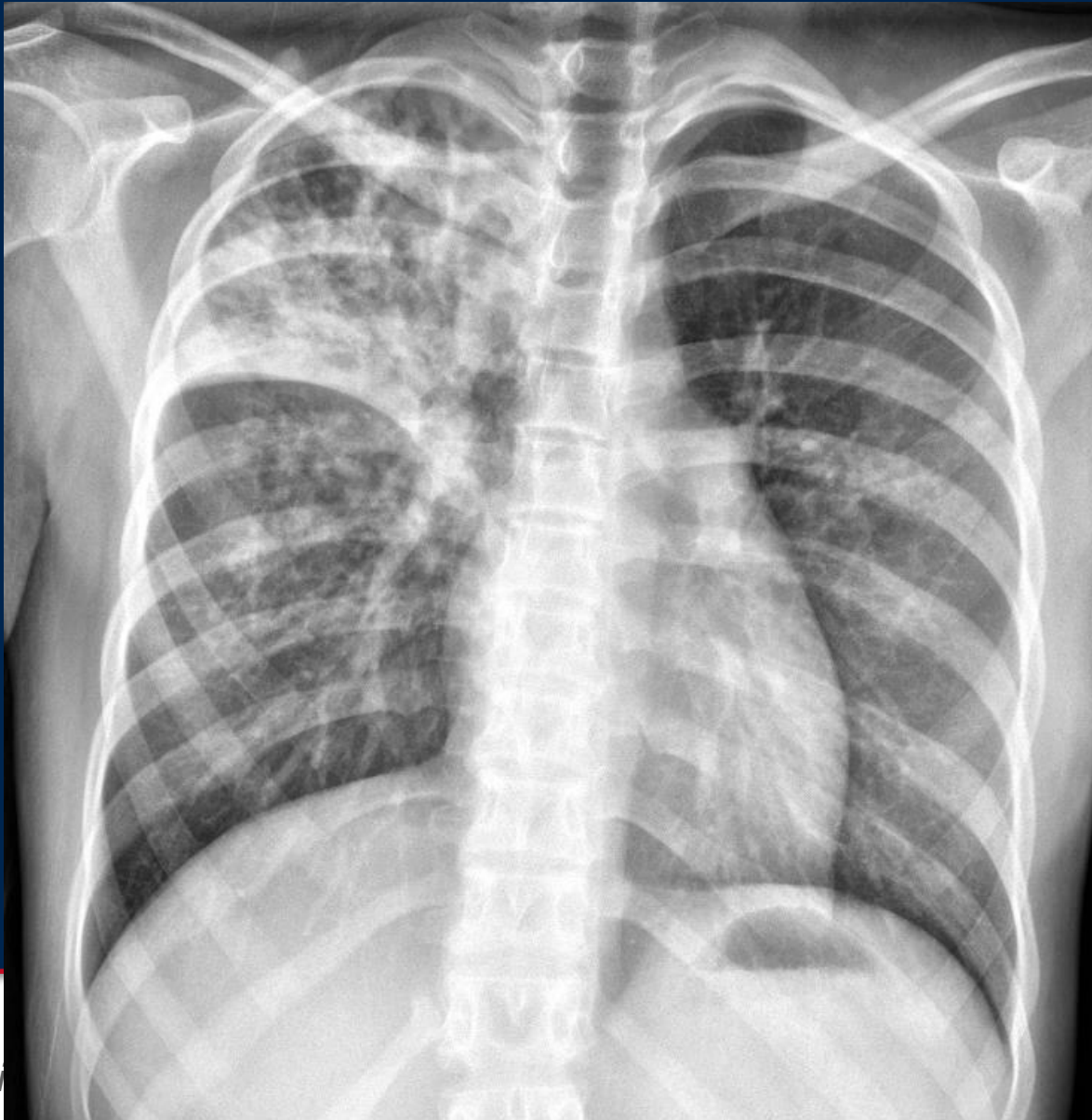


There is a large low attenuating mass extending from the mediastinum into the right hilum which causes leftward shift of the heart and mediastinal structures. This mass also encases the right upper lobe bronchus which is greatly narrowed and causes partial collapse of the right upper lobe. The etiology of the mass is unclear but certainly could reflect lymph nodes involved with granulomatous disease (such as tuberculosis) or lymphoma demonstrating partial internal necrosis. This lesion is felt to be amenable to bronchoscopic biopsy

9mo M presents to TB clinic with 23mm PPD done after grandfather diagnosed with smear-positive pulmonary TB. Baby is asymptomatic, normal vital signs, growing well. Admitted for LP (normal), gastric aspirates (smear-negative), started on multidrug therapy for TB disease

CXR looks sicker than the kid!

Cavitary Lesions

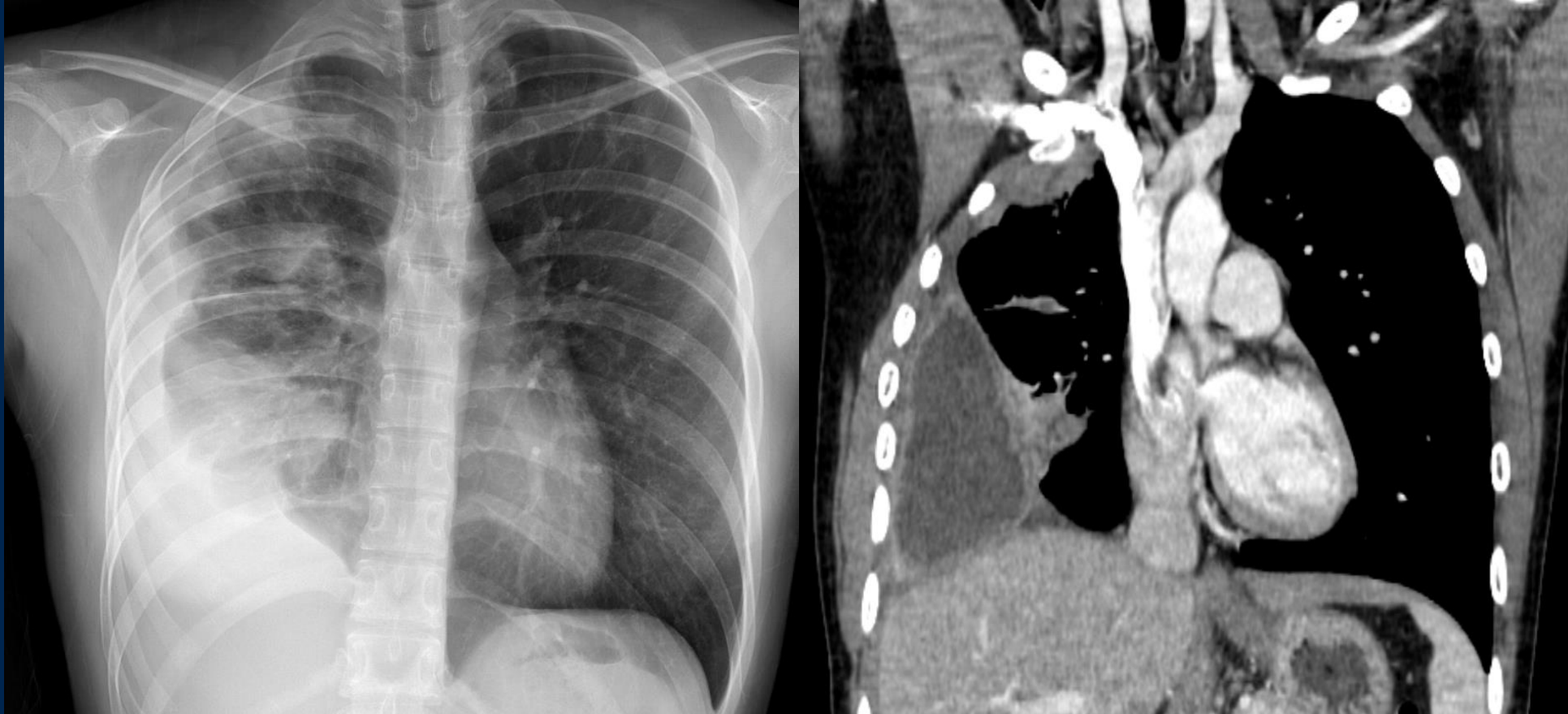

! MTB complex and Rifampin by PCR

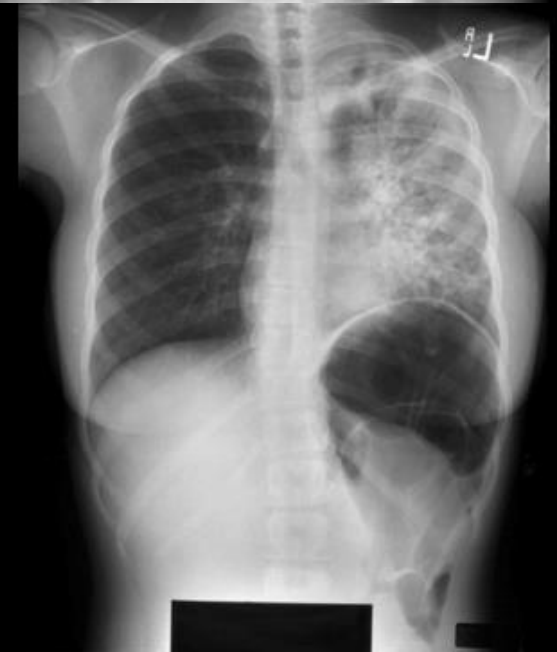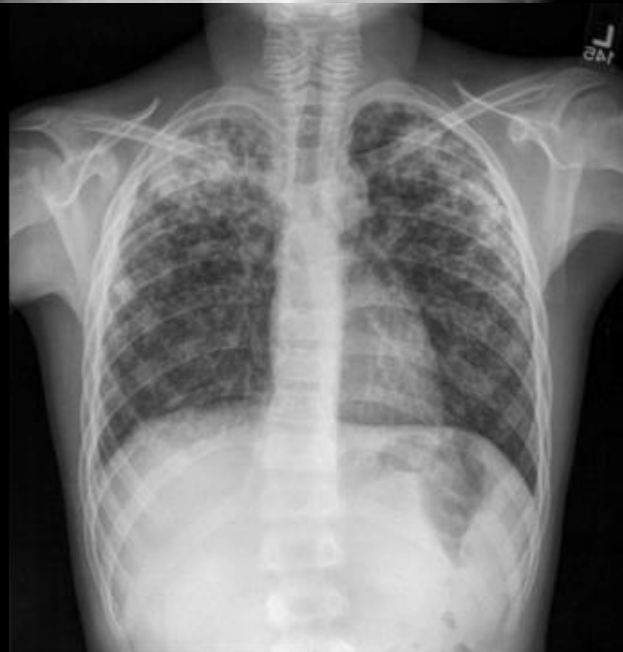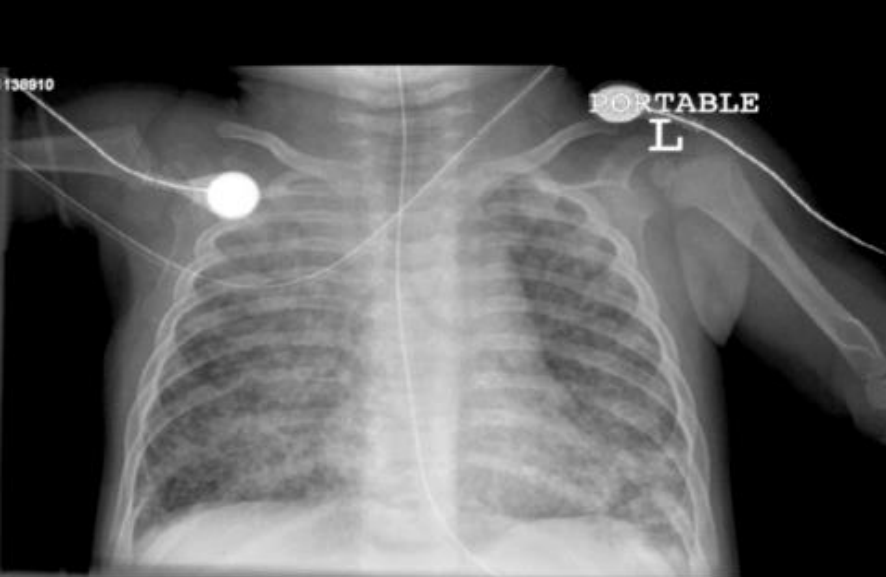
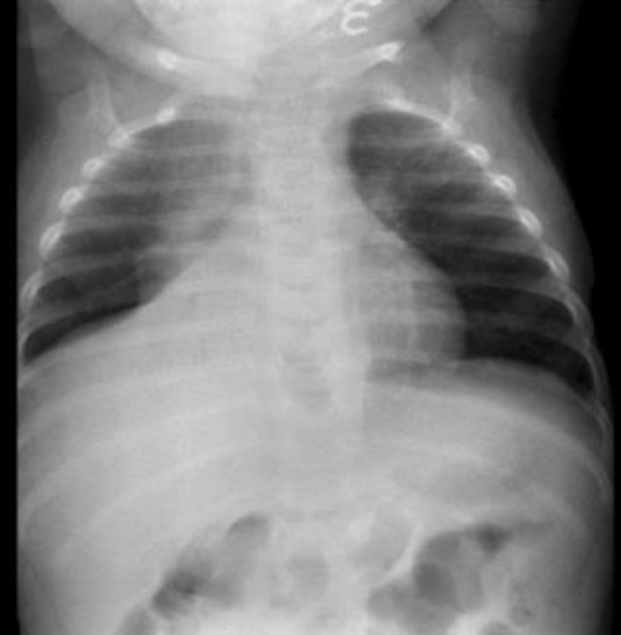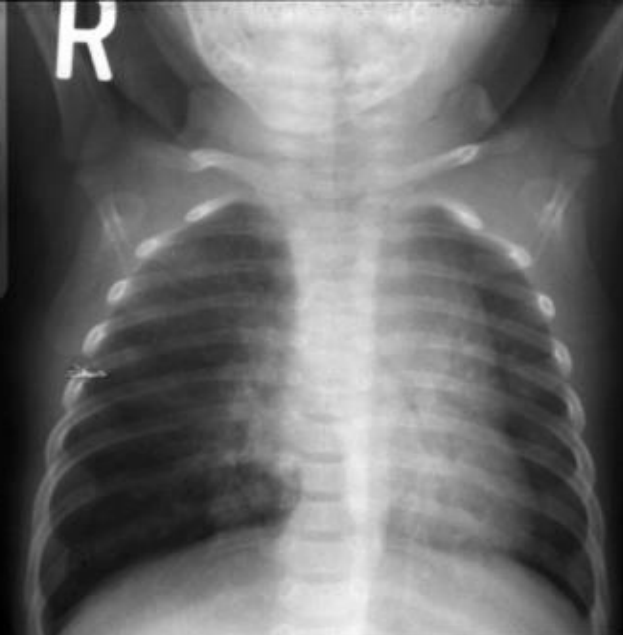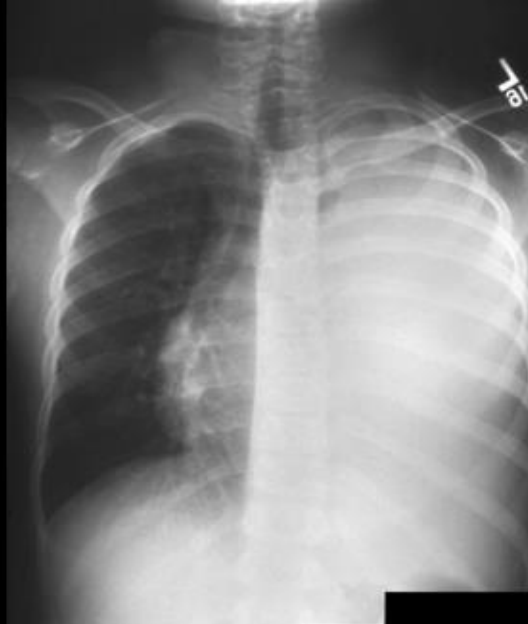Status: Final result Visible to patient: No (Not Released) Next appt: 02/21/2020

Component	12/24/19 8:18 AM
MTBRIF Source	Sputum
Mycobacterium Tuberculosis by PCR	Detected !
MTB Rifampin by PCR	Not Detected
MTB Cmplx Interpretation	Detected !

Pleural Effusions



If requires thoracentesis, try to avoid leaving in a chest tube, as this can result in creation of a fistulous connection; often requires debulking (with cultures from pleural punch biopsy) in combination with antibiotic therapy and sometime steroids

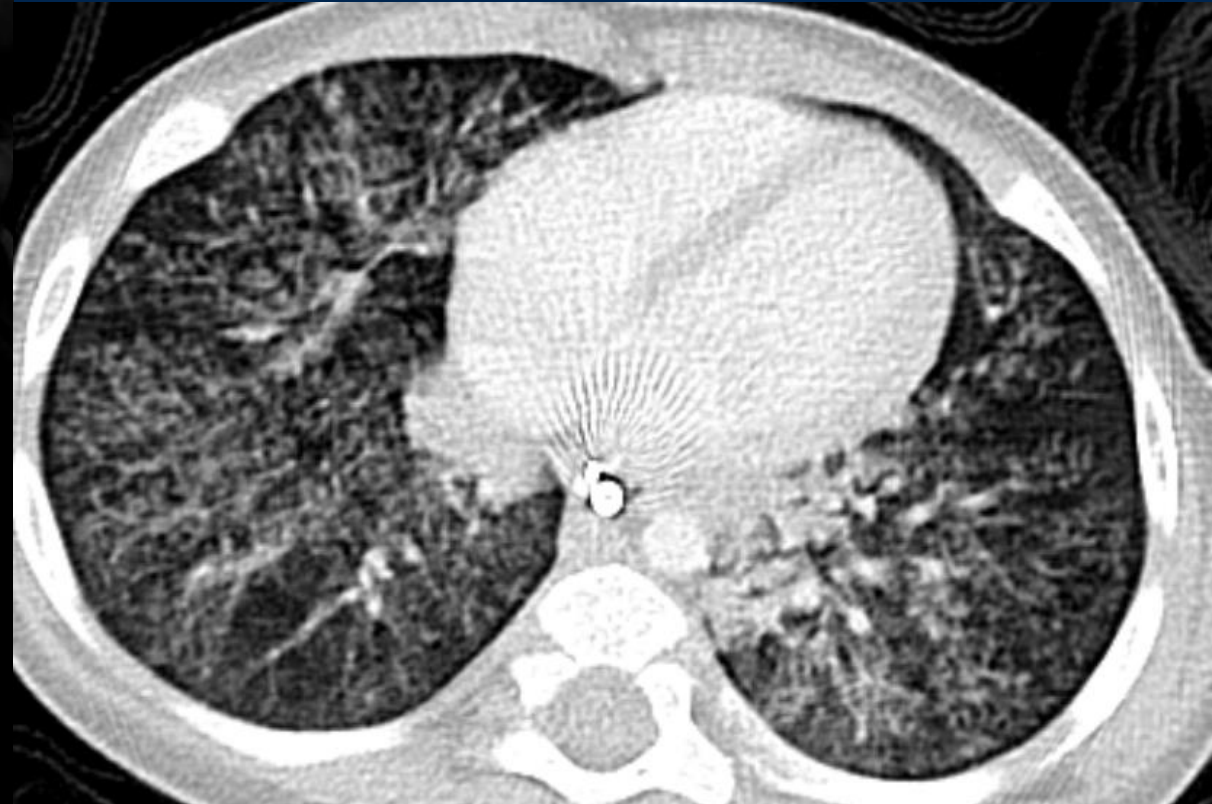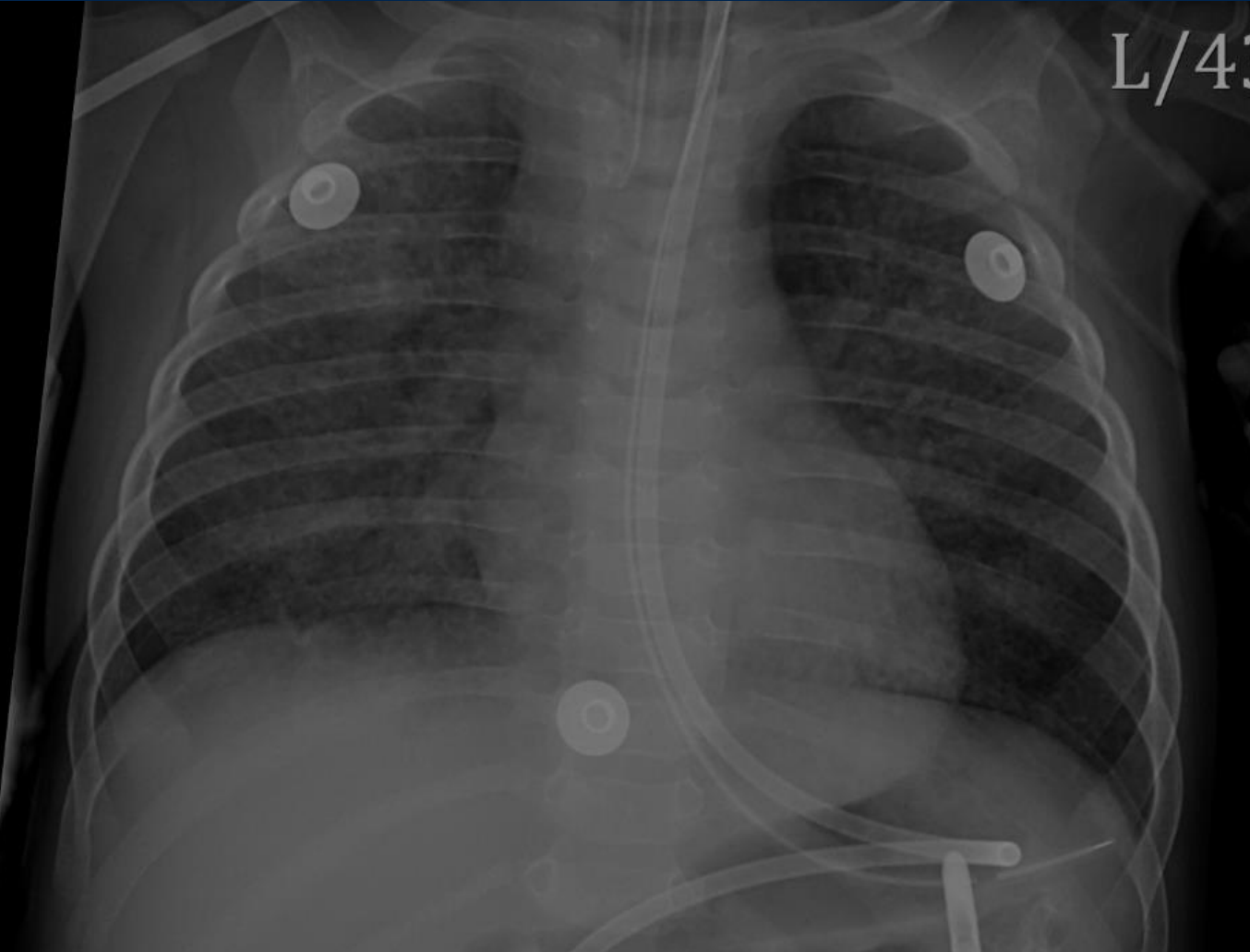


TB Meningitis: Imaging Findings

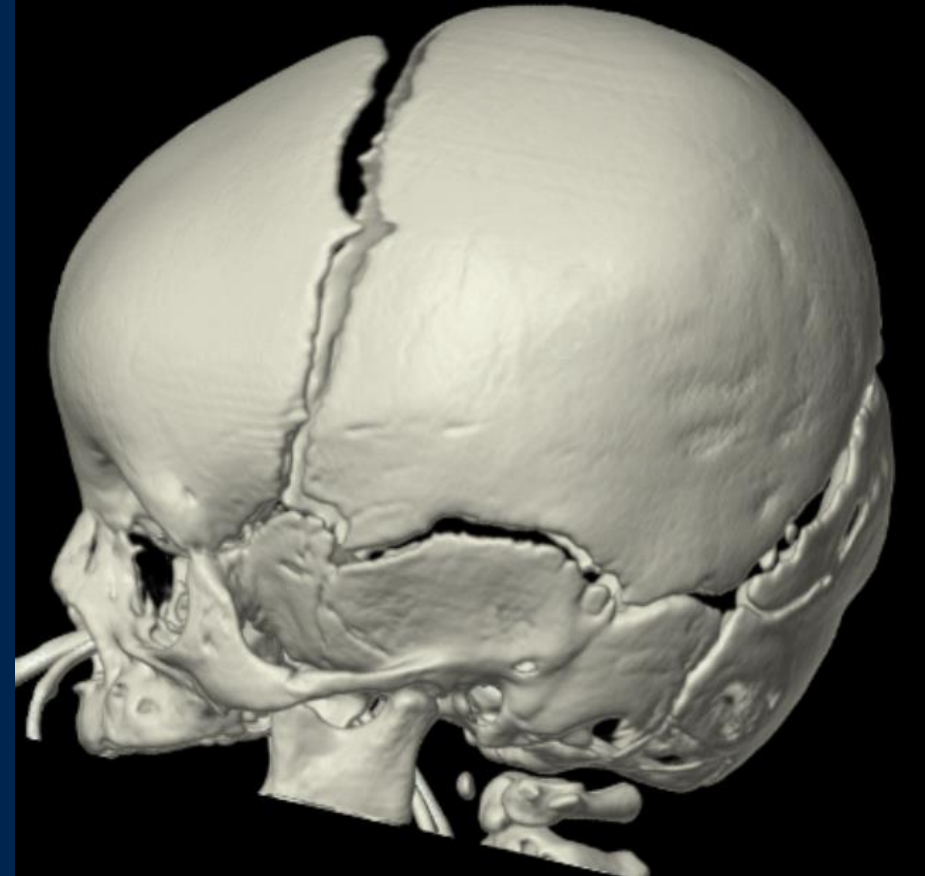
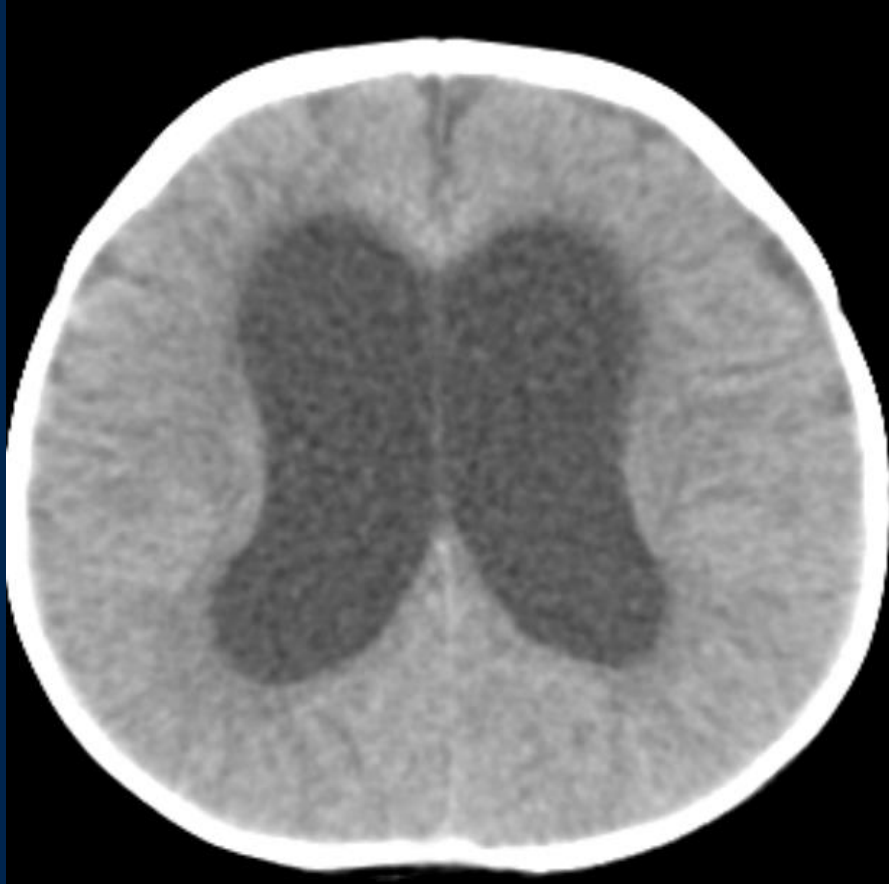
CT Feature	Sensitivity	Specificity	PPV	NPV	LR+
Basilar enhancement	89%	94%	94%	88%	14.3
Hydrocephalus	68%	72%	74%	66%	2.4
Infarcts	62%	78%	77%	64%	2.8
Granuloma	14%	94%	71%	48%	2.2
“Full House”	41%	100%	100%	59%	N/A

“Full house” – combination of basal enhancement, infarction, and hydrocephalus

>90% with TB meningitis have abnormal CXRs!

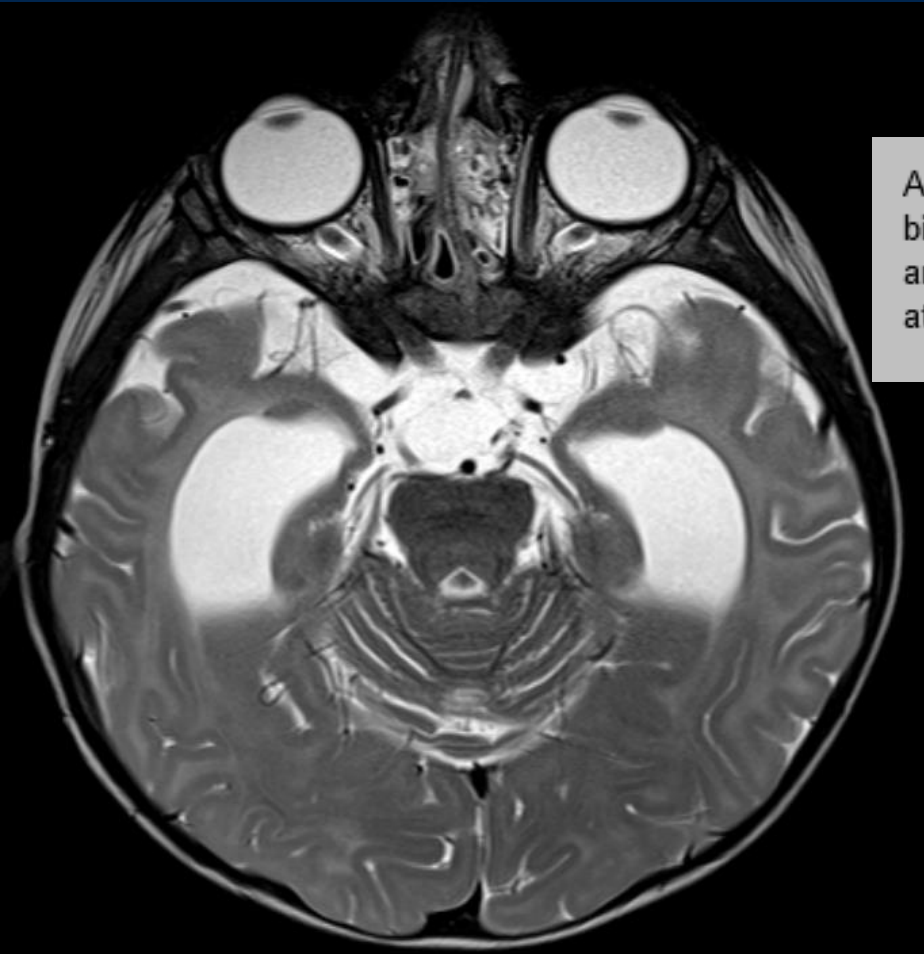


Hydrocephalus



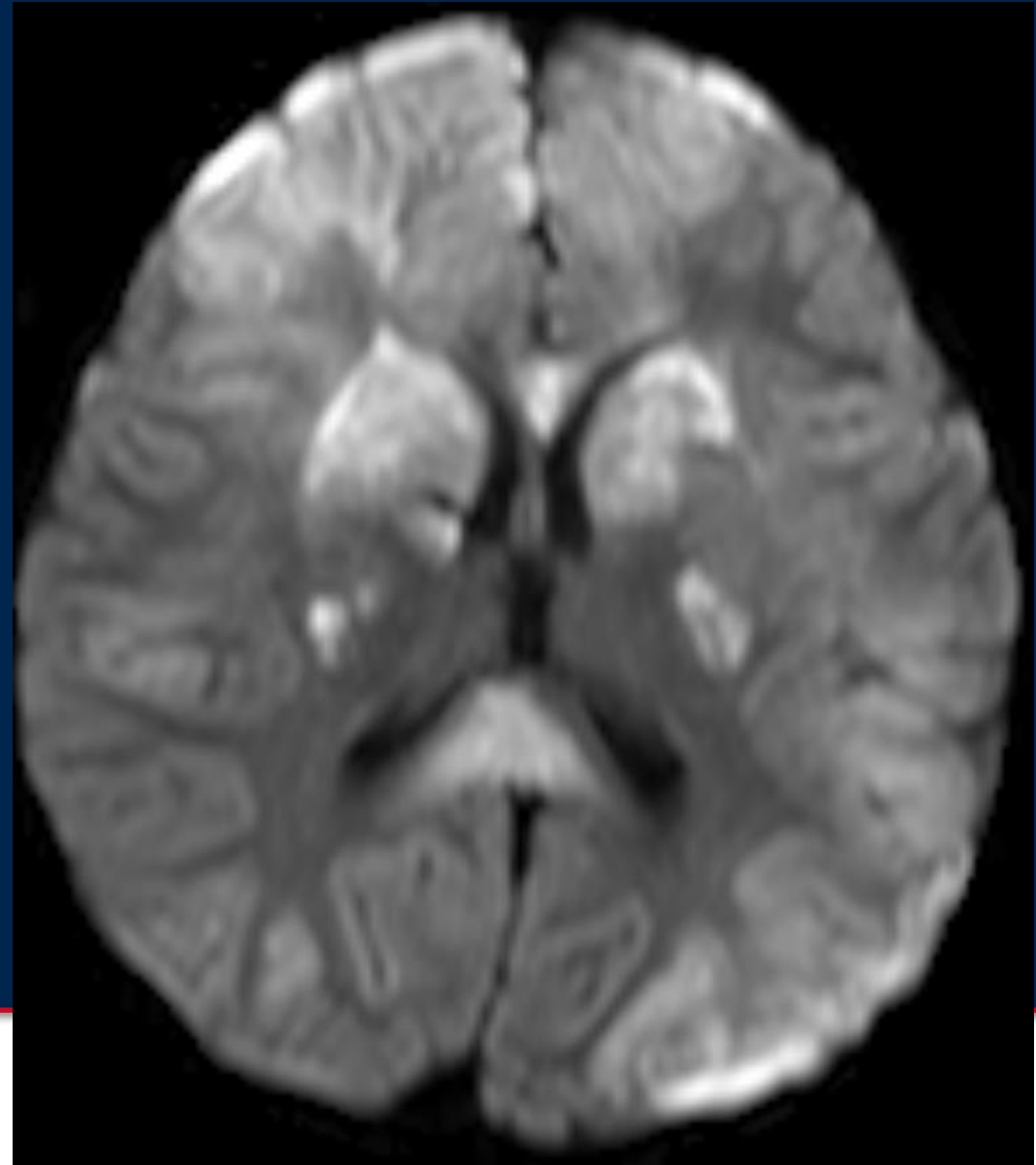
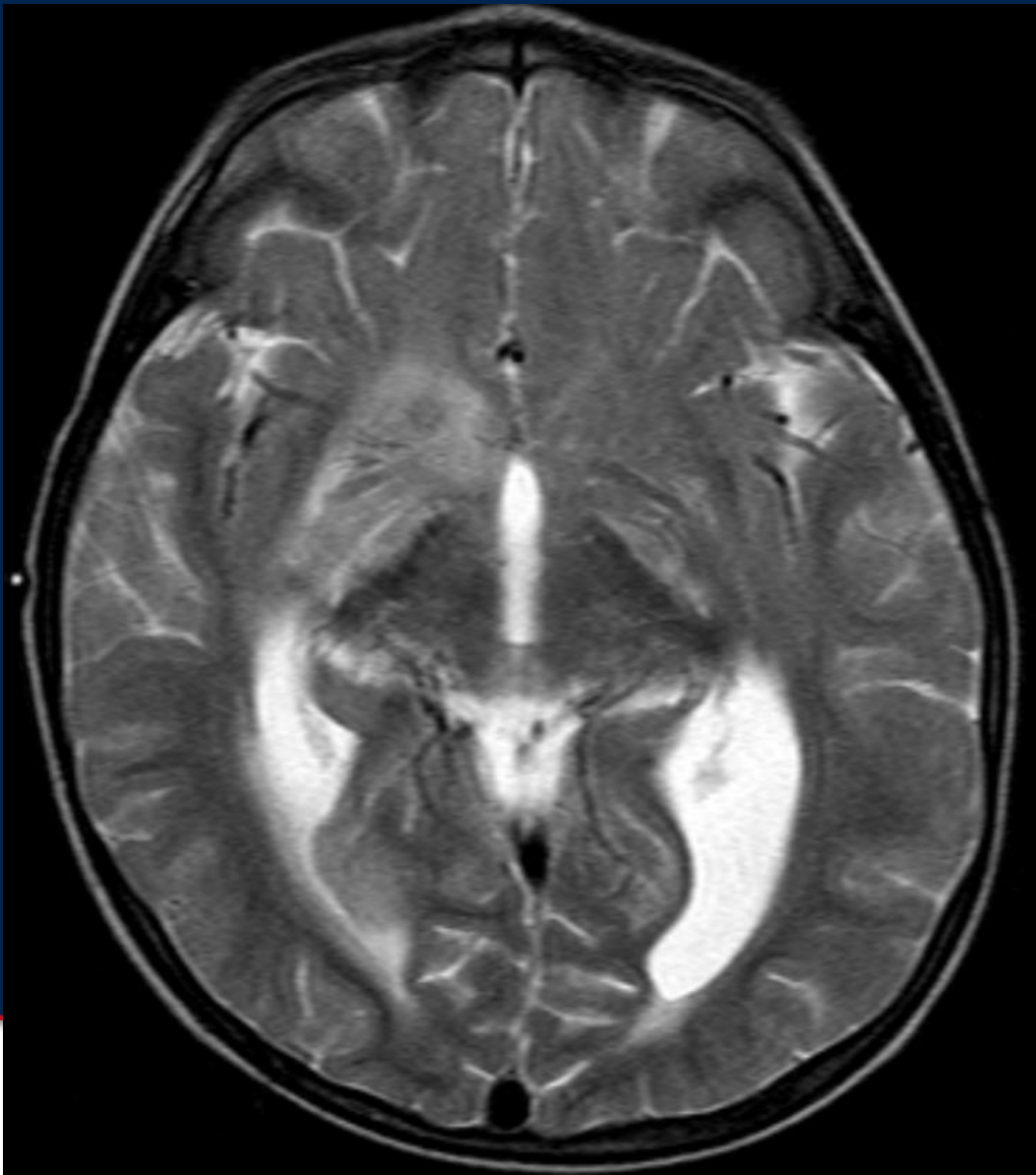
CSF: 52 WBC (13S/70L/17M), 43 RBC, protein 326, glucose 42

Leptomeningeal enhancement

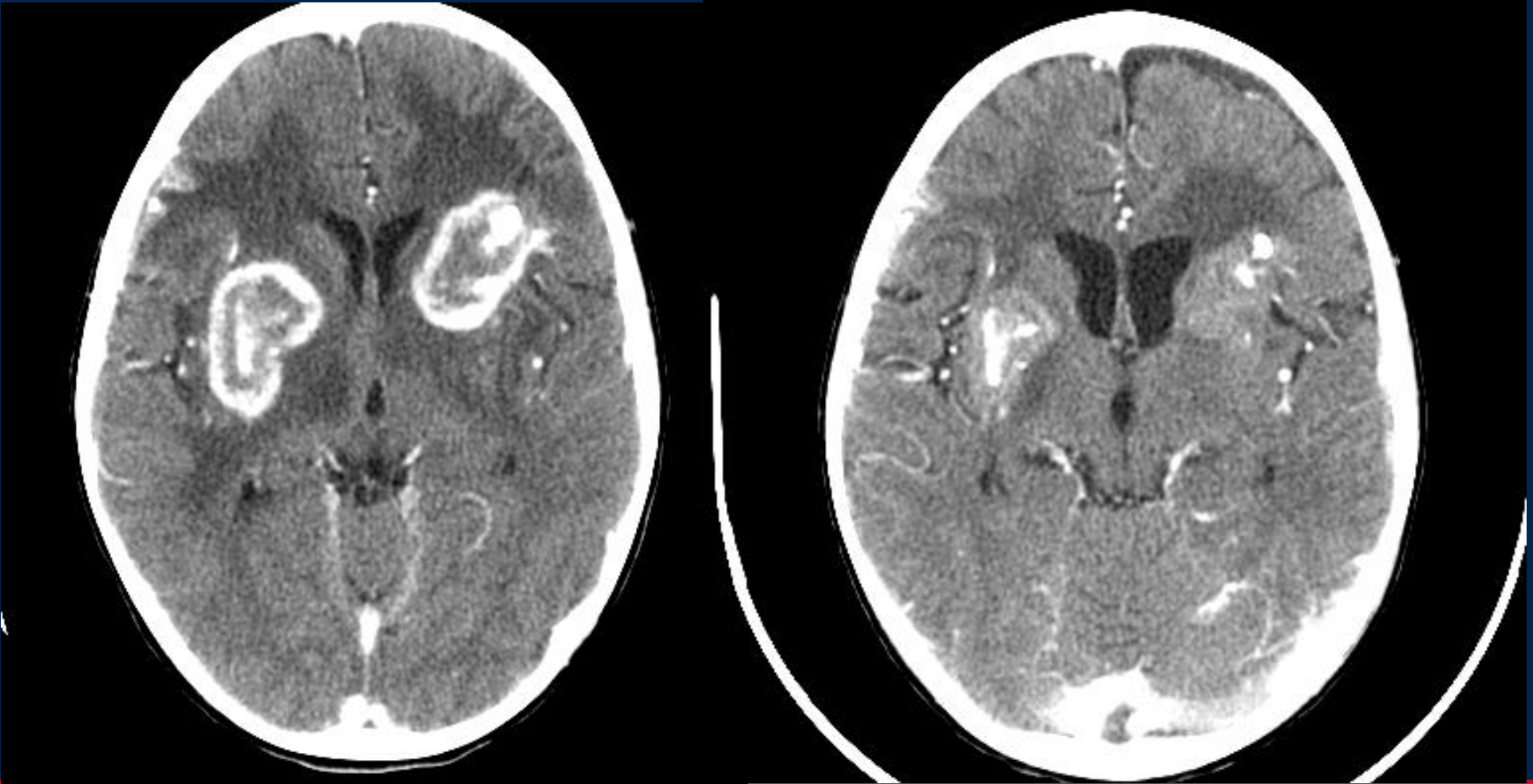


Advanced leptomeningitis with basilar predominance to include extensive neural/perineural disease of the bilateral cranial nerves and proximal cervical nerve roots. In combination with multifocal infarct of the brainstem and left hypothalamus, mild vasospasm of the proximal anterior circulation findings are most consistent with atypical infection, especially mycobacterial infection/tuberculosis.

Infarcts



Tuberculomas



At initiation of therapy

After 2 months of therapy

Who do I tap?

- *Assuming it is safe to tap them from a herniation standpoint; would obtain CNS imaging first*
- Any child with symptoms concerning for TB meningitis
- Any infant in first year of life with suspected pulmonary TB
- Consider in any child with miliary pattern on CXR

Who do I image, preferably with MRI?

- All children with pleocytosis
- Children too unstable to do lumbar puncture
- All infants with miliary TB, even if they do not have a CSF pleocytosis
- Why do I image?
 - Can see tuberculomas in absence of meningitis
 - Young children can have unreliable physical examinations
 - Exam findings can be subtle early on
 - Changes management

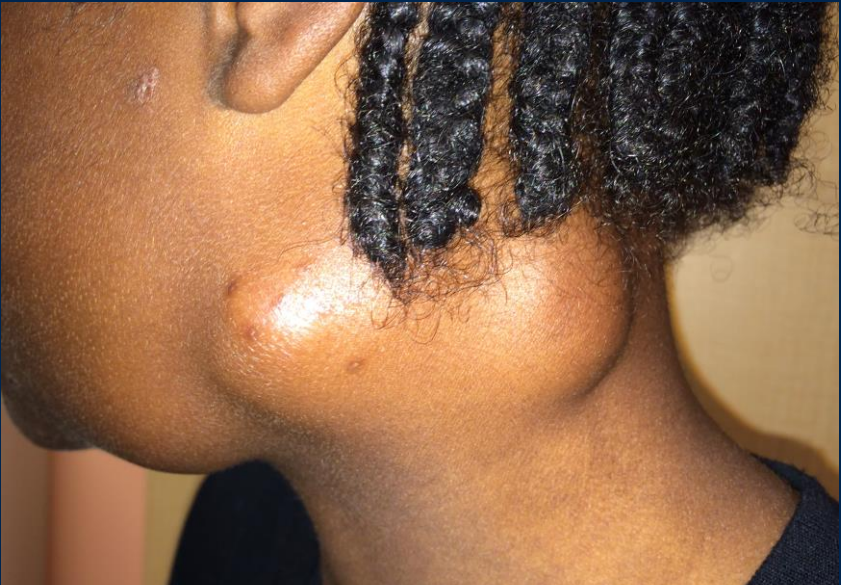Why do we insist on LP (and MRI)?

- Changes drugs used
 - Ethambutol penetrates blood/brain barrier poorly, so we instead use ethionamide or a quinolone
- Changes decision to use systemic steroids
 - Usually 1 month with slow taper
- Changes duration of therapy
 - Minimum 9-12 months for CNS TB
- Changes prognostic conversations
 - Most children with TB meningitis suffer sequelae

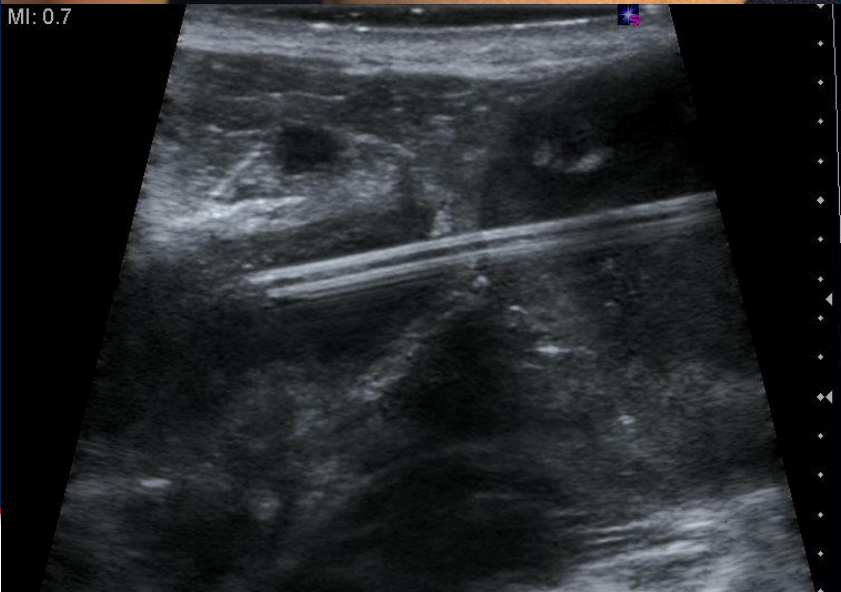
TB adenitis

- Painless, can be come tethered to overlying skin, central fluctuance
- Reddish or violaceous discoloration
- Can form draining sinus tracts
- AVOID incision and drainage; prefer FNA or needle aspiration

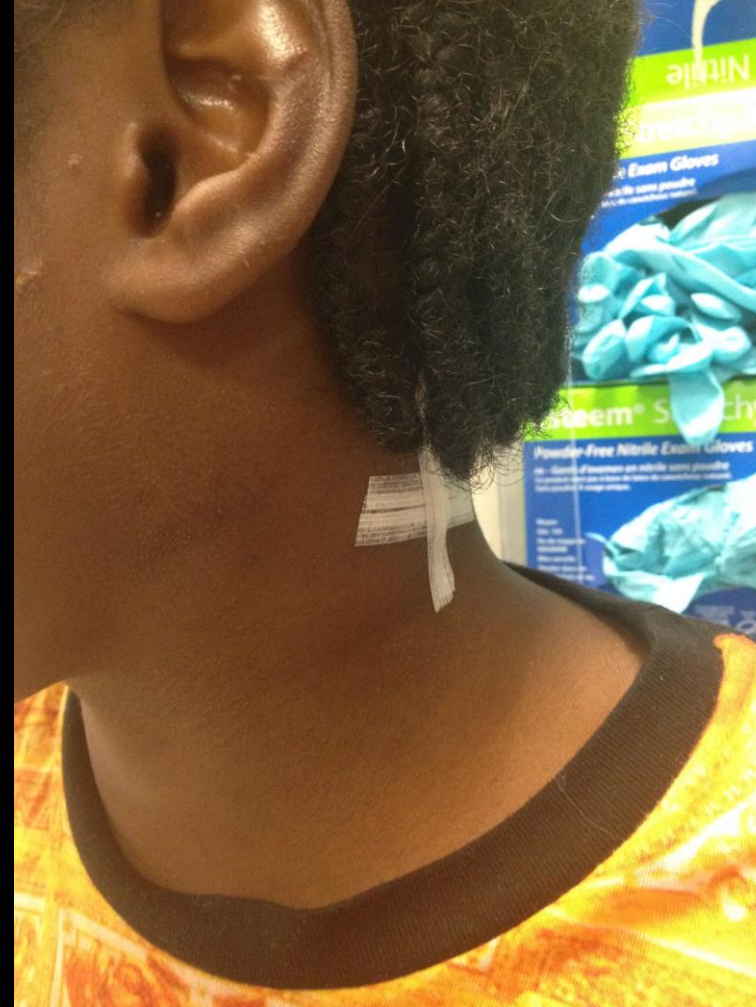TB Cervical Adenitis



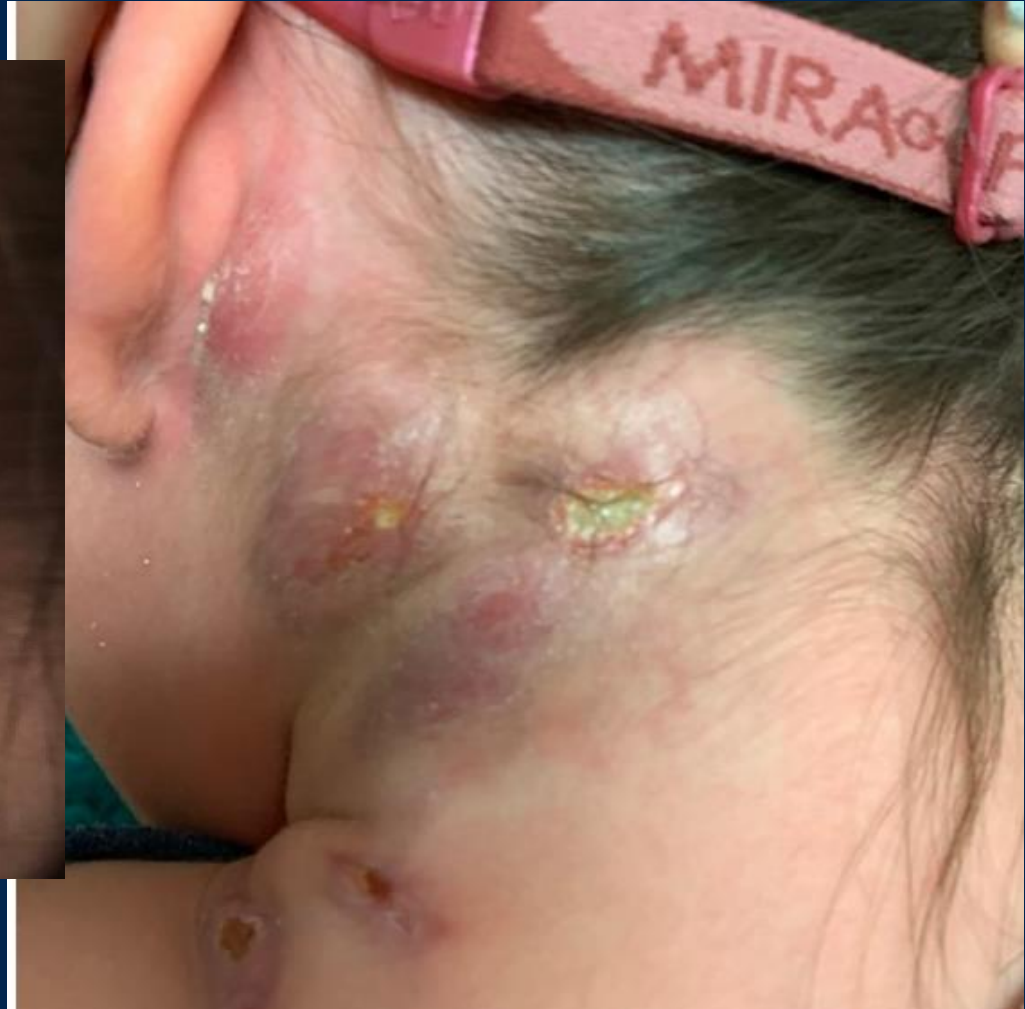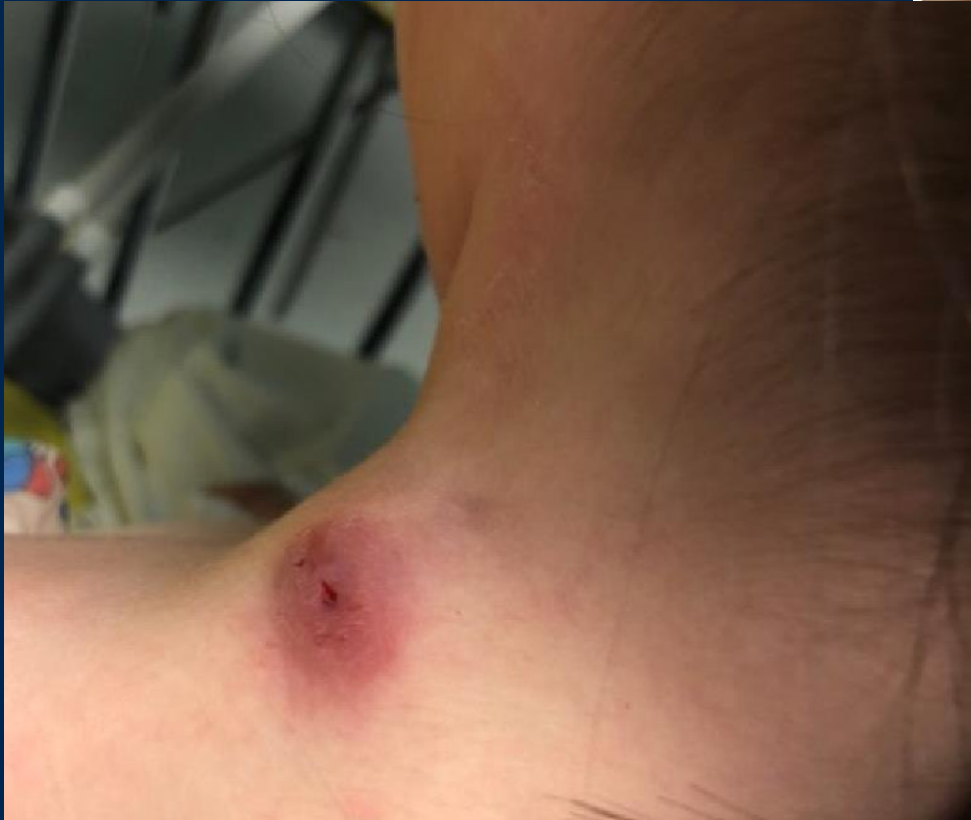MI: 0.7



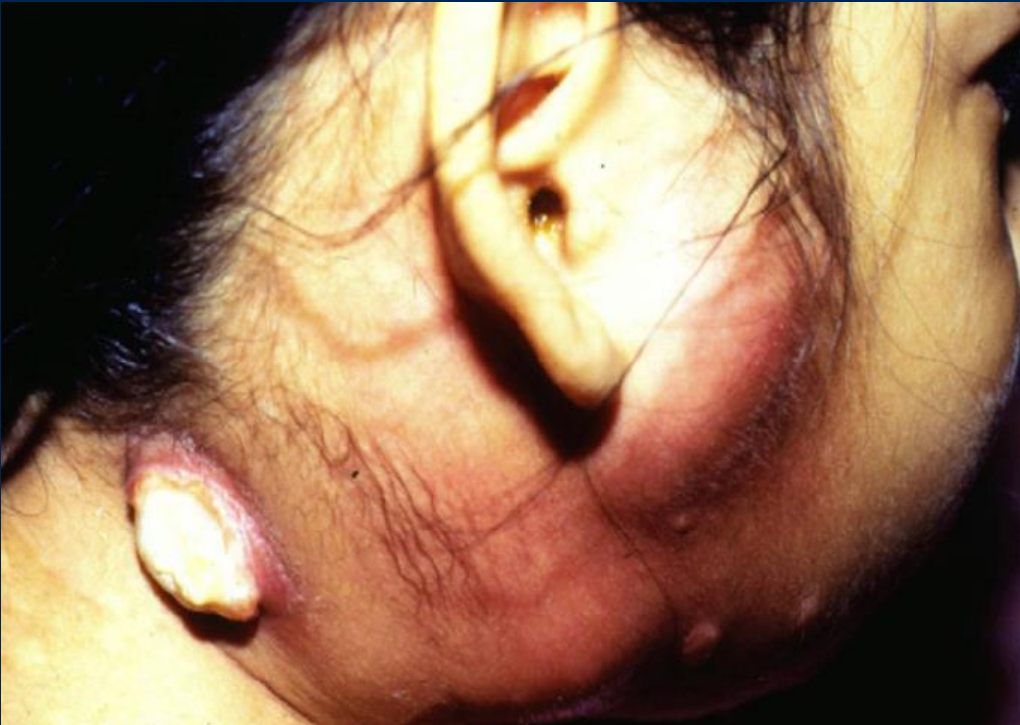40fps 3cm



TB Cervical Adenitis



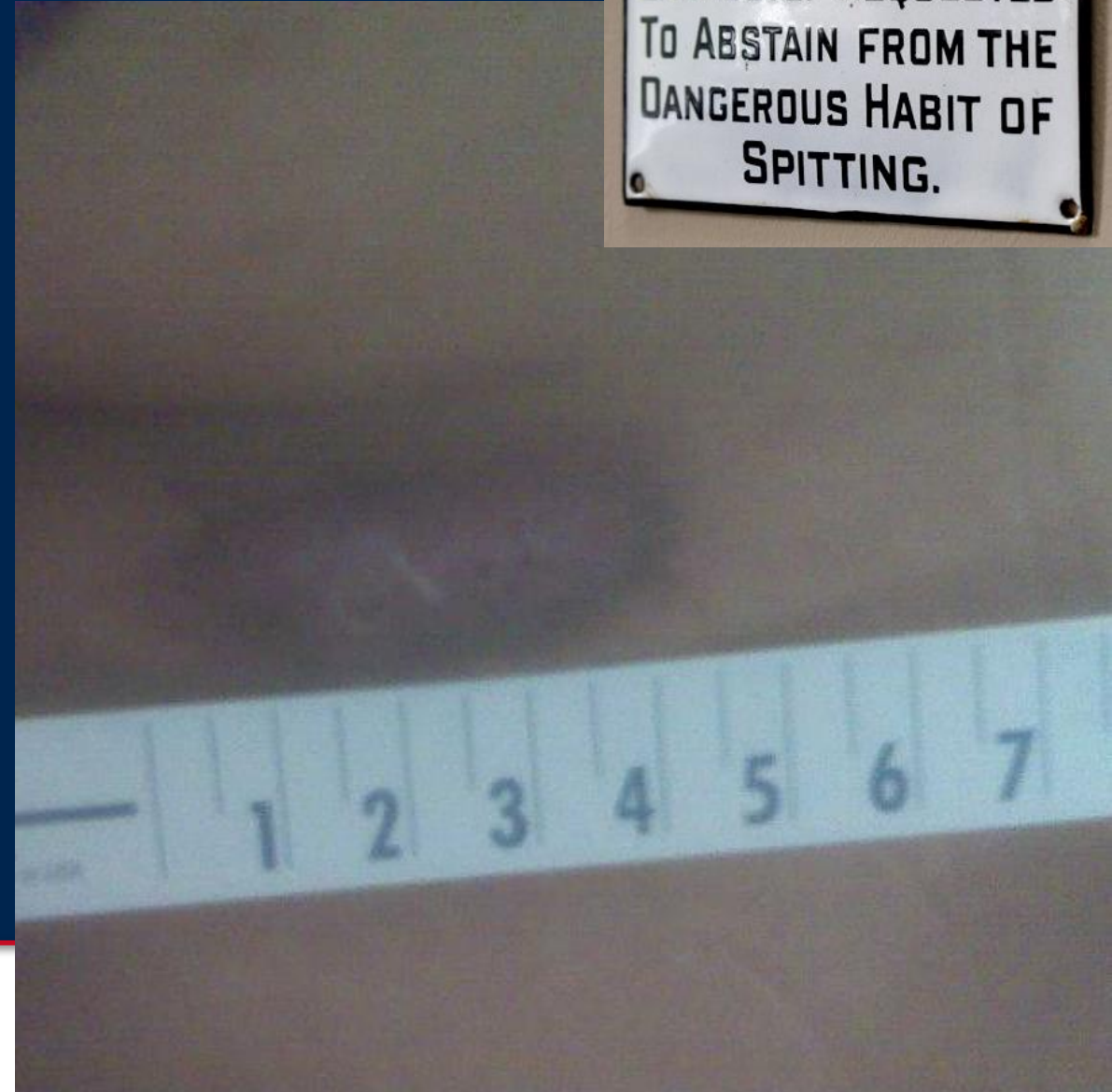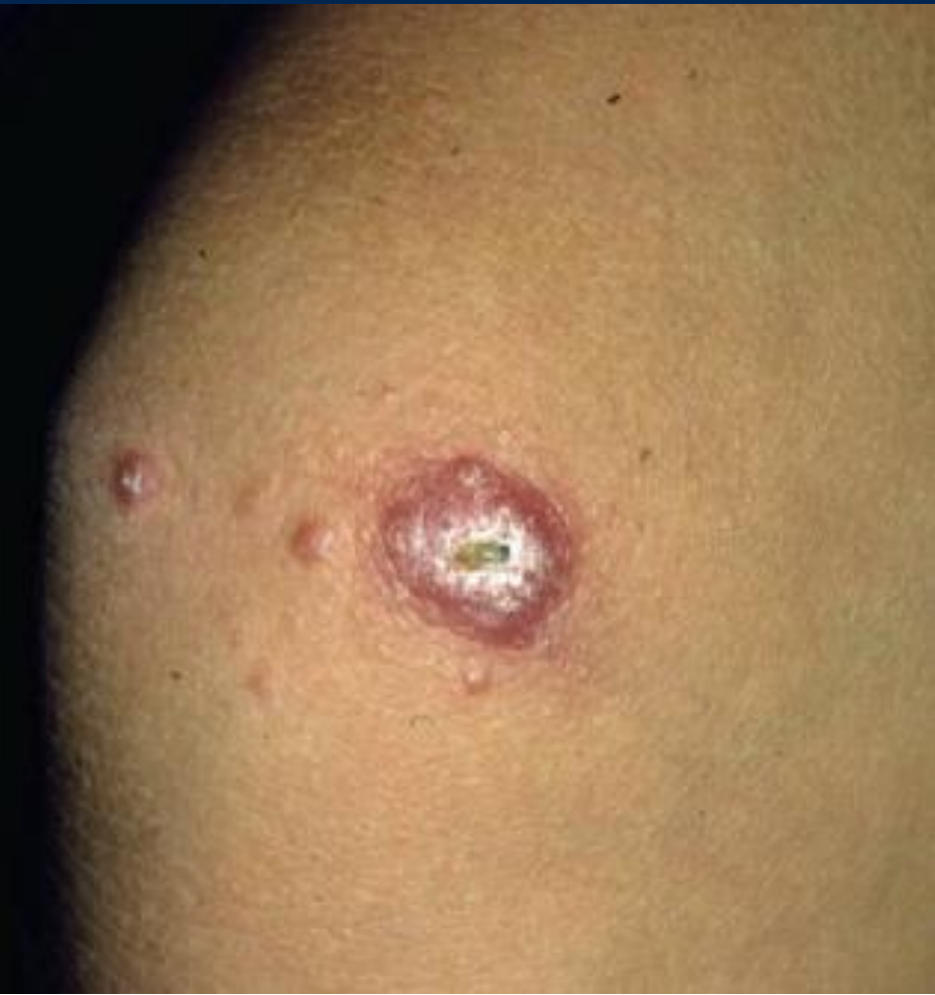Lymphadenopathy + Scrofuloderma



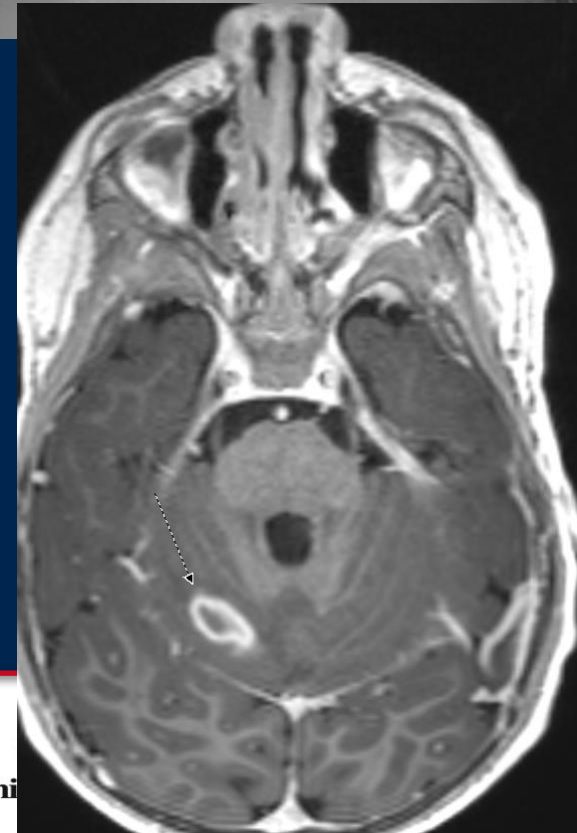
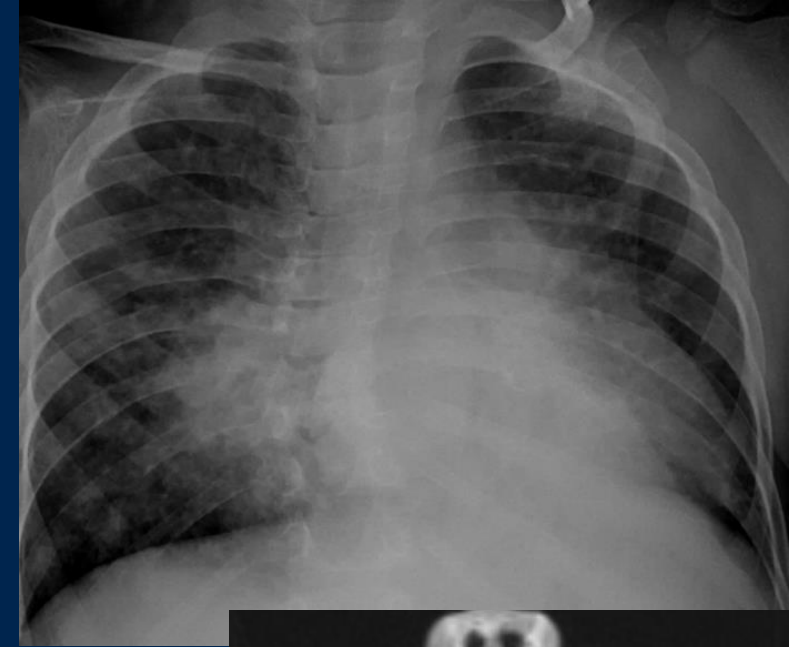
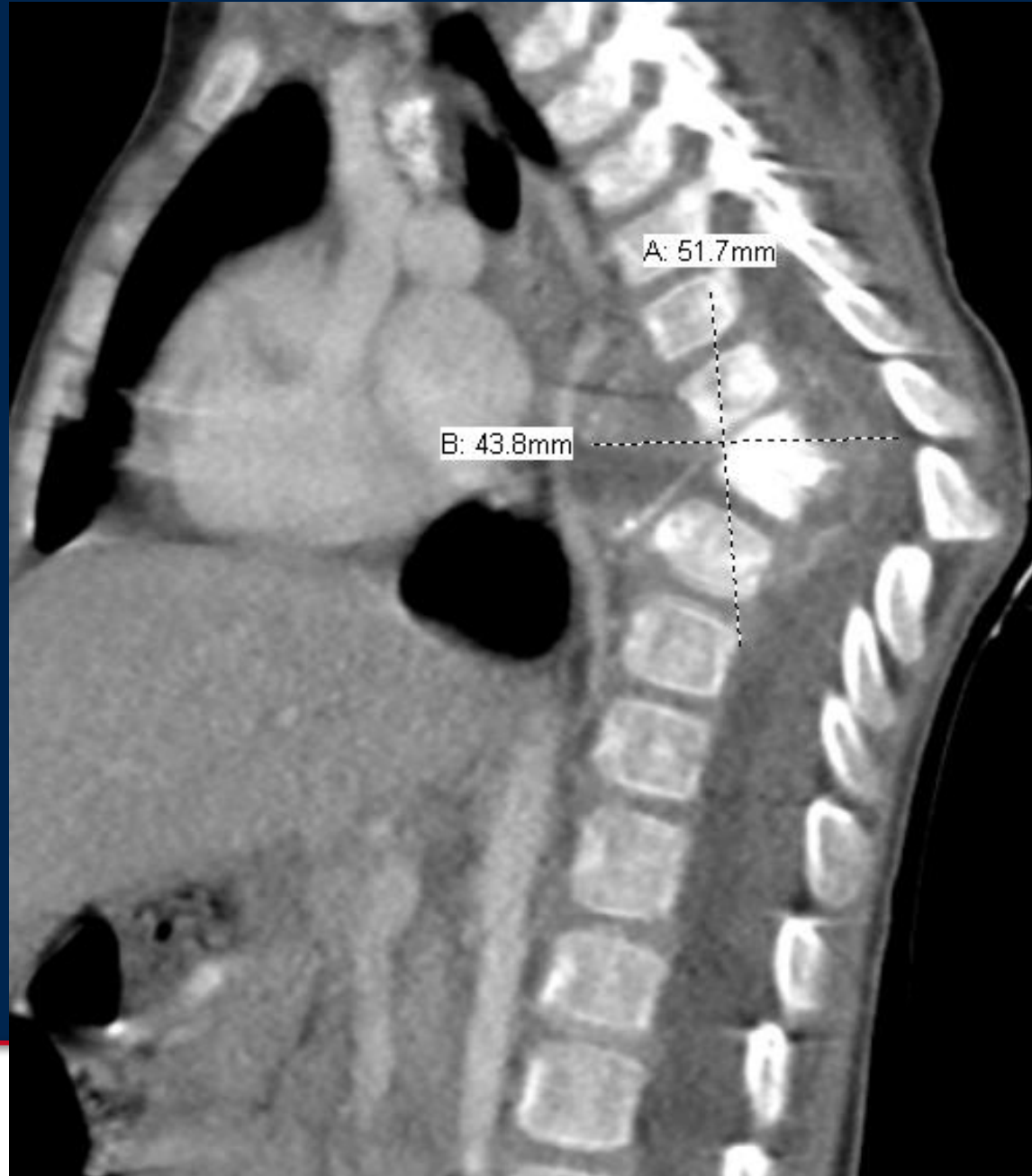
NATURAL SELECTION

Now you know it really works.

Cutaneous TB: Lupus vulgaris



Potts



Diagnosis



**Texas Children's
Hospital®**

BCM
Baylor College of Medicine

Pediatrics

Baseline testing

- CBC, HIV, LFTs
- Order T-SPOT and QuantiFERON interferon gamma release assays [IGRAs], place TST
- Xpert TB PCR (also detects RIF resistance)
- CXR, other appropriate imaging studies
- LP if indicated
- CXRs on 2 caregivers (done at TCH expense)
- Respiratory samples: gastrics vs sputum induction vs expectorated sputa

Acid-Fast Culture Yield

Specimen	Culture Yield
Sputum/gastric aspirate	30-40%
Lymphatic tissue	75%
Pleural fluid	20-40%
Cerebrospinal fluid	20-50%
Pericardial fluid	0-42%
Ascitic fluid	30%
Skin biopsy	20-50%
Skeletal biopsy	75%

Diagnosis of pediatric TB

- Given poor culture yield, the diagnosis of childhood TB is usually based on the following triad:
 - Positive PPD or IGRA
 - Compatible radiographic and/or clinical findings
 - Epidemiologic link to a person with known or suspected TB

If you wait upon microbiologic confirmation for children with suspected TB, you will be grossly under-diagnosing pediatric TB and kids will die

Public health contact tracing invaluable

Initial regimens (*not discussing MDR*)

- Non-CNS:

- Rifampin, INH, pyrazinamide, ethambutol (RIPE)
- SHINE Trial results: 4m course of therapy

- CNS: Start **minimum 4-drug** therapy

- INH, rifampin, pyrazinamide, **ethionamide**, and often add another drug (e.g., **levofloxacin**)
- Steroids
- Consider admission to the ICU

Who gets steroids?

- Always:

- CNS disease (meningitis, tuberculomas)
- Pericarditis

- Sometimes:

- Pleural disease
- Bulky lymphatic disease
- Endobronchial disease
- Immune reconstitution / paradoxical worsening

Acute decompensation

- Neurologic:

- Hydrocephalus
- Shunt malfunction
- Worsening of tuberculomas

- Respiratory:

- IRIS with worsening of adenopathy around the airway
- Pneumothorax (tension or otherwise)
- Erosion into vessel

- Cardiac(ish):

- PEA in child with miliary disease: needle the chest

Notes on TB Drugs

Drug	Side Effects	Other notes
INH	Peripheral neuropathy; seizures in overdose	B6 helps prevent neuropathy and is only treatment for INH seizures, but doesn't prevent hepatotoxicity
RIF	Orange discoloration of secretions; inactivates oral contraceptives; many drug interactions	Please warn of Astros-orange urine!
PZA	Can increase uric acid → gout symptoms; rash	Of 1 st -line drugs, greatest association with hepatotoxicity
EMB	Optic neuritis, red-green color blindness	Despite side effects, has very poor CNS penetrance and not used for meningitis

*All primarily hepatically metabolized, except EMB, which is also renally excreted

Diagnosis: TB Infection

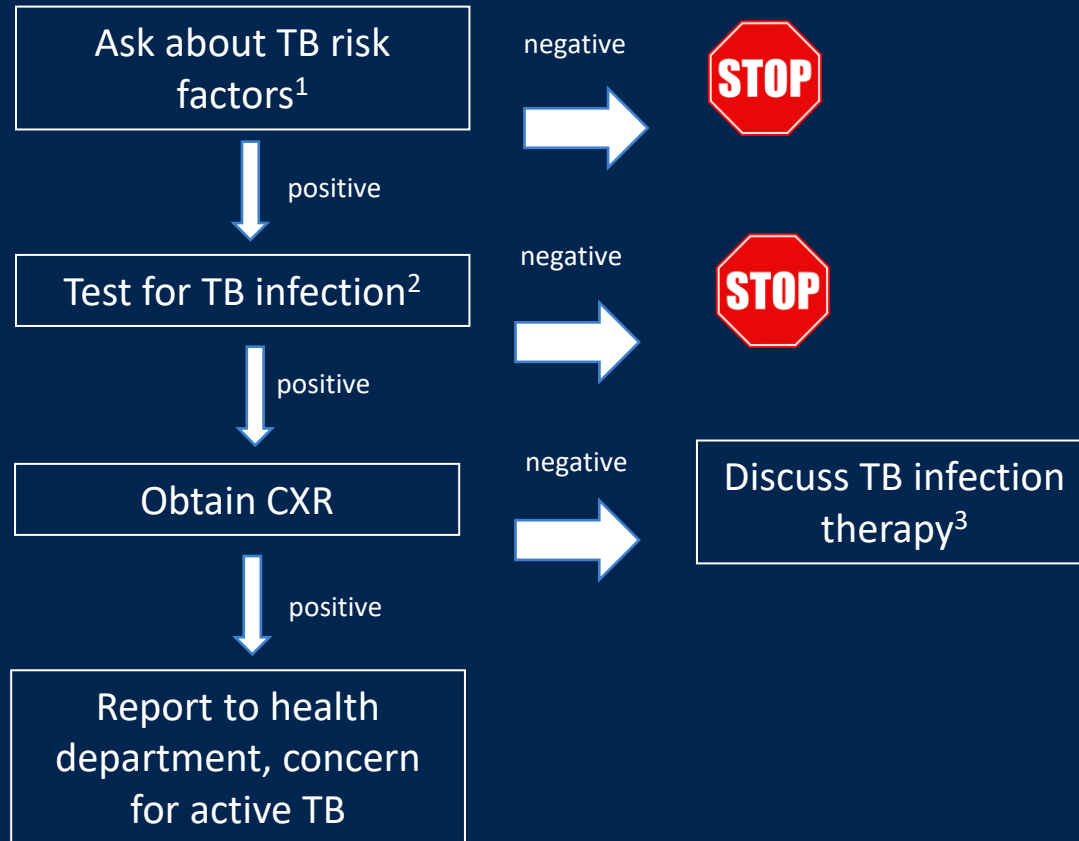


**Texas Children's
Hospital[®]**

BCM
Baylor College of Medicine

Pediatrics

Algorithmic Approach to TB Testing



1:

- *Epidemiologic risk factors:* birth in or prolonged travel to a high-prevalence nation, contact to TB case or person with infection
- *Medical risk factors:* HIV+ or immunocompromised

2:

- Interferon gamma release assays (IGRAs)
- Tuberculin skin test (TST)

3:

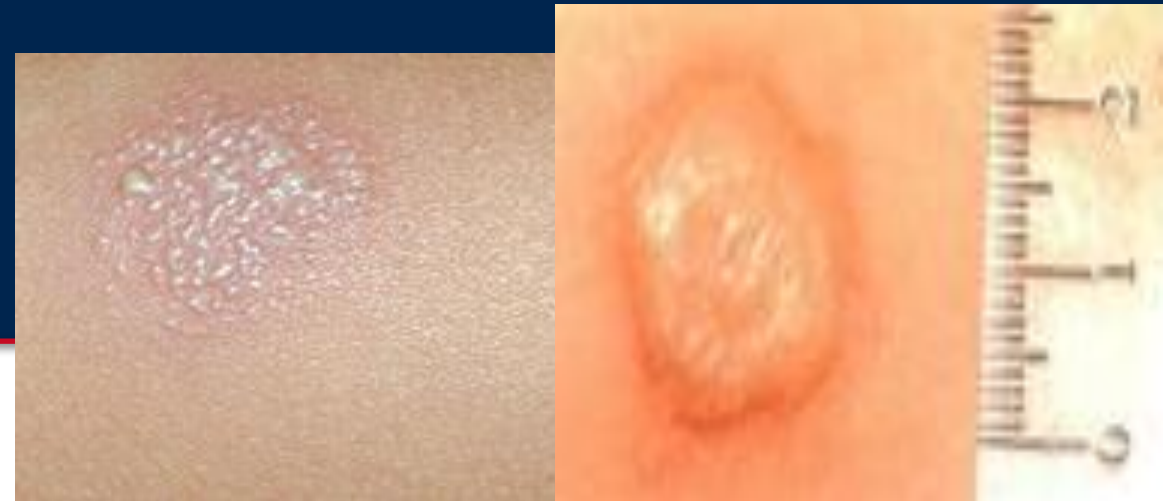- Isoniazid + rifapentine
- Rifampin
- Rifampin + Isoniazid
- Isoniazid

Comparison of Skin Test & IGRA

Characteristic	TST	IGRA
Antigens studied	Many -PPD	ESAT-6, CFP-10, (TB-7.7)
Cross-reactivity with BCG	Yes	Unlikely
Cross-reactivity with NTM	Yes	Less Likely
Estimated sensitivity, TB in immunocompetent adults	75-90%	75-95%
<i>Estimated specificity, TB in immunocompetent adults</i>	<i>70-95%</i>	<i>90-100%</i>
Distinguish between TB infection and TB disease	No	No
Boosting	Yes	No
Patient visits required	Two	One

Positive TSTs

- Generally, skin test conversion occurs within 2 months of contact
- Measure only **induration**
- **Record millimeters of induration (never record “+” or “-”)**
- Any induration seen only in the first 24 hours should be ignored
- Induration after 72 hours counts
- Blistering also counts



What is a Positive TST result?

≥ 5mm	≥ 10mm	≥15mm
Living with HIV	Children < 4 years of age	Anyone, even without risk factors
Contact to a TB case	Children exposed to high-risk adults†	
Child in whom you suspect TB disease	Immigrants from high-prevalence regions*	
	Children with diabetes or other immunocompromising conditions	

† living with HIV, incarcerated, IV drug use

*Low prevalence regions: US, Canada, Scandinavia, Western Europe, Australia, New Zealand

TST Limitations

False positives:

- Exposure to mycobacteria other than TB
- BCG vaccine

False negatives:

- Corticosteroid usage
- Other immunocompromise
- Viral suppression: measles, mumps, influenza

- Inter-observer variability
- Sliding scale for what is considered positive can be confusing
- **Until very recently**, lack of any confirmatory tests

2015-2024* Red Book: IGRAs

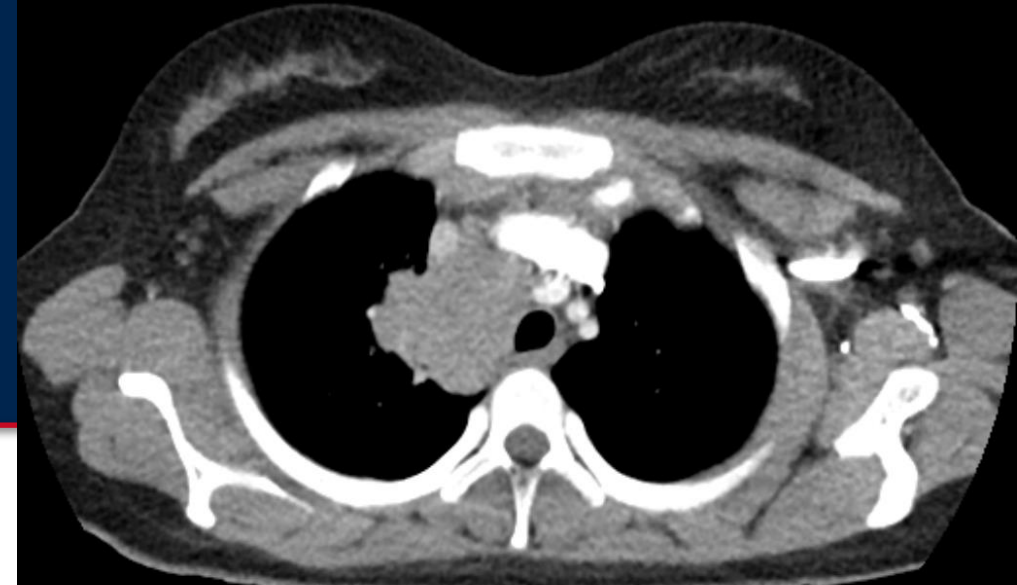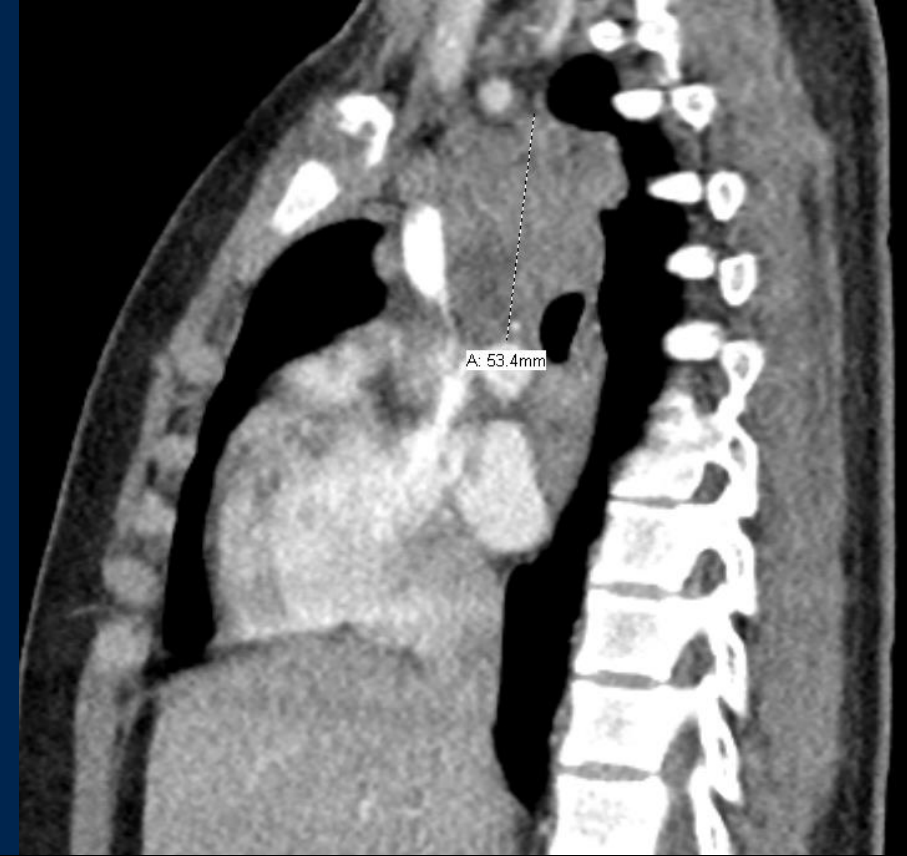Recommendation	2015	2018	2021	2024
Age	≥ 5 years	≥ 2 years	Unchanged, but indicated some experts will use down to 1 year of age	All ages!!
Preferred test for BCG-immunized children	Yes	Unchanged	Unchanged	Unchanged
Use in immunocompromised children (both TST and IGRA)	Cautiously	Unchanged	Unchanged	Unchanged

2015 -2024 Red Book: LTBI Regimens

Rec	2015	2018	2021 and 2024
Preferred regimen	INH	No specific preference (this is order in Red Book): <ul style="list-style-type: none"> • 3m INH + Rifapentine* • 4m Rifampin • 9m INH 	Several regimens are recommended, depending on circumstance: <ul style="list-style-type: none"> • 3m INH + Rifapentine • 4m Rifampin • 3m INH + Rifampin (if 3HP or 4R not feasible) • 6-9m INH • 6m levofloxacin [if MDR-TB, drug interactions]
RIF role	Limited: INH intolerance or INH resistance in child's contact	Expanded	Unchanged
3HP	Use in ≥ 12 years	Use in ≥ 2 years	Unchanged

Case 1

- 14yo F from Afghanistan, + IGRA, no symptoms
- Massive mediastinal mass, encasing the aorta, internal jugular, subclavian
- What next?

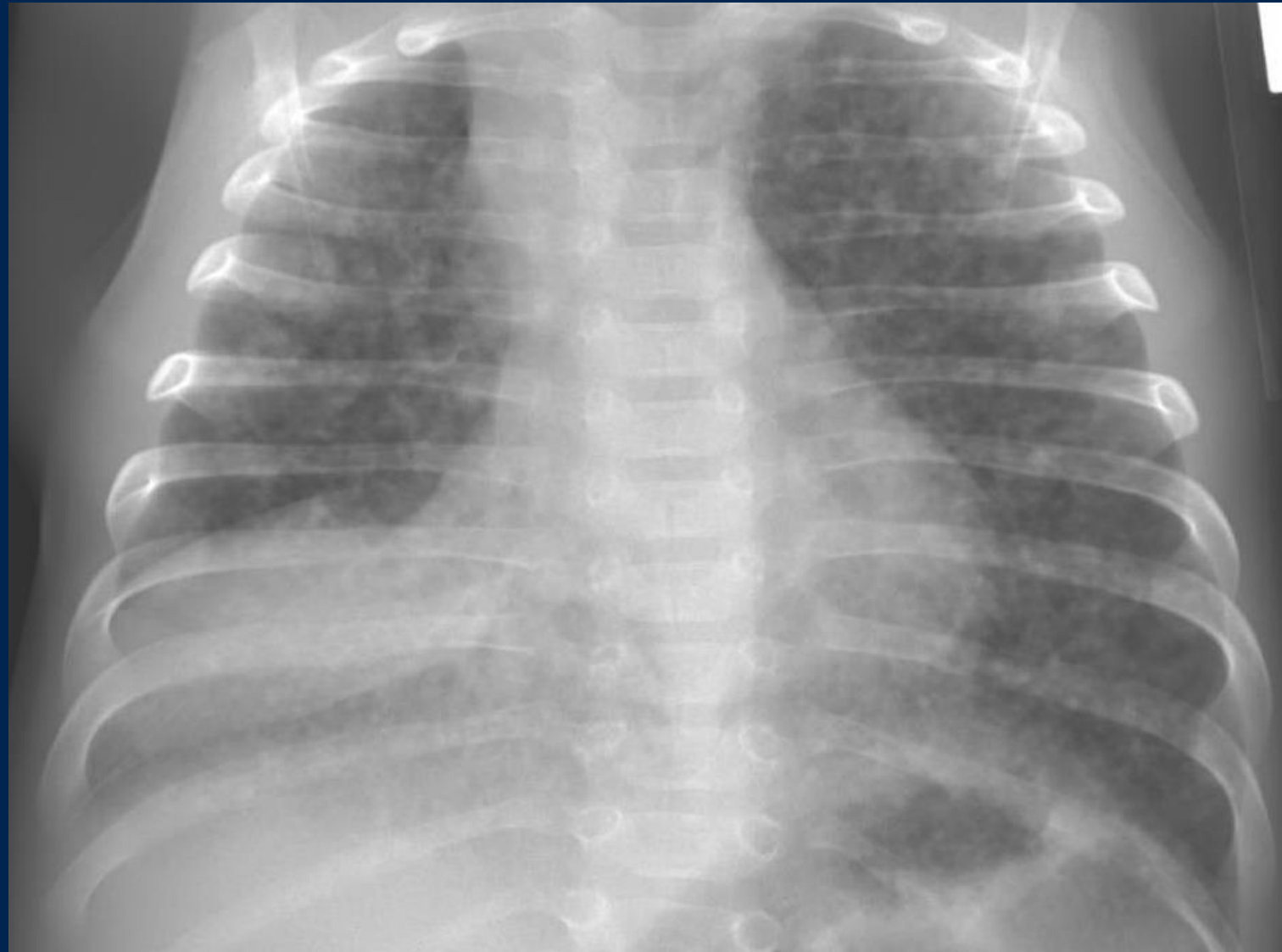


Tissue is important

- Admitted for oncology evaluation
- Trans-bronchial biopsy of the mass showed necrotizing granulomas
- Smear, PCR, culture negative
- Being treated empirically for TB

Case 2

- 3-month-old boy, US born, recurrent admissions for fever, no cause identified
- Concern for miliary TB
- CSF: 4 wbc, 5 rbc, protein 36, glucose 53, CSF PCR negative

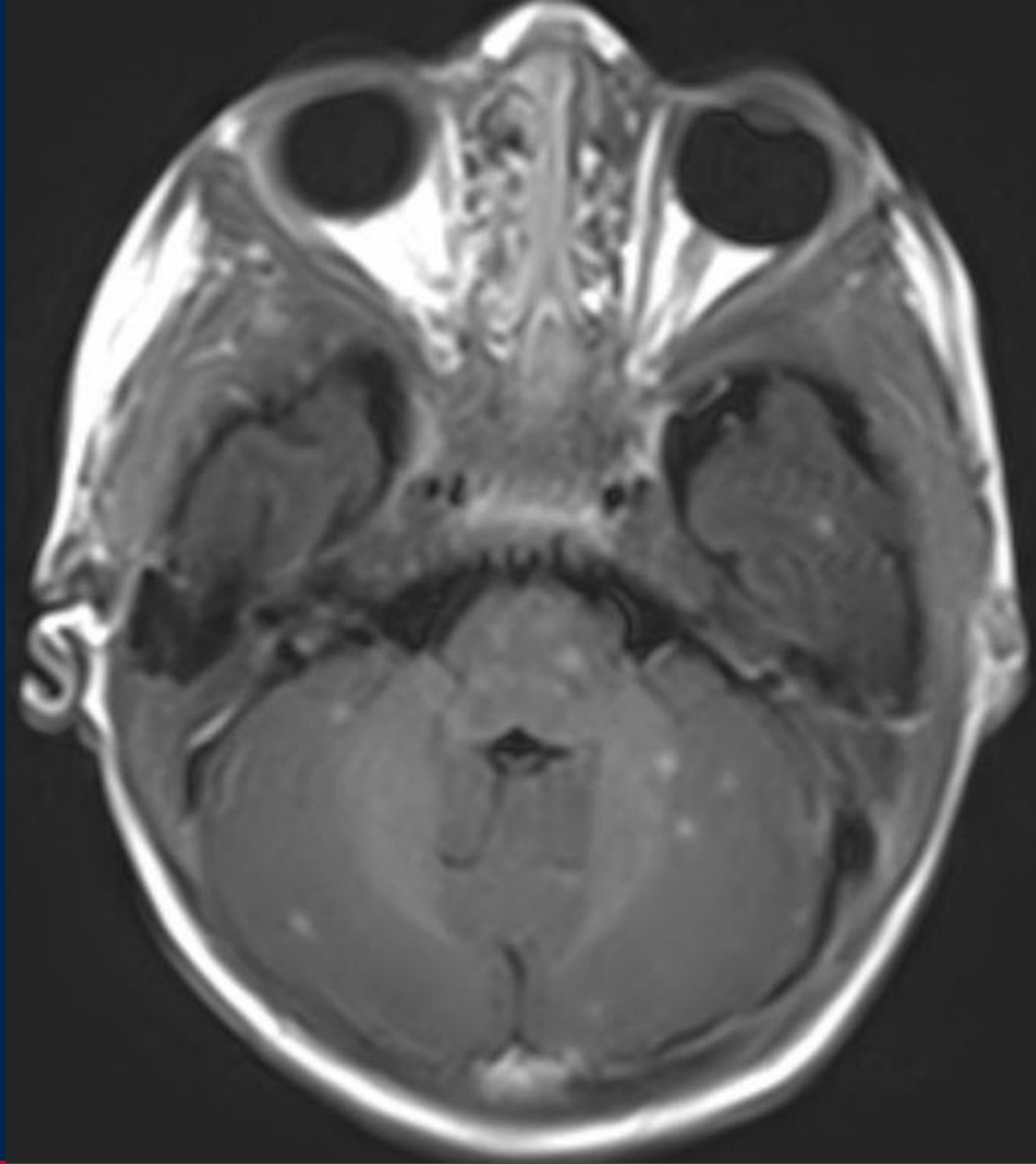


Neuroimaging is your friend!

What does this change?

- Decision to use steroids
- Use of 'E' drug

Take-home: you can see tuberculomas in absence of meningitis!



Case 3

- 6-month-old presents with fever, vomiting, seizures
- CT head shows hydrocephalus, CXR shows miliary pattern
- To OR with neurosurgery → VPS placed

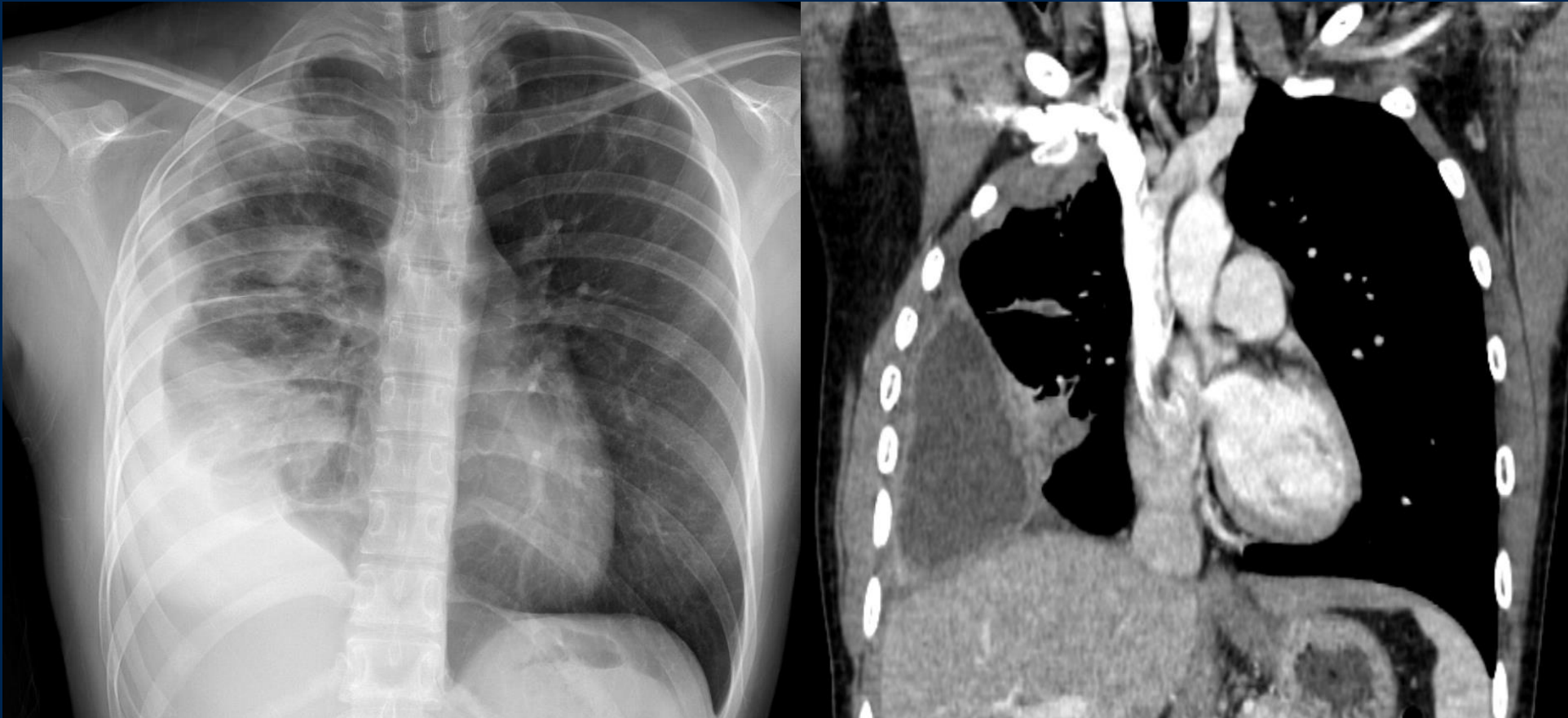Source	WBC	RBC	Protein	Glucose
EVD	10	500	46	65

Next steps

- You ask the ICU to perform an LP
- Response: Why, Andrea? We already have CSF from the EVD

Source	WBC	RBC	Protein	Glucose
EVD	10	500	46	65
LP	94	3	173	<20

Case 4: Pleural TB



When do I consider steroids?

- Worsening effusion and other factors excluded:
 - Adherence
 - Malabsorption / metabolism
 - Drug resistance
- Have to consider immune reconstitution inflammatory syndrome (IRIS)
- If tap the effusion, don't leave chest tube in!!!!

Case 5: Oy, a rash....

- 2-month-old infant exposed to her mom, who has INH monoresistant TB
- Baby asymptomatic, normal exam and CXR
- Start rifampin
- Rash → CBC, LFTs normal, no findings of anaphylaxis or DRESS
- What now?

Risk/benefit

- High risk of progression if infected
- Quinolones are well tolerated
- Could consider levofloxacin for younger children and moxifloxacin for older children

Case 5 (part deux)

- Father is in clinic with the baby
- He wonders why management is different for the baby than for his 2 older children (7, 12 years old)
 - This comes up all the time with children of different ages
- What do you tell him?

Case 5 (part deux)

- Infant's risk of progression to disease is high
 - Intrathoracic
 - Disseminated
- Less confidence in a negative test in a very young exposed infant

Change in Practice

- Children are often the first in the family to be diagnosed
 - Often, there is no apparent family history at first
- Certain combinations of symptoms and radiographic findings should increase your suspicion for TB
 - Meningitis + pneumonia
 - Pneumonia + weight loss
 - Pneumonia and lymphadenitis refractory to therapy
- Traditional culture techniques are of much lower yield in children as compared with adults
 - Start medications before microbiologic confirmation

Reference List

- Diagnosis of TB in children and adults. Clin Infect Dis. 2017;64:e1.
- Updated guidelines for using IGRAs to detect *M. tuberculosis* infection. MMWR. 2010;59:1.
- Guidelines for the treatment of LTBI. MMWR. 2020;69:1
- Updated recommendation for use of once-weekly isoniazid-rifapentine to treat LTBI. MMWR. 2018;67:723.
- Treatment of drug-susceptible TB. Clin Infect Dis. 2016;63:e147.