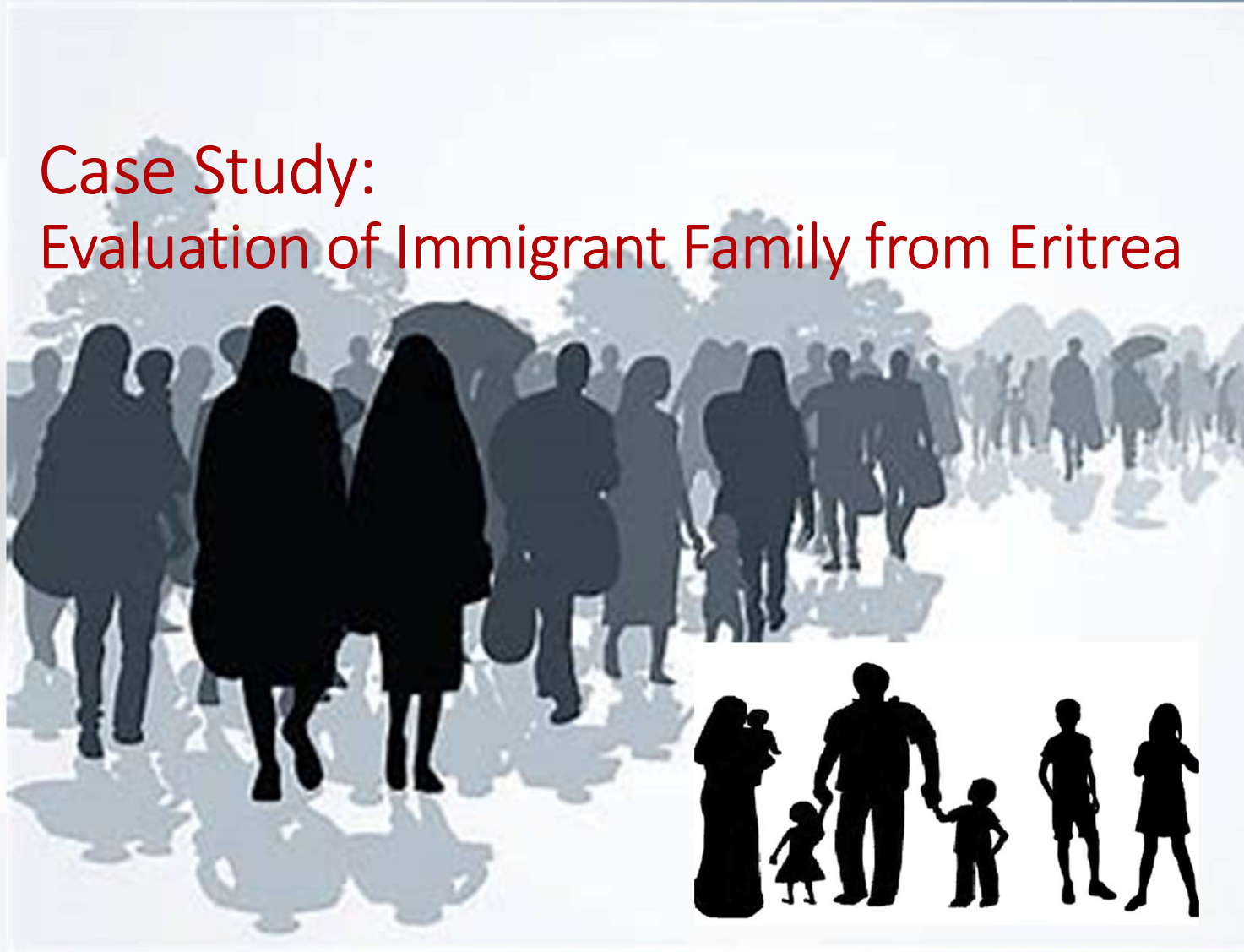



## Case Study: Evaluation of Immigrant Family from Eritrea



## Case Study

04/30/2019: 37 year old male from Eritrea (speaks Tigrigna) entered U.S. in 10/15/2016. He had no record of TB evaluation at time of entry into the U.S. and he had no history of prior TB.

He was admitted to University Hospital in San Antonio, Texas on 04/29/2019 with a 4-month history of a dry cough, feeling poorly, and weight loss.

Weight decreased from his usual weight of 63 kg down to 54 kg

He denied fever, night sweats or hemoptysis



Eritrea





Father: highly infectious pulmonary TB



32-year-old  
female  
Wife/Mother



17-mo-old  
Male



3-year-old  
Male



4-year-old  
Female



13-year-old  
Female



15-year-old  
Male





Father: highly infectious pulmonary TB



32-year-old female  
Wife/Mother

Coughing  
Lost Voice  
Weight loss  
5/2/19  
TSpot +



17-mo-old Male

Chronic cough  
< 10% on  
growth curve  
5/4/19  
TST + 14 mm



3-year-old Male

Well  
40% on  
growth curve  
5/4/19  
TST + 15 mm




4-year-old Female

Chronic cough  
50% on  
growth curve  
5/4/19  
TST + 18 mm



13-year-old Female

< 3% on  
growth curve  
Cough x1 month  
BMI 16.5  
5/2/19  
TSpot +



15-year-old Male

< 3% on  
growth curve  
BMI 17  
5/2/19  
TSpot +

