



# Introduction to Radiology For TB Nurses

**Megan Devine, MD**

Medical Consultant  
Heartland National TB Center

Associate Professor  
Internal Medicine/Pulmonary Medicine/Critical Care  
University of Texas Health Science Center at Tyler

# Chest Radiology in TB

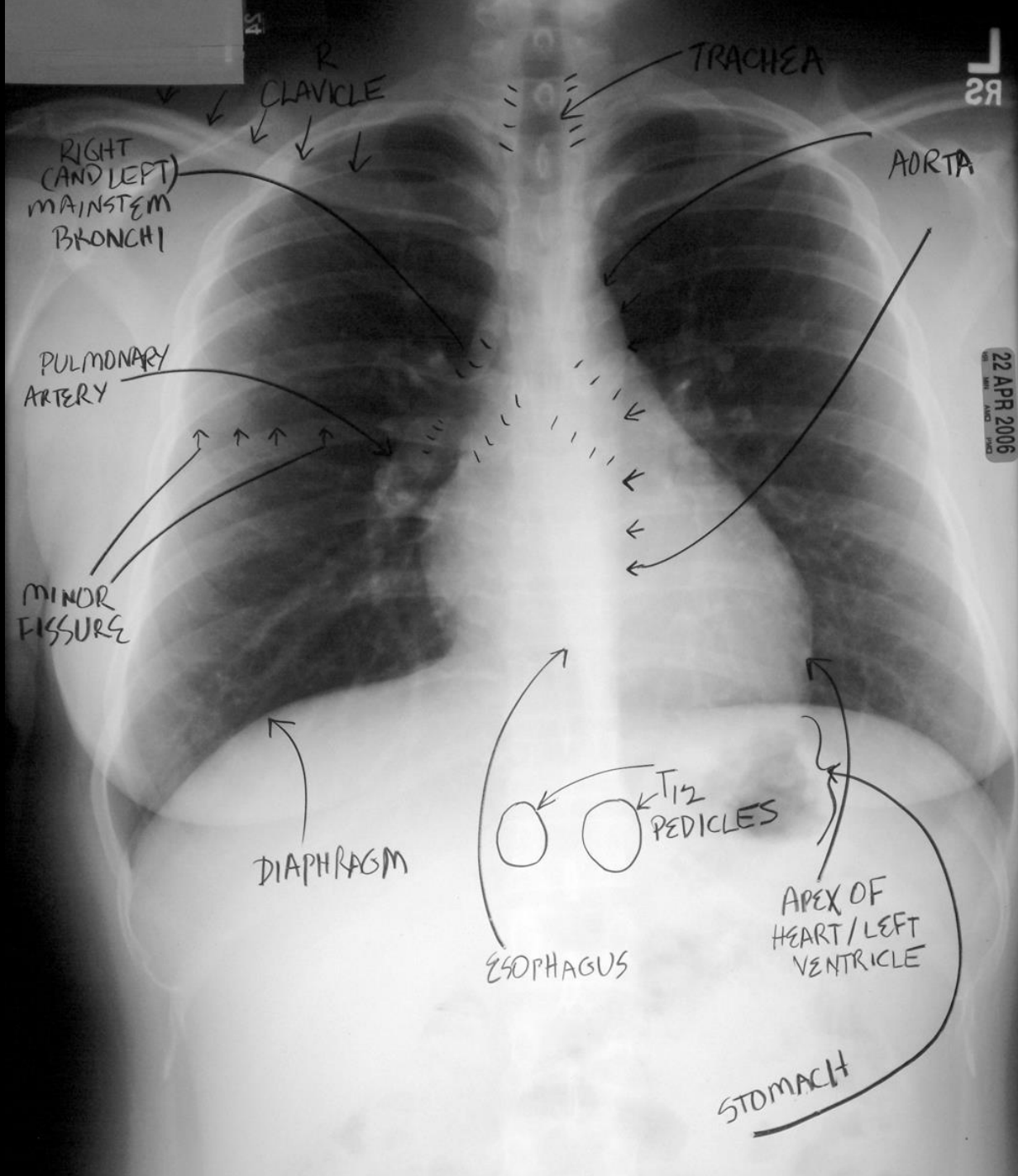
- X-Rays penetrate air, absorbed by fluids/solids
- Chest radiographs show us shadows of organs and structures in the chest
- Interpretation of a chest radiograph is pattern recognition that requires clinical correlation for true diagnosis
- To know what “abnormal” looks like, you have to know what “normal” looks like



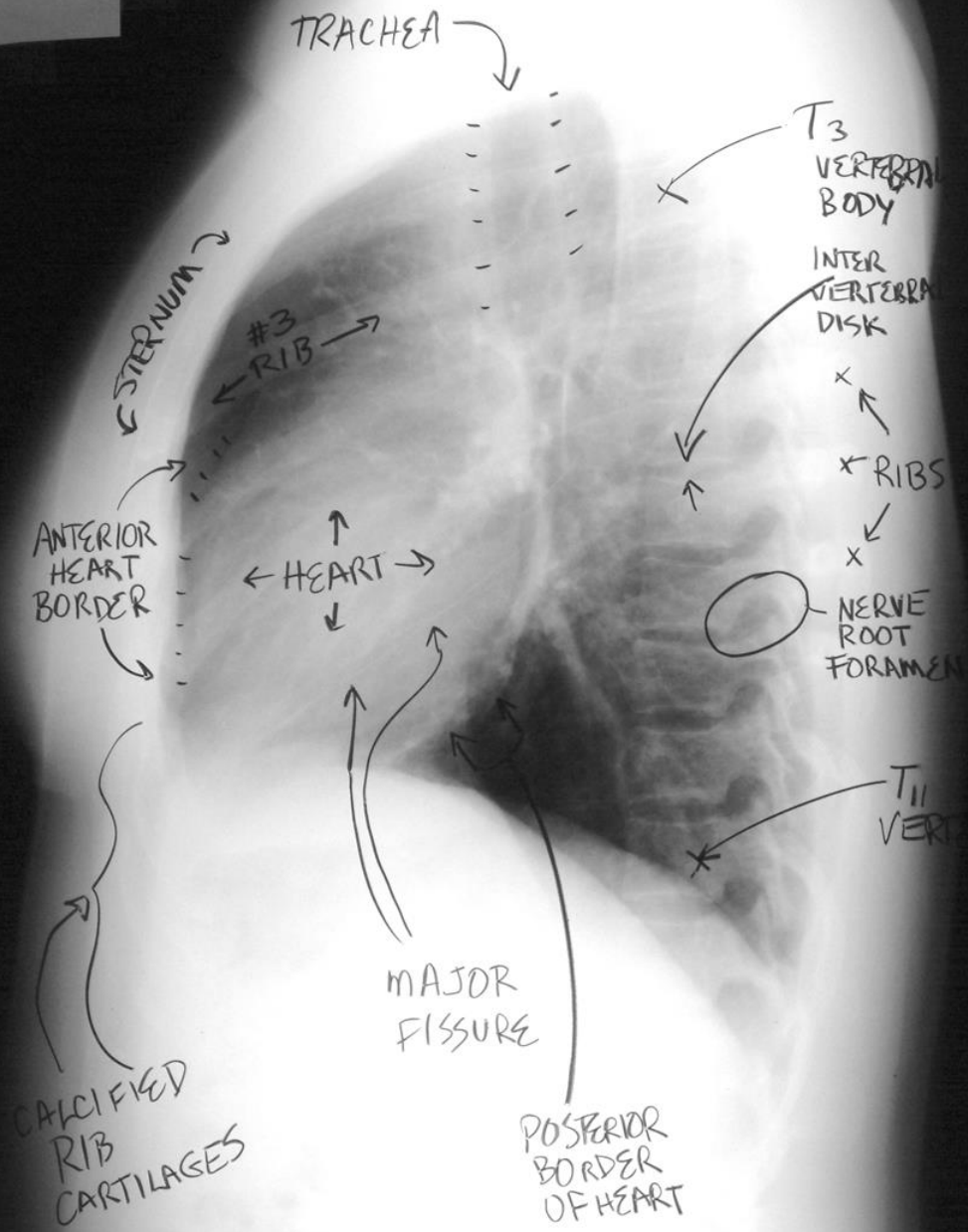
# Chest Radiology Basics

- Dark/black = Air
- Dense White = Calcium (Bone Density)
- White = Water Density (Everything else)
  - Water
  - Blood
  - Fat
  - Tissue
  - Pus

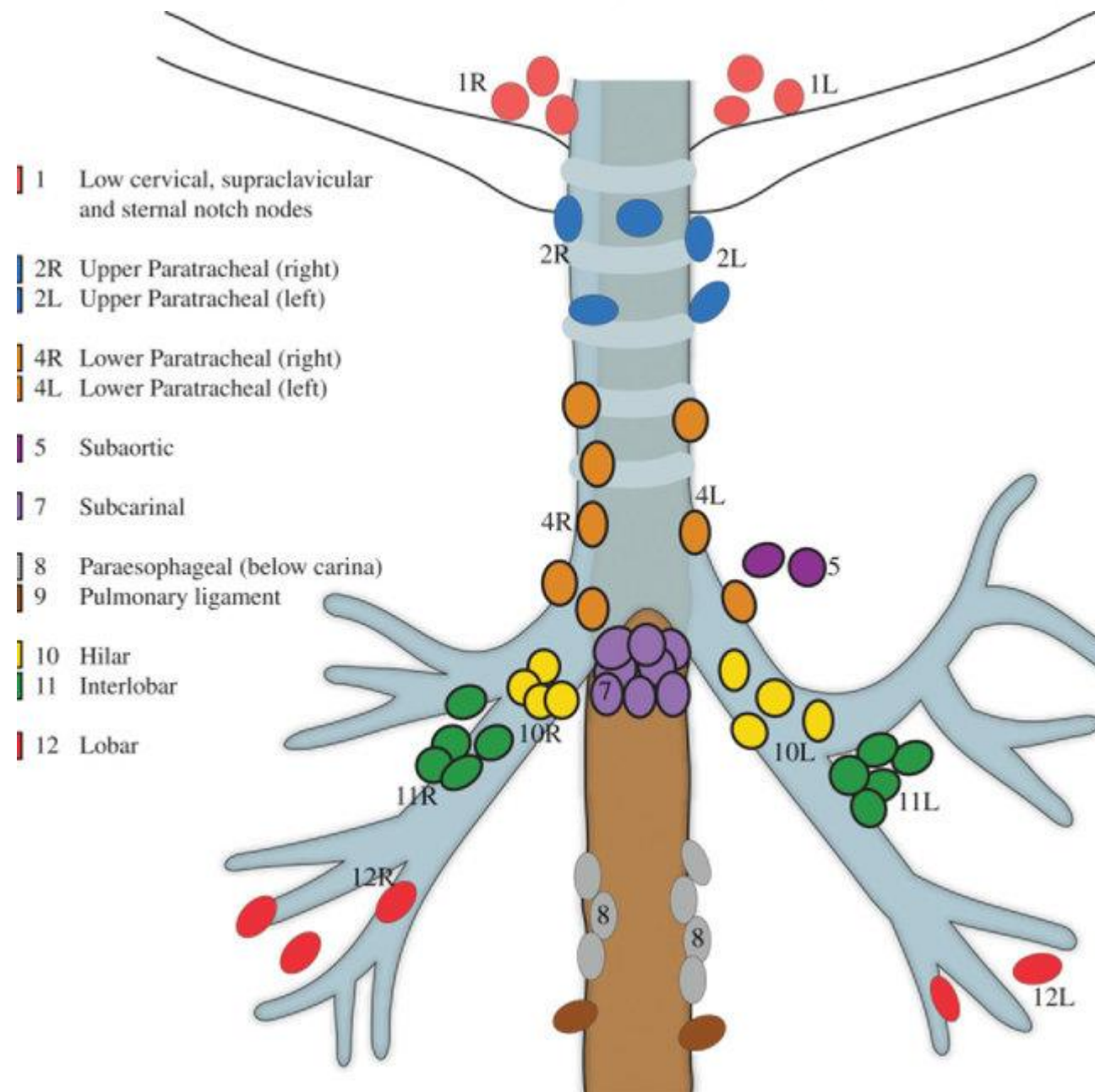




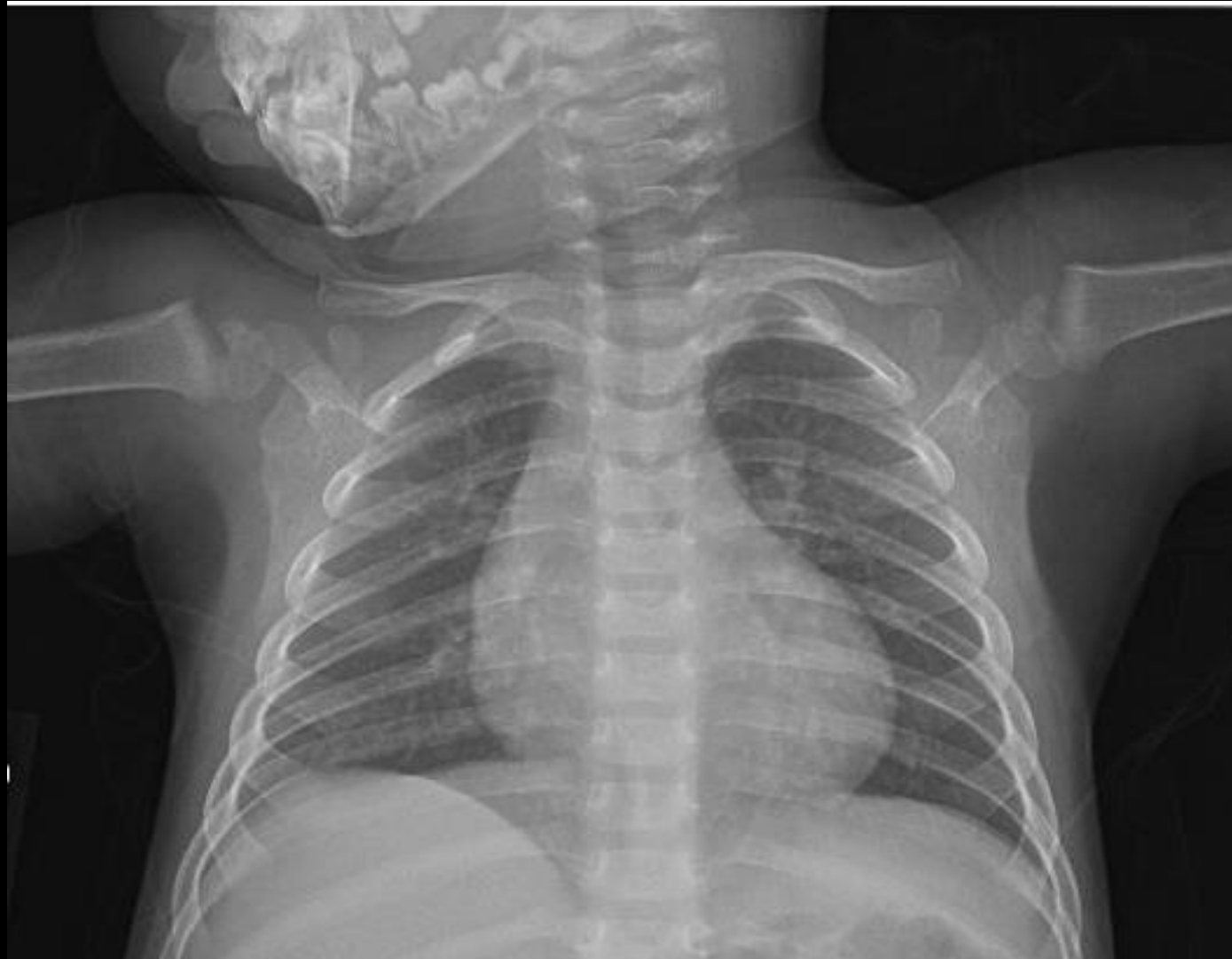22 APR 2006



# Lymph nodes in the chest



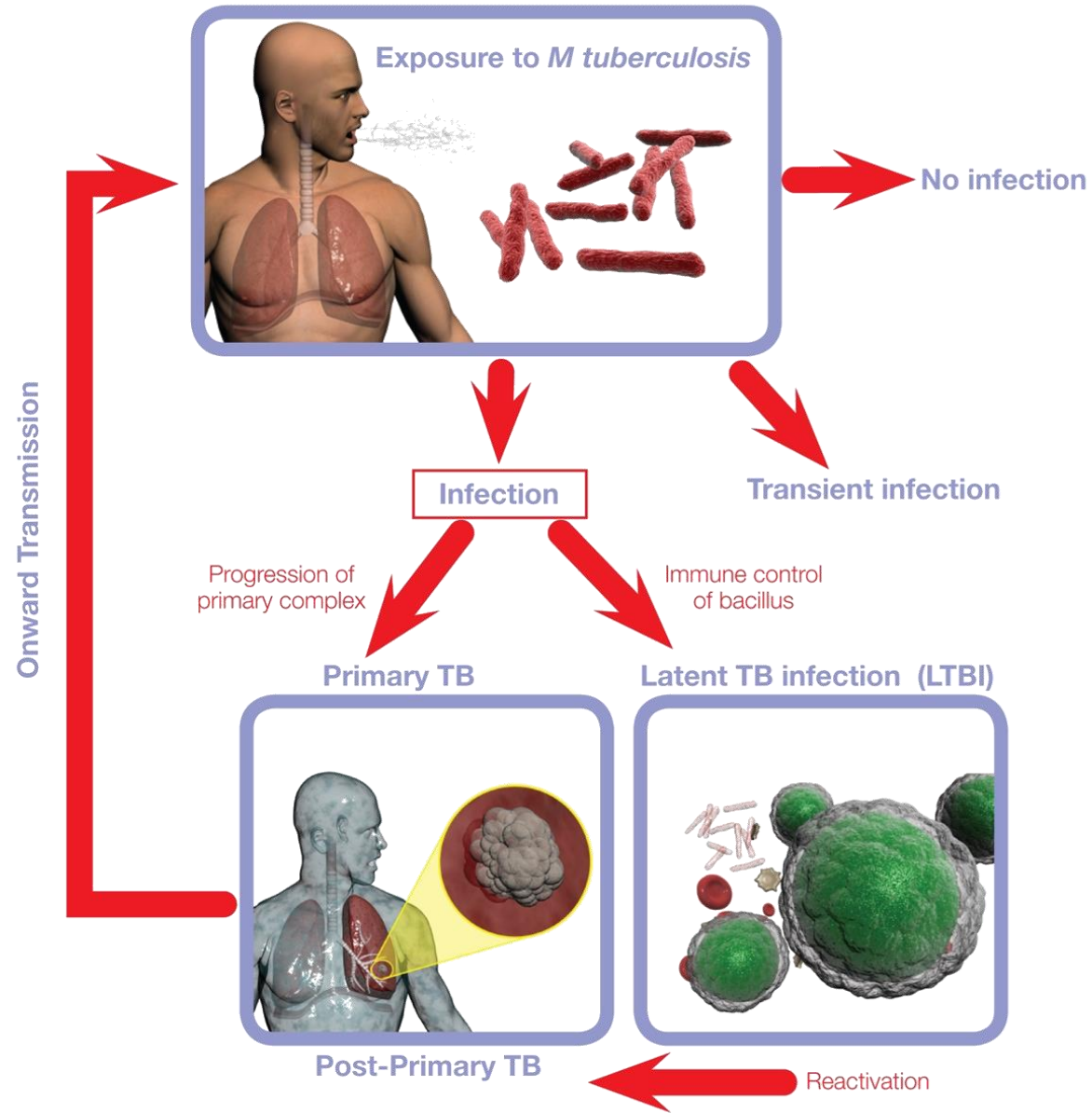
# Normal CXR Child



# Role of CT in the Diagnosis of TB

- CT is not the primary radiologic diagnostic test for TB (CT is overused in the US)
- Usually don't need CT for cavitory consolidation
- If TB is a possible diagnosis, sputum for AFB should be obtained prior to CT
- In most instances, CT should be reserved for patients in whom the diagnosis is unclear

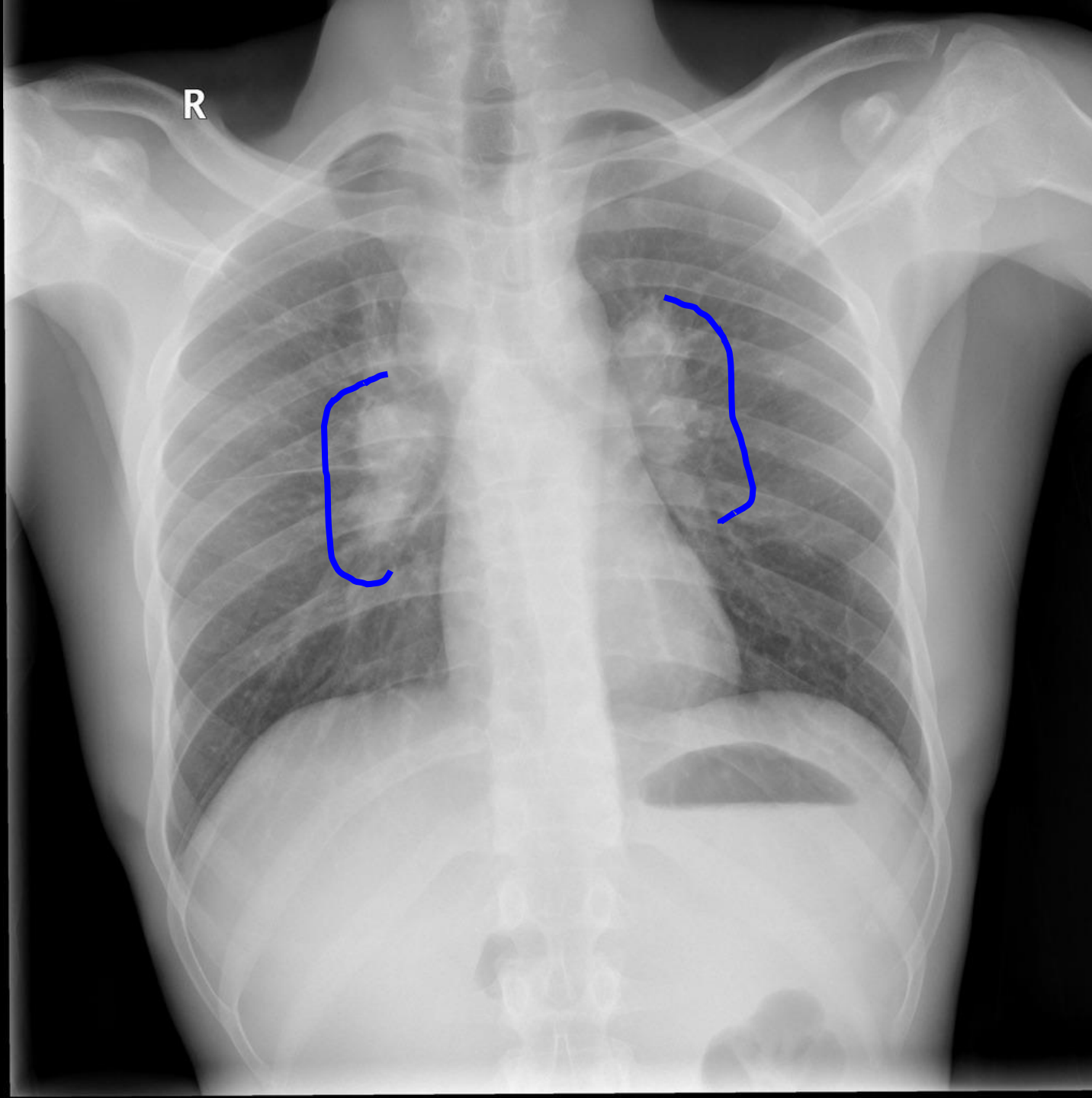


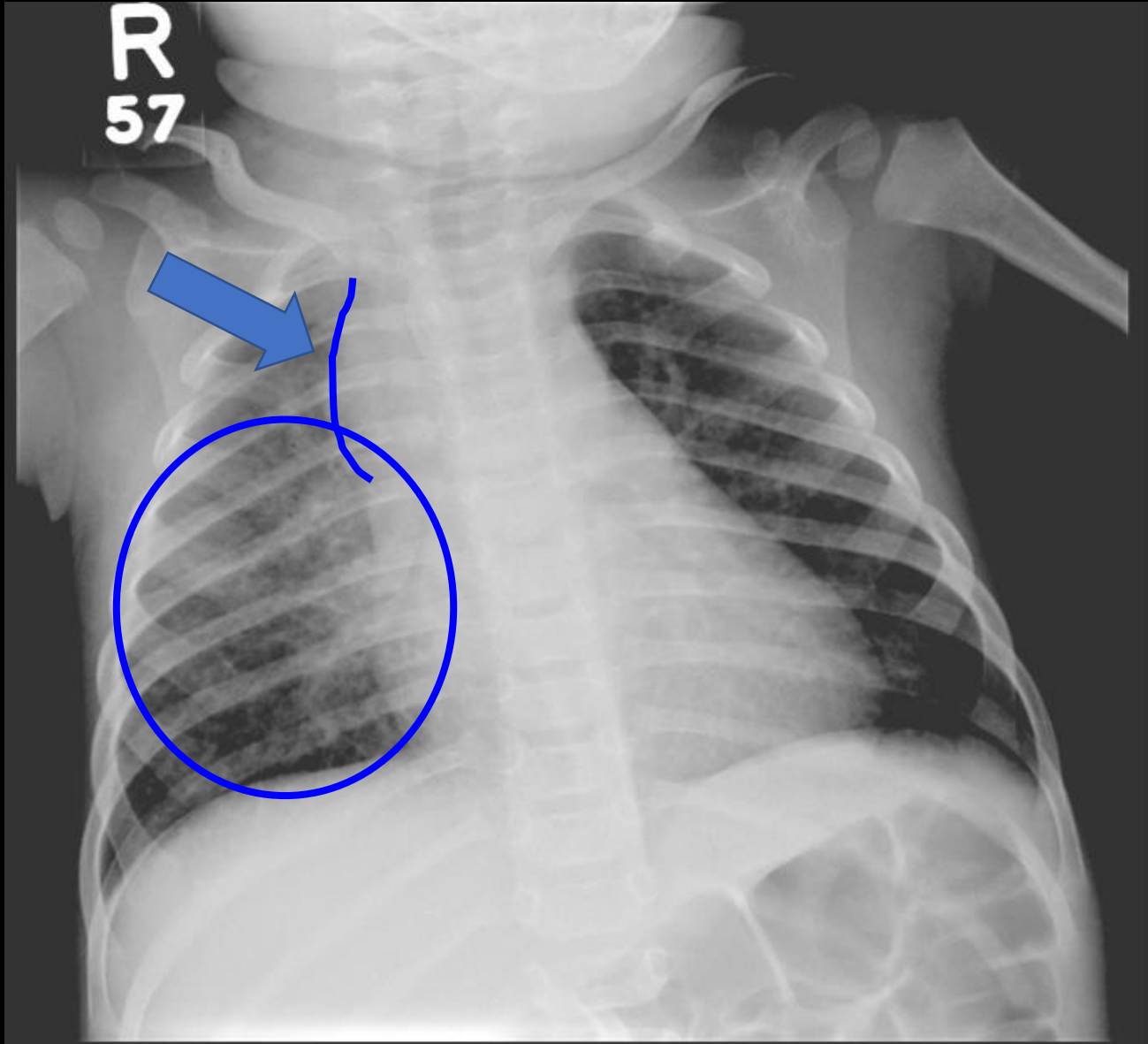


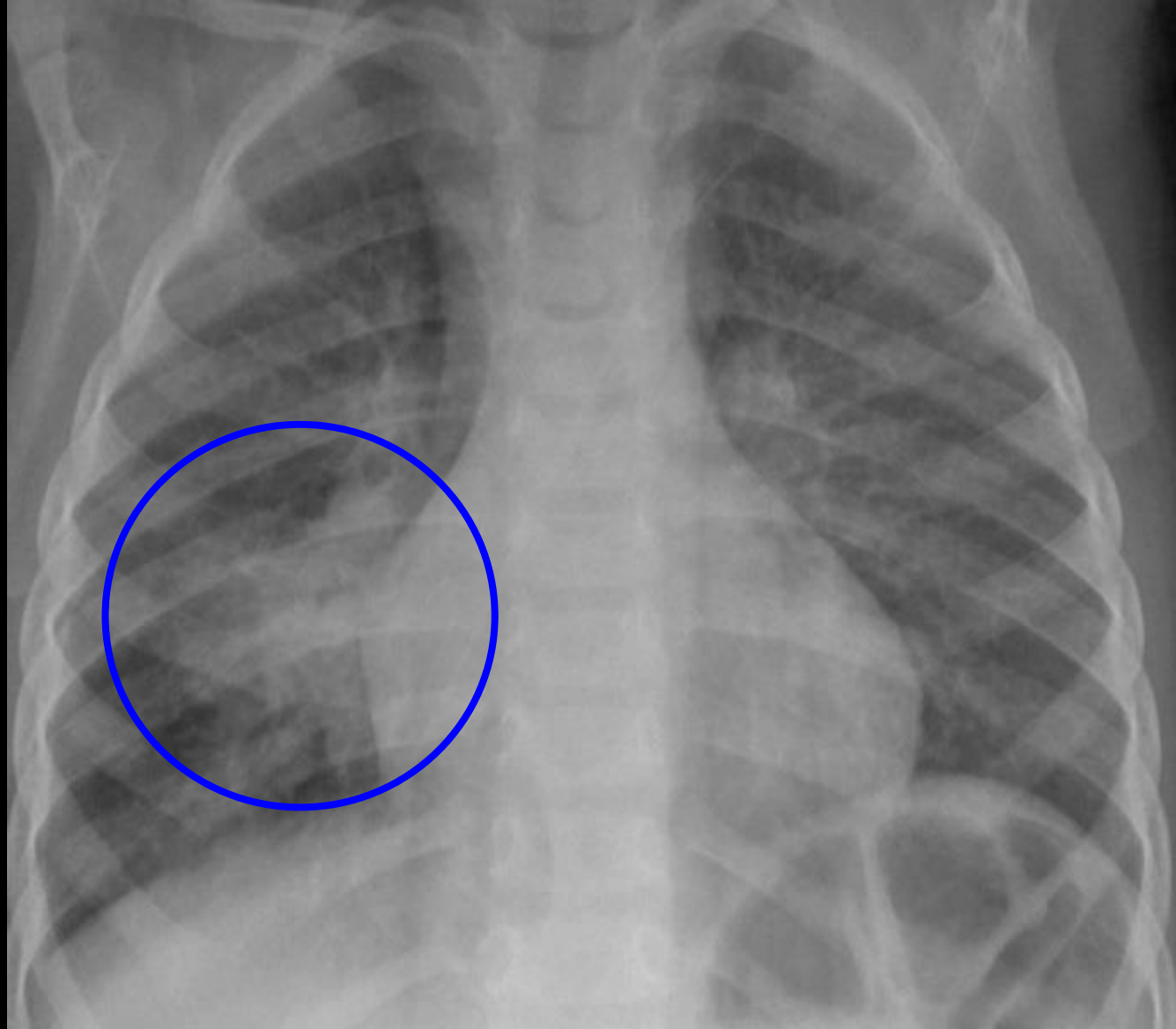
# Primary Tuberculosis

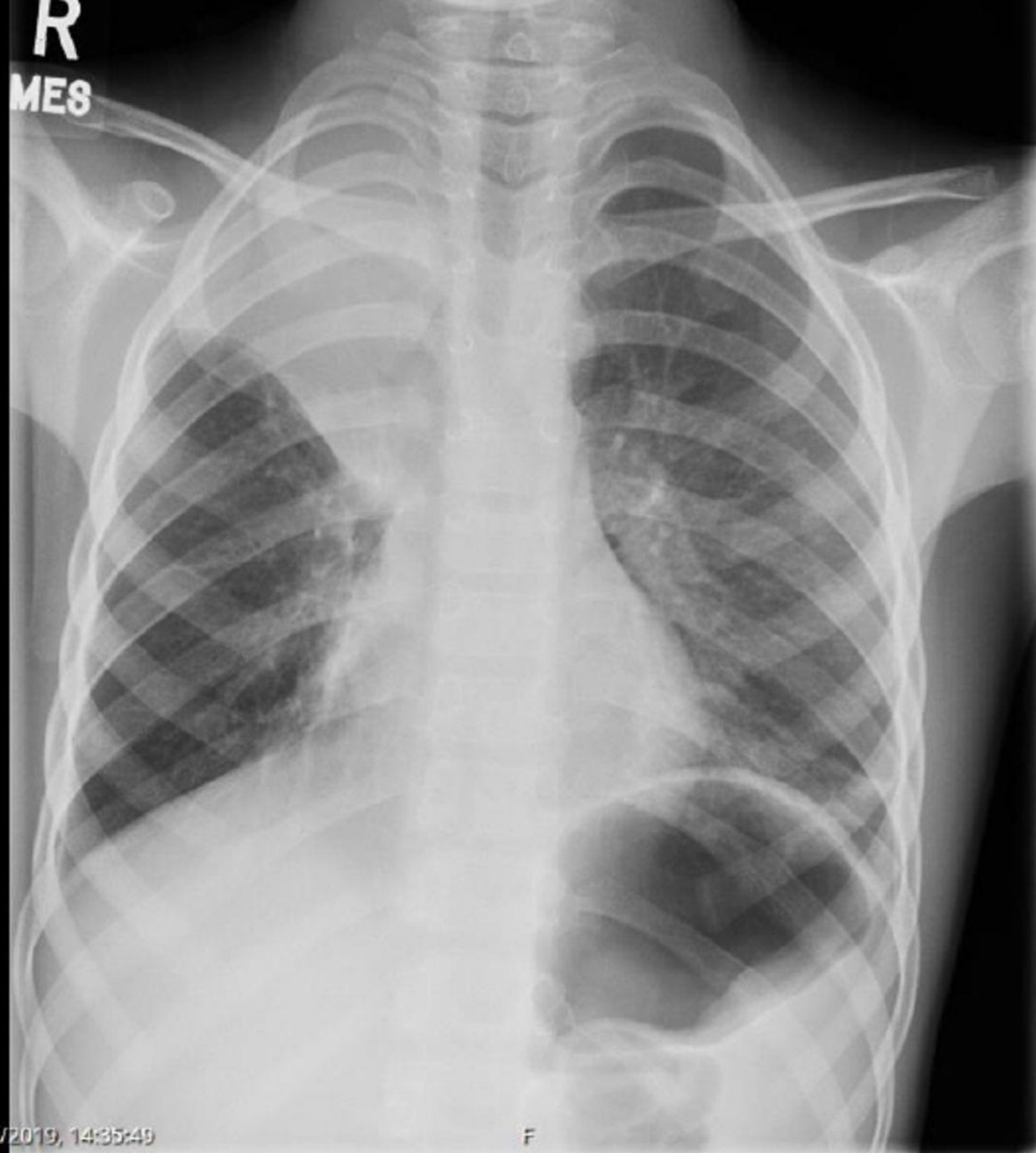
- Most commonly in children and immune compromised patients
- Opacities are seen the in middle and lower lungs; commonly unilateral, bilateral 15%
- Hilar or paratracheal lymphadenopathy with or without infiltrates is characteristic.
- Lymph node enlargement may cause bronchial compression
- Pleural effusion (25% can occur in primary disease)





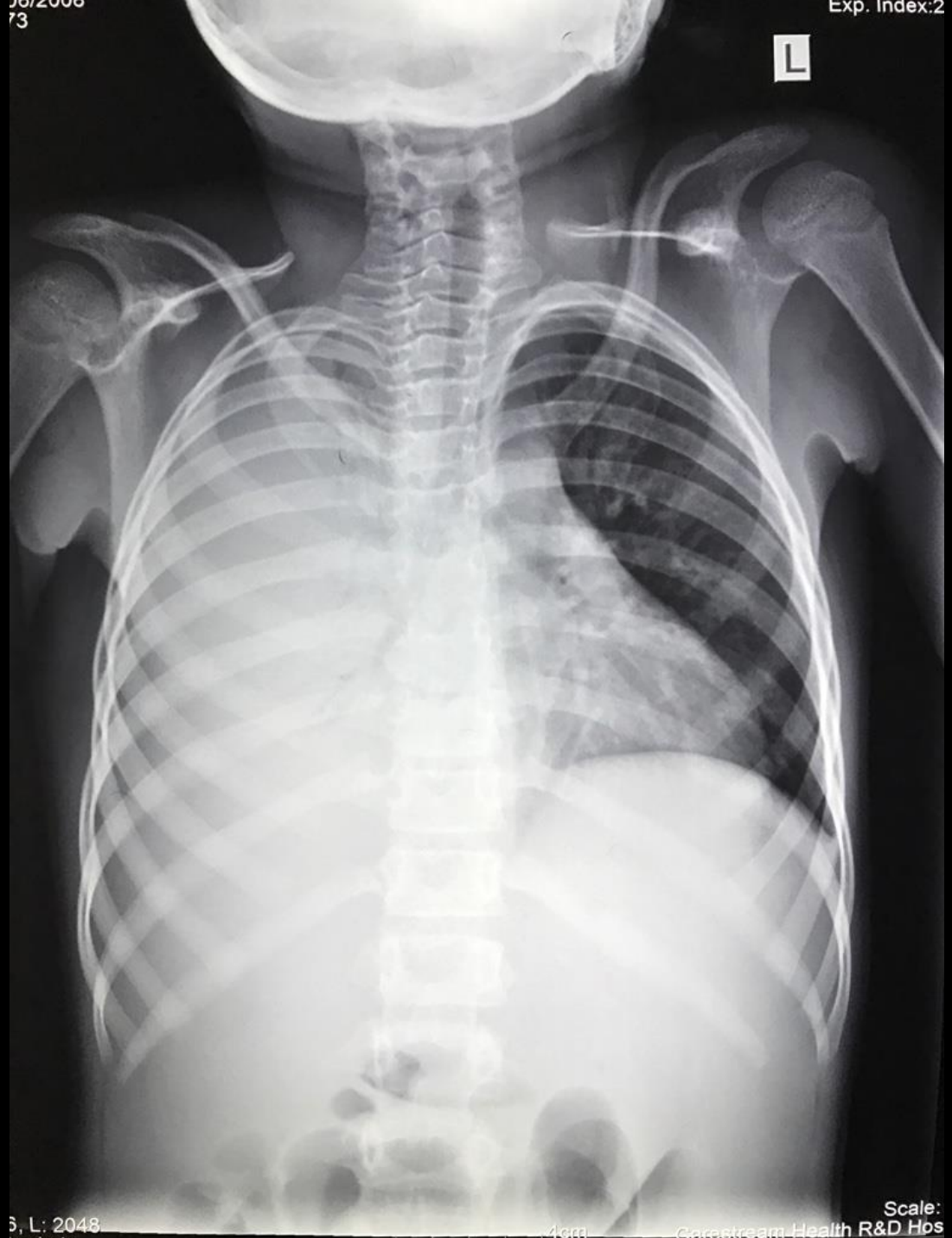





18/08/2019, 14:35:49

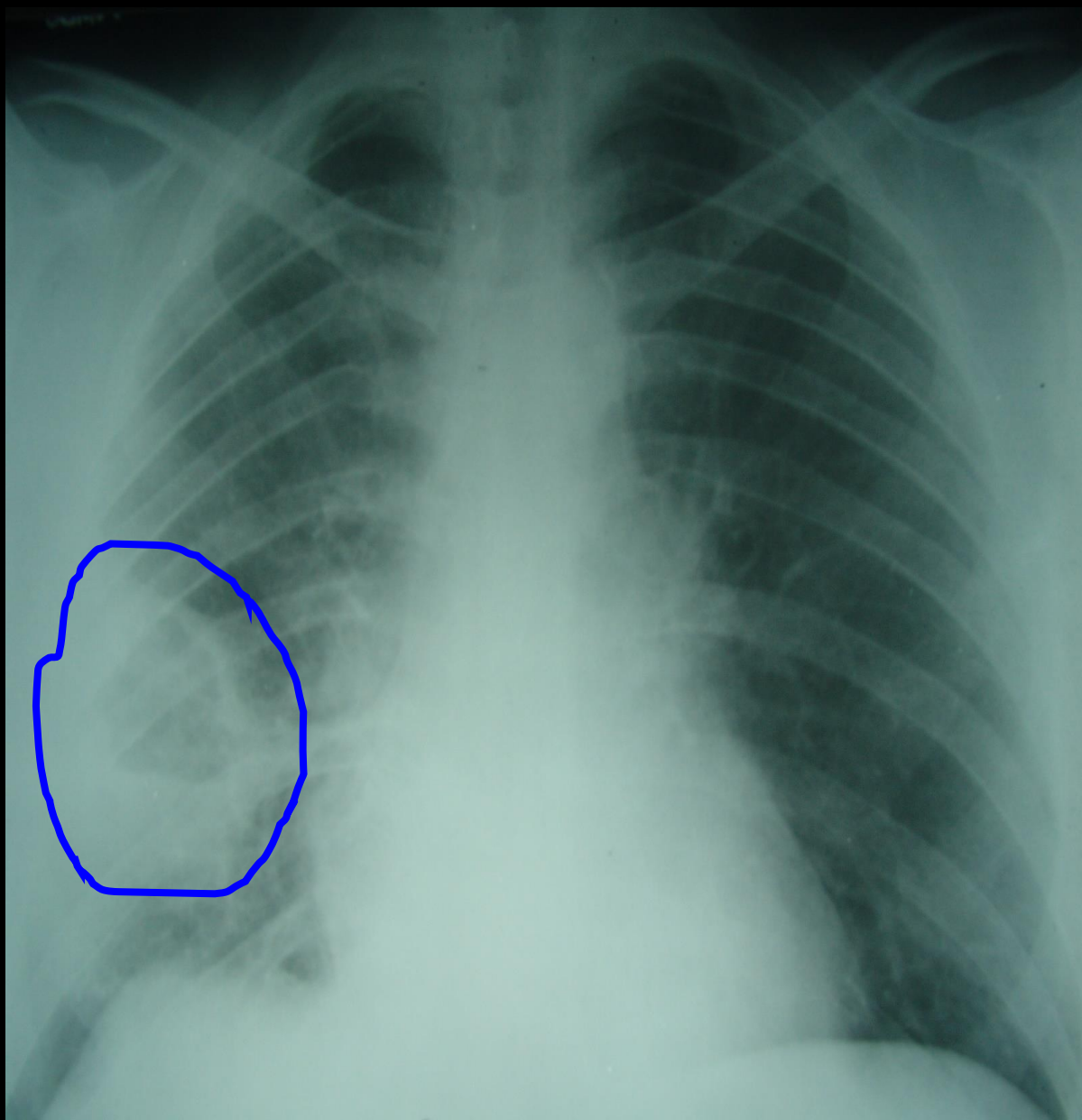
F

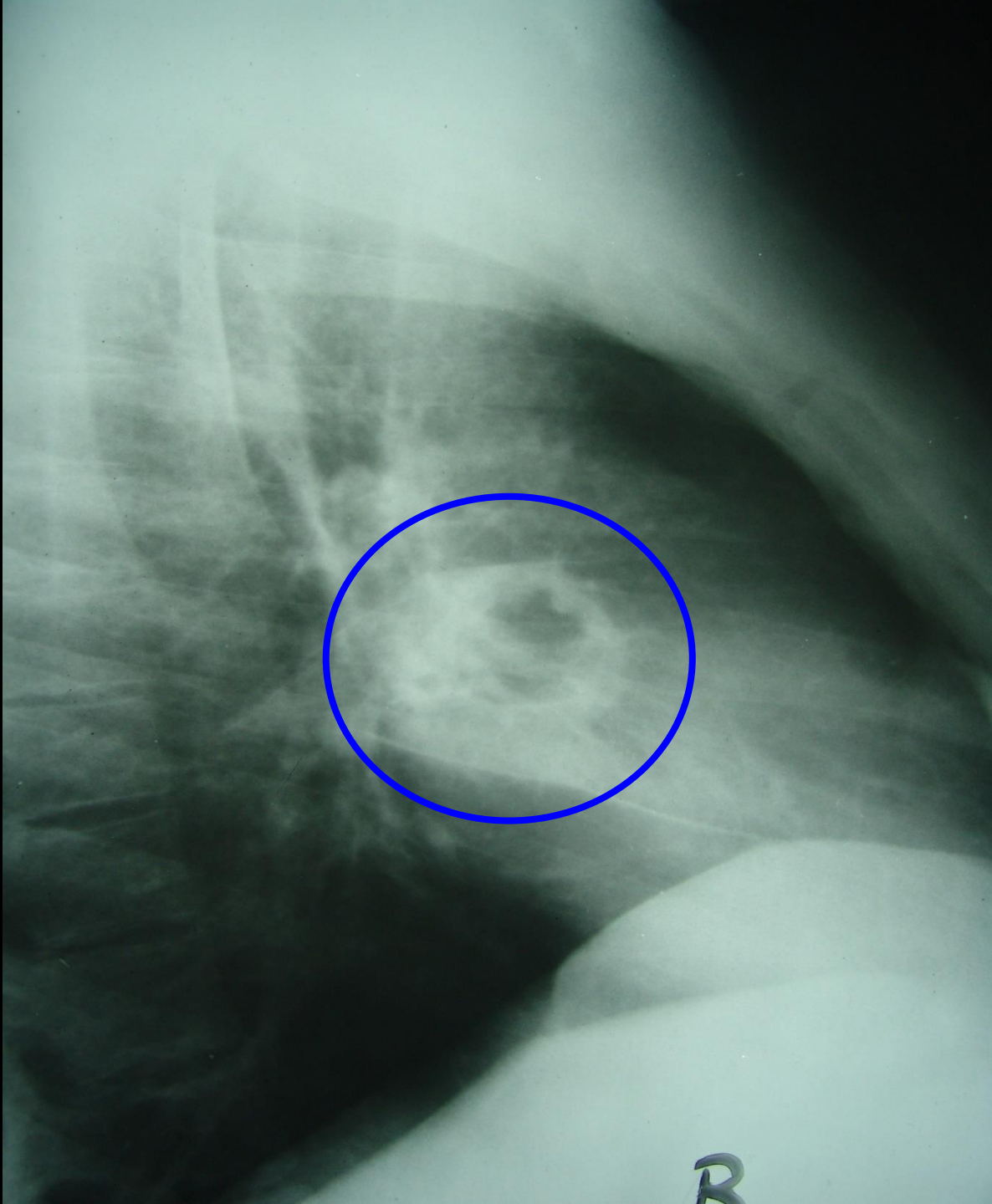


# Post Primary, Reactivation Tuberculosis

- Characterized by upper lobe predilection, cavitation and absence of lymphadenopathy.
- Cavitation is the hallmark; can also see parenchymal disease (consolidation), hematogenous dissemination (miliary), bronchogenic spread (tree-in-bud) and pleural disease.
- Fibrosis and calcification are seen after healing.







# Millet Seeds

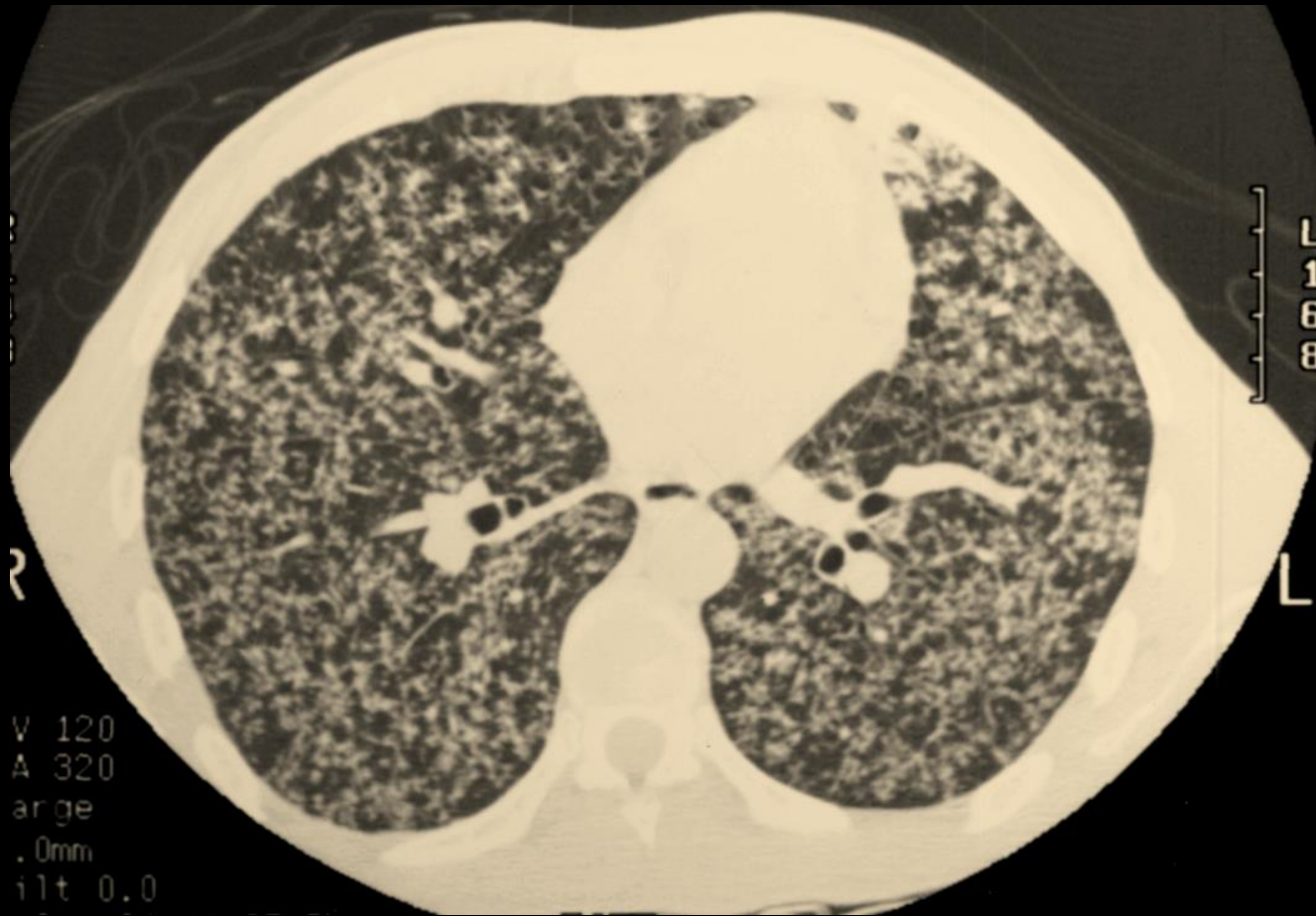Slender plant, 1-  
15 feet

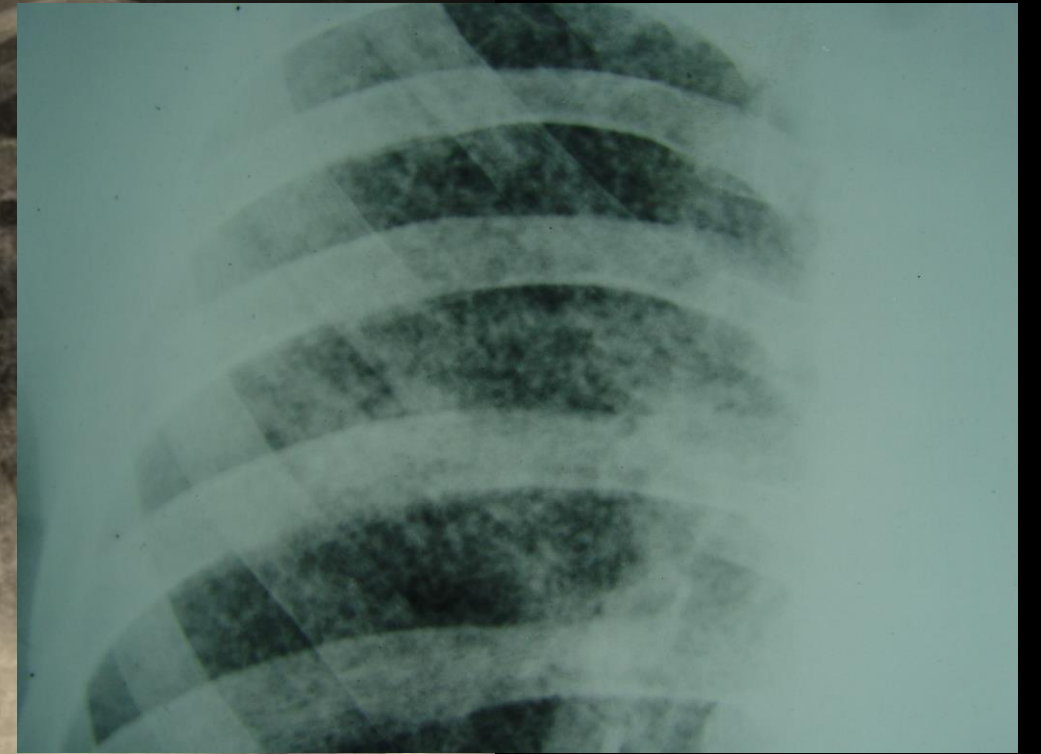
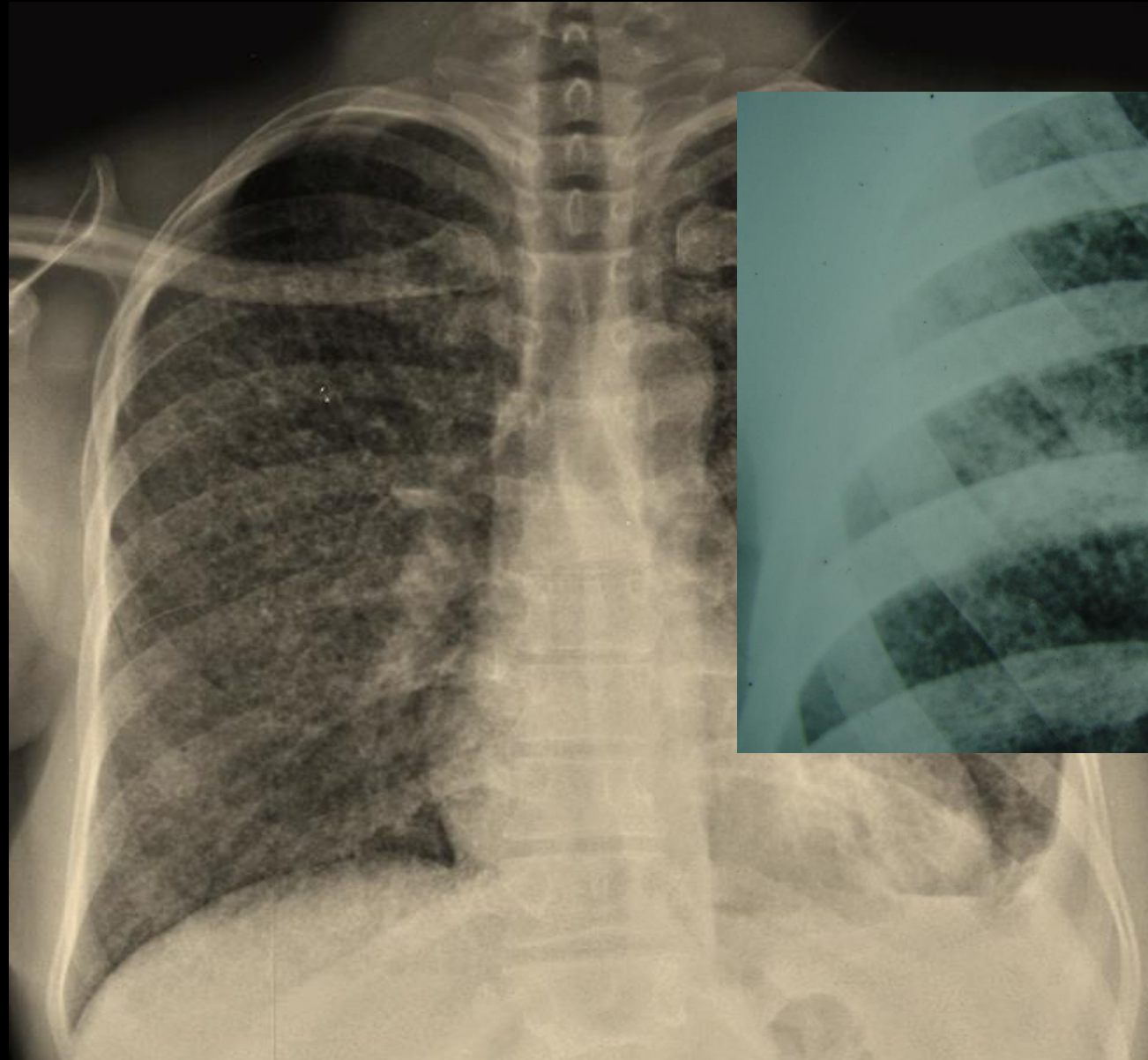
Seeds ~ 2-3 mm  
in diameter

Africa and India



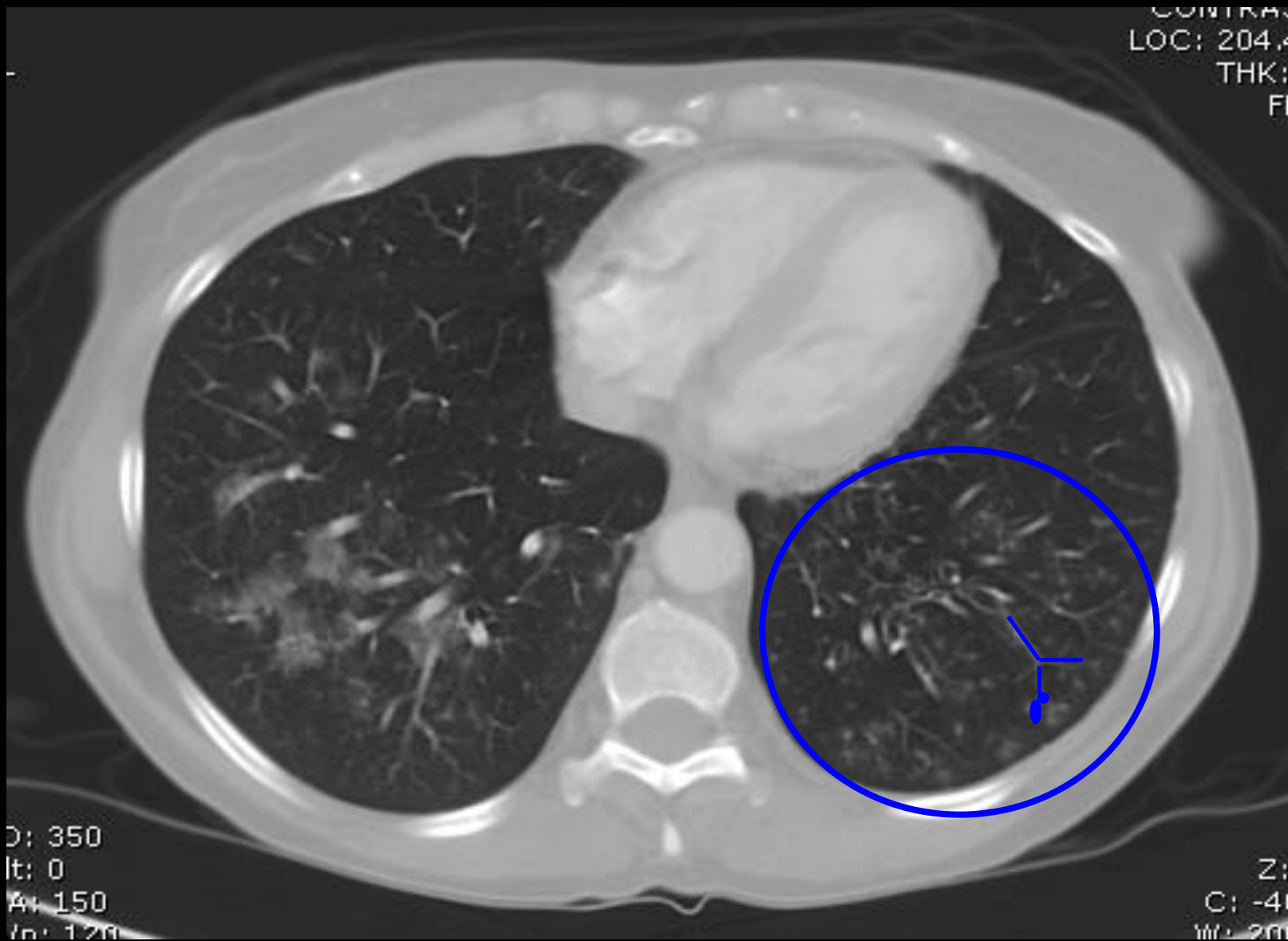
# Milliary TB





# Tree in Bud.....





CONTRAS  
LOC: 204.4  
THK:  
FI

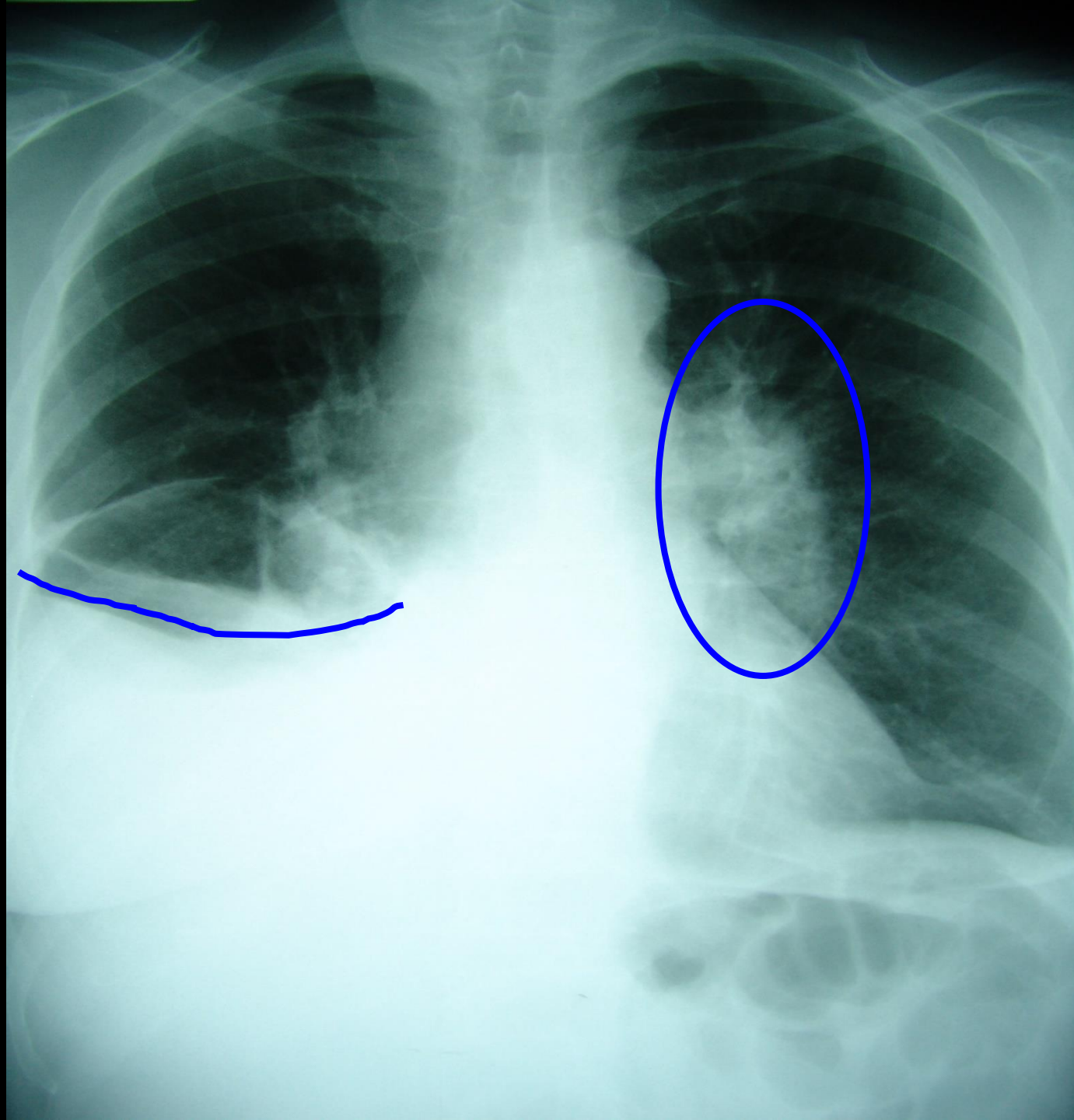
D: 350  
It: 0  
Av: 150  
In: 120

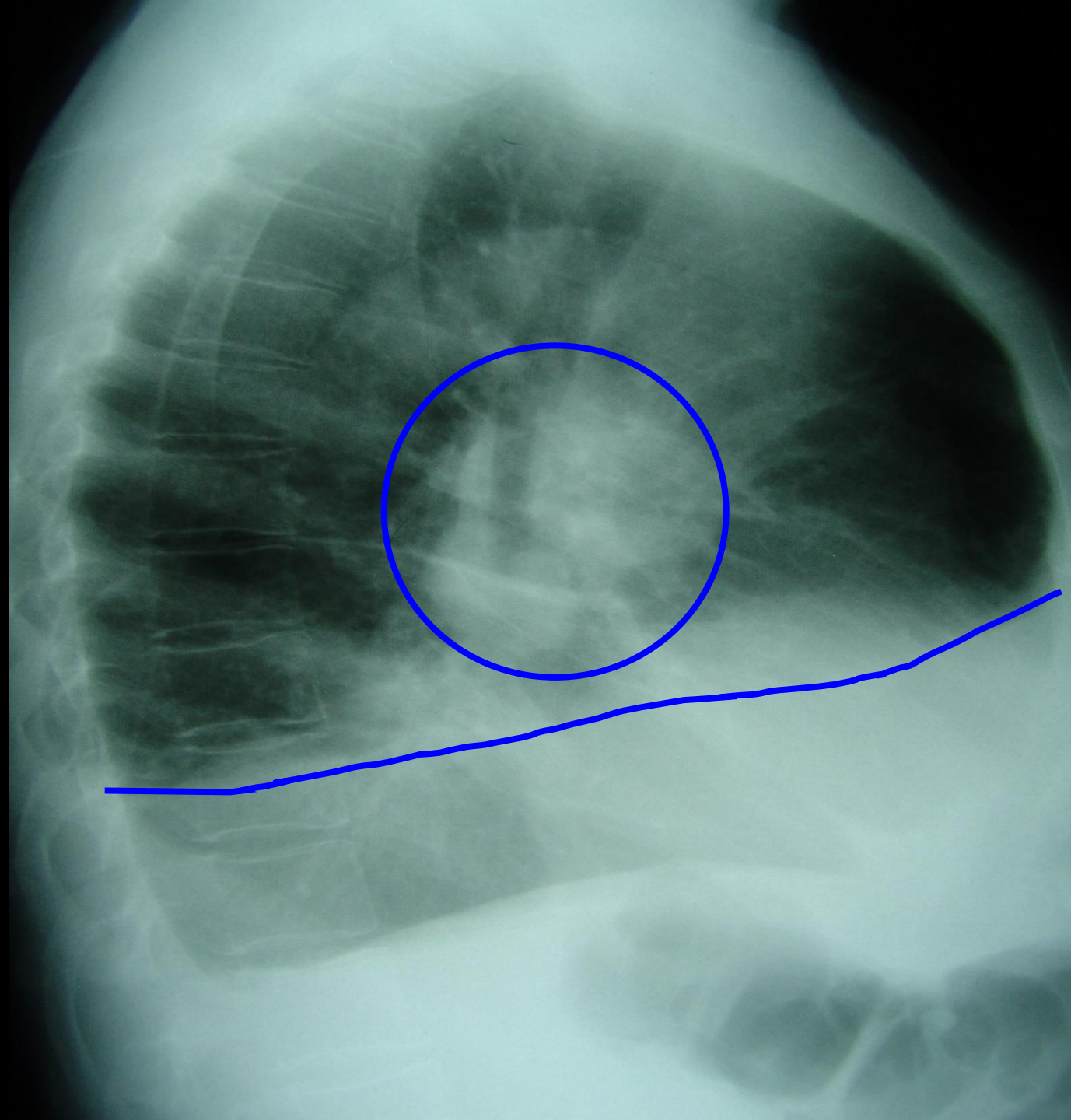
Z:  
C: -41  
W: 200

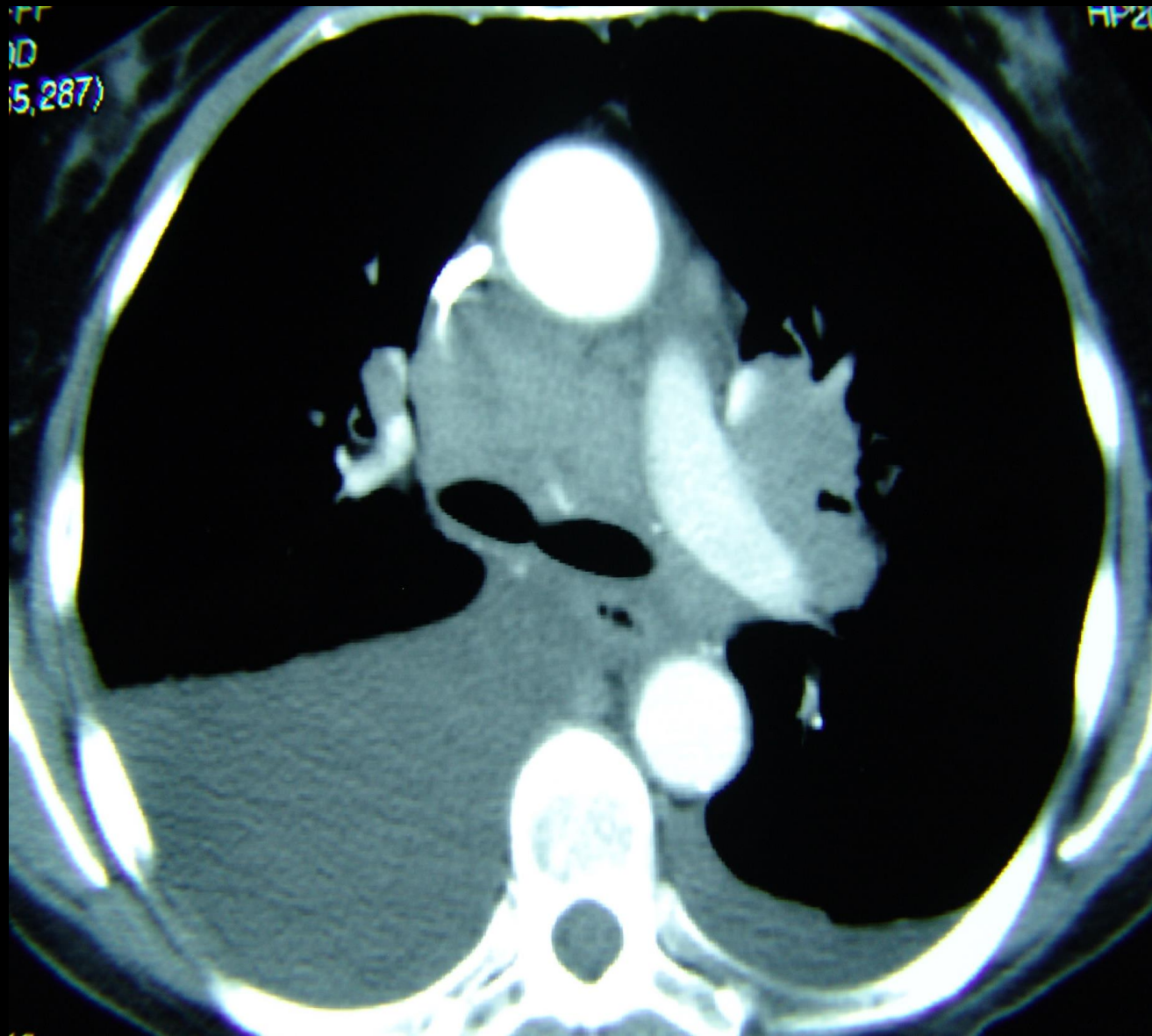
# Pleural Effusions

- Primary TB (25%)
- Hypersensitivity reaction to TB proteins
- Organisms uncommonly isolated from fluid
- May not be associated with obvious parenchymal disease on CXR



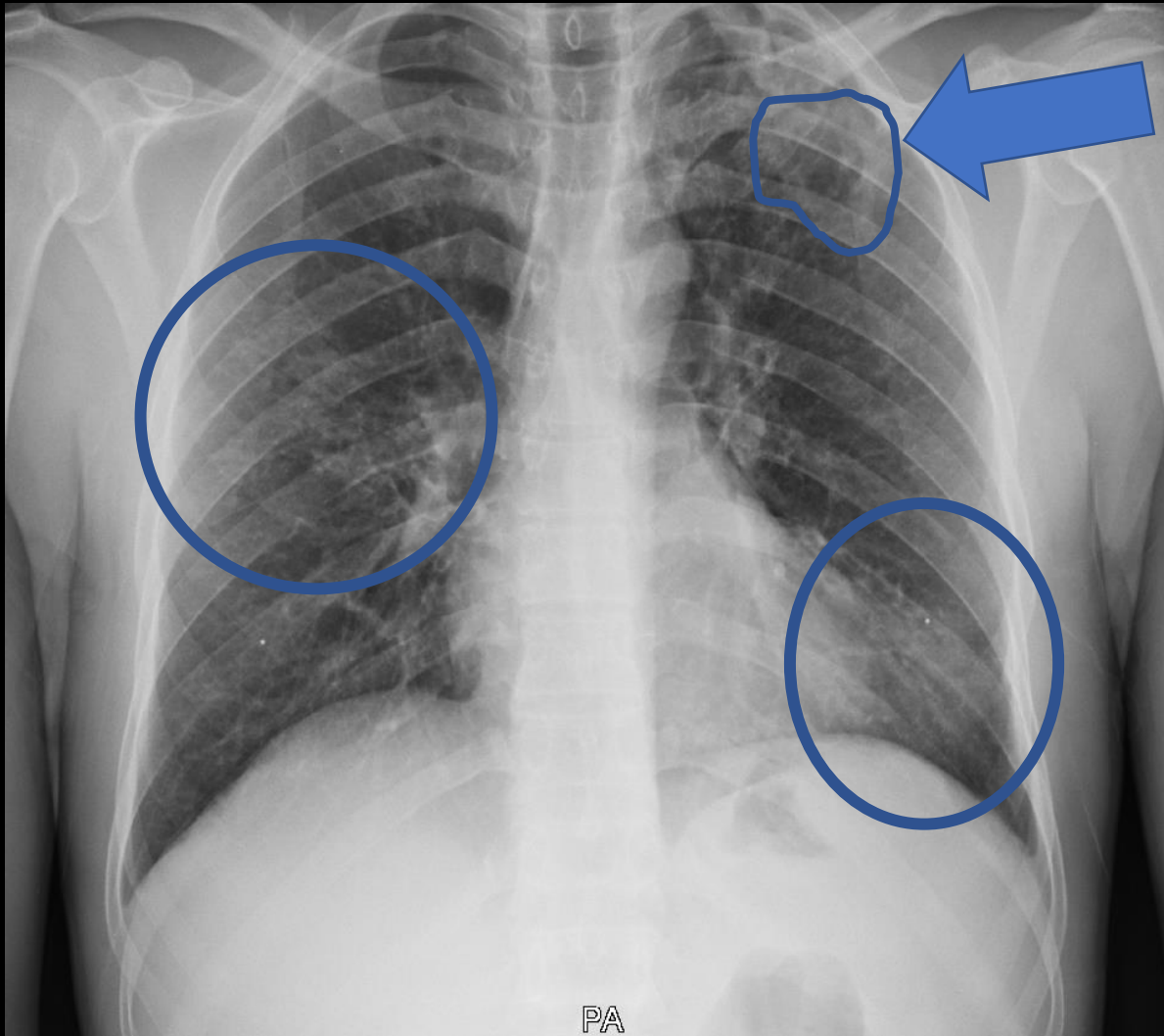






Back to our Eritrean family...




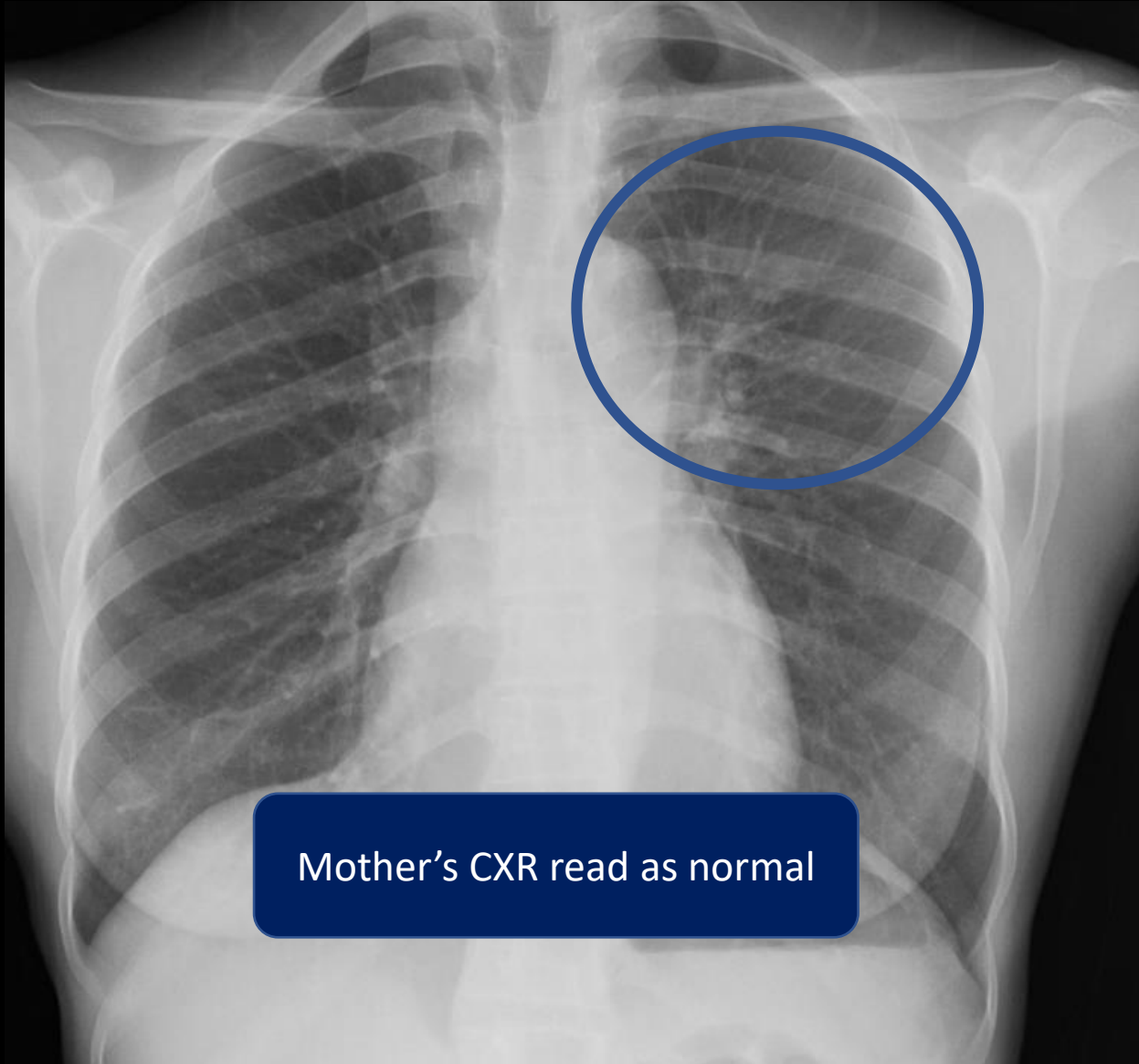


May 2019

37 year old African man  
4 months of cough, weight  
loss, and poor energy

Chest xray is one piece of the TB puzzle





Mother's CXR read as normal

Sputum AFB smear and PCR +,  
culture + MTB

# Chest Radiology in TB

- Interpretation of a chest radiograph is pattern recognition that requires clinical correlation for true diagnosis



# Thank you

Heartland National TB Center

