



Importance of a TB Medical Assessment

Barbara J Seaworth, MD

Co-Medical Director, Heartland National TB Center of Excellence

Professor, Internal Medicine and Infectious Disease

UT Health Northeast

Clinician, San Antonio Metro Health TB Clinic

Think TB

TREATMENT IS PREVENTION – WE DO NOT HAVE
AN EFFECTIVE VACCINE – YET

TREATMENT STOPS TRANSMISSION

YOU HAVE TO FIND THEM TO TREAT THEM!





Latent TB Infection (LTBI)

- Persons are **infected** with *Mycobacterium tuberculosis* but:
 - No Active TB Symptoms
 - Chest X-ray may be normal, or show small granuloma, **stable** pleural or parenchymal scarring
 - Positive TST (Tuberculin Skin Test) or IGRA (Blood Test)
 - Not infectious – Do not transmit TB

Active TB Disease

- Persons are **sick** and usually have at least one of the below
 - Abnormal CXR
 - Symptoms and or findings c/w TB disease
 - Specimen which is pcr positive or grows MTB
- Usually are infectious

LATENT TB INFECTION

- We used to think the bacteria were in a complete resting state or dormant but
 - TB Bacteria **are metabolically active and dividing**, but infection is controlled by the immune system.
- **Current methods of LTBI diagnosis are less than perfect**
- Active TB Disease may develop if immunity wanes.



The Spectrum of Activity of MTB – One Could Think of Popcorn



Persons at Risk of (**Exposure**) MTB Infection or Disease

- People who have spent time with someone who has TB disease
- People from a country where TB disease is common:
 - most countries in Latin America, the Caribbean, Africa, Asia Eastern Europe, and Russia
 - especially now consider Afghanistan, Iraq, Ukraine
- People who **live or work** in high-risk settings:
 - correctional facilities, long-term care facilities or nursing homes, and homeless shelters
- Health-care workers who care for patients at increased risk for TB disease
- Infants, children and adolescents exposed to adults who are at increased risk for latent tuberculosis infection or TB disease



Persons at Risk of **Progression** from Latent TB Infection to Active TB Disease

- HIV infection
- Chronic kidney disease
- Silicosis
- **Recent exposure**
- Diabetes
- Chest x-ray abnormality c/w previous inadequately treated TB
- Intravenous drug use
- Smoking – active and passive
- Underweight by >10% (*Maybe*)



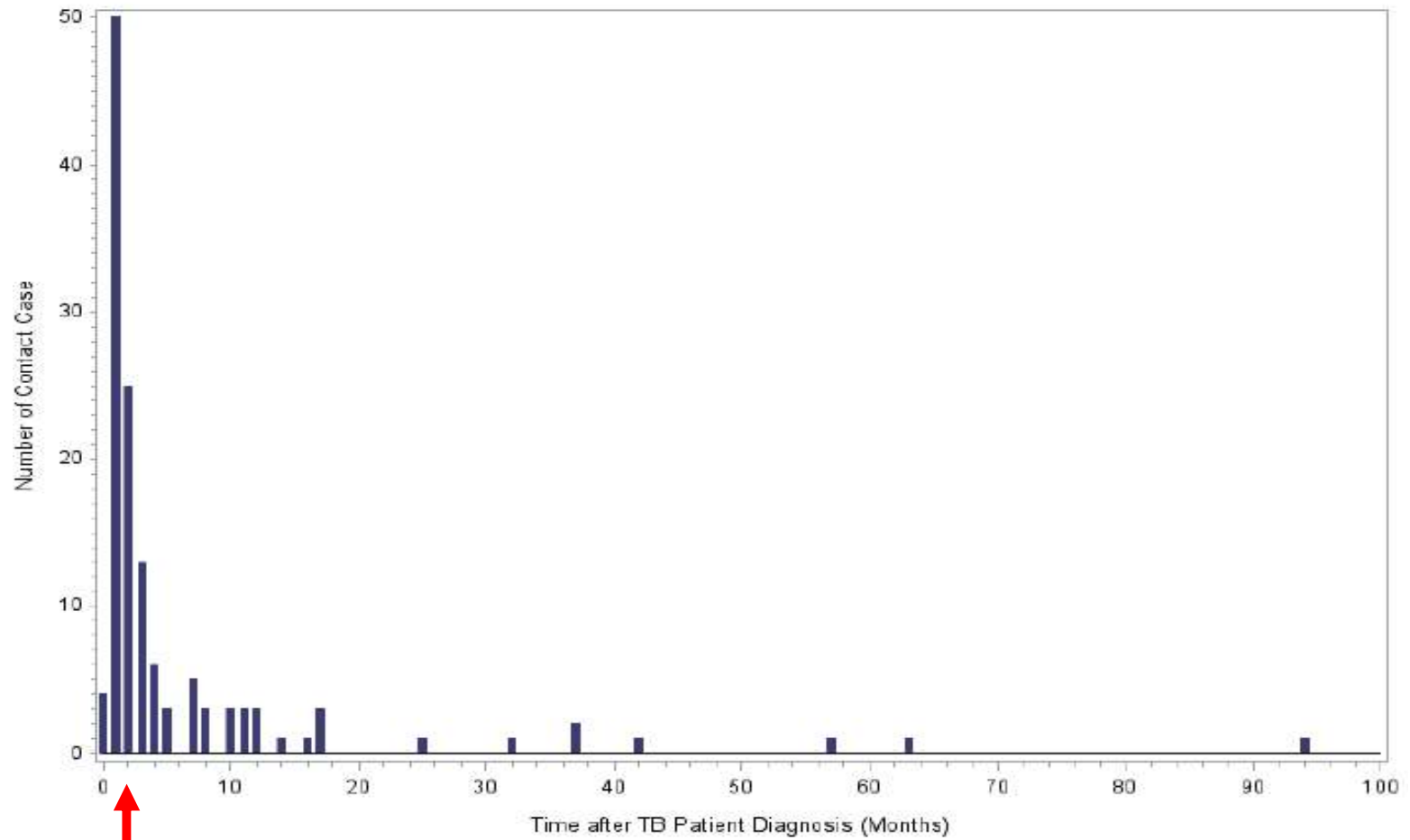
Persons at Risk of **Progression** from Latent TB Infection to Active TB Disease

- Immunosuppression

- Pregnancy and first three months post partum
- Organ transplant recipients
- Hematologic cancers and head and neck cancers
- Medications
 - TNF α inhibitors
 - Prednisone >15 mg, > 4 weeks
 - Chemotherapy
 - Other immunosuppressive drugs



Figure 1. Timing of Tuberculosis Diagnosis among 131 Contacts Diagnosed after the Index Case Diagnosis



2 months

JID
June 2018

Evaluation for TB

- In U.S. usually starts with a screening test to detect evidence of TB infection –
 - **Only after the provider considers the Possibility of TB**
 - TB Skin Test (TST)
 - Interferon Gamma Release Assays (IGRA)



Treating TB Infection

Wait –
Are We
There Yet?



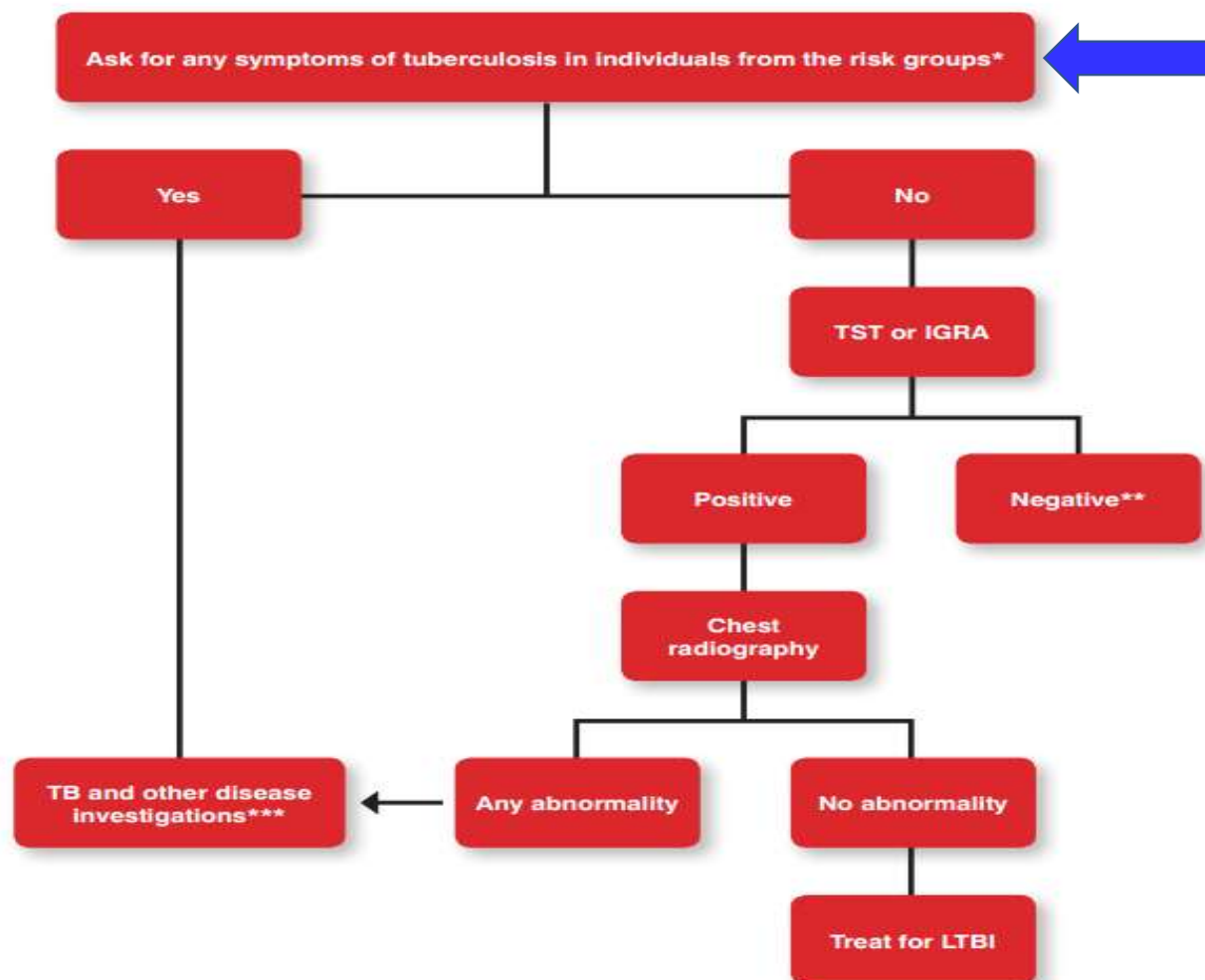
“NO!”



WHO Guidelines on the management of latent tuberculosis infection 2015

Remember that the TST or IGRA may be negative in those with active TB!

Figure 1. Algorithm for targeted diagnosis and treatment of LTBI in individuals from risk groups



* Any symptoms of TB include any one of: cough, haemoptysis, fever, night sweats, weight loss, chest pain.

Active TB Disease or TB Infection? The Clinical Evaluation

The single most important thing prior to starting treatment for TB Infection is to exclude active TB disease.

If in doubt – wait!

Evaluate for TB disease

Consider consultation with TB expert



Evaluate to Exclude Active TB Disease

- If the TST or IGRA is Positive –
 - » **OR**
- Child < 5 or immunocompromised person with recent exposure or patient has symptoms –
 - even if TST/IGRA negative -**
 - ✓ History
 - ✓ Physical examination
 - ✓ Chest X-Ray



How Can TB be “Ruled Out?”



Is There Evidence of Disease?

- Symptoms*

- Fever
- Chills
- Night Sweats
- Weight Loss
- Cough (dry/productive)
- Hemoptysis
- Fatigue

*** only one may be present – or patient may deny all**

Is Patient at Risk of Progression to Disease?

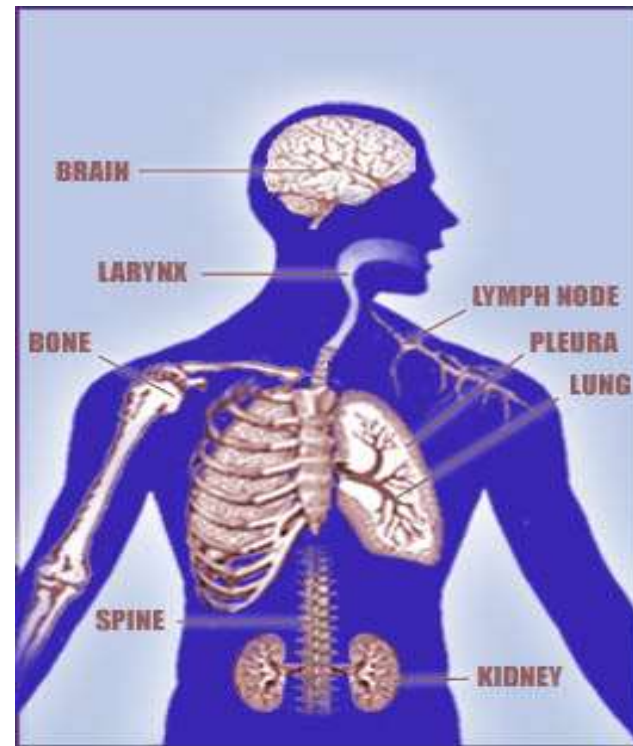
- Medical History:

- HIV
- Silicosis
- Chronic Kidney Disease
- Diabetes
- Immunosuppression
- Drug/alcohol/tobacco
- TB exposure



TB Exam – Focus on Possible Sites of TB Disease

- Lungs – Pulmonary
- Extrapulmonary
 - Larynx
 - Lymph nodes (cervical, inguinal, supraclavicular, mediastinal, abdominal)
 - Pleural effusion
 - Genitourinary
 - Bones & joints
 - Miliary (disseminated)



Physical Exam

- General assessment – does person look well?
- Lung exam
- Check for lymph nodes
- Palpate liver
- *In children* look at growth curve/weight/activity
- Look for anything that will complicate therapy!
- Laboratory abnormalities c/w active TB
 - Elevated platelet count, low serum albumin, anemia



Radiologic Exam

- CXR must be done **before treatment of TB Infection**
 - Must be read as normal
- Or
- IF abnormal:
 - Not consistent with Active TB
 - Stable abnormality confirmed over a 3 - month period



CXR - Can Suggest TB Disease but Does Not Definitely **Diagnose or Exclude** TB Disease

Cavitary lesions

Upper lobe infiltrates

Pleural effusion especially in those with recent exposure

“Tree in bud” findings on CT exam

Common mimics of TB =

- Non-tuberculous mycobacteria (NTM)
- fungal infection
- bacterial abscesses
- necrotic neoplasm (especially lung neoplasm)



Usually thin walled cavities

May be Normal!



CXR – Old Healed TB

- Nodules & fibrotic lesions may contain slowly multiplying bacilli; these persons have a higher risk for progression to active TB disease

Caution: I usually have several patients in the San Antonio TB Clinic with positive cultures for TB and a CXR report that says c/w old healed TB.

If the CXR is “stable” for 2 – 3 months this is an indication that abnormality represents latent TB infection

If the CXR shows calcified nodular lesions (calcified granuloma) there is a very low risk for progression to TB disease



Bacteriologic and Histologic Examinations

When lung or larynx is site of disease and for **every** patient with extrapulmonary TB:

- **3** sputum specimens for AFB smear and culture
Ask for a pcr (GeneXpert) on initial specimen if you suspect TB disease
- Collected 8-24 hours apart
with at least 1 early morning specimen
one induced specimen
one observed specimen



Specimens should be obtained in an isolated, well-ventilated area or sputum collection booth

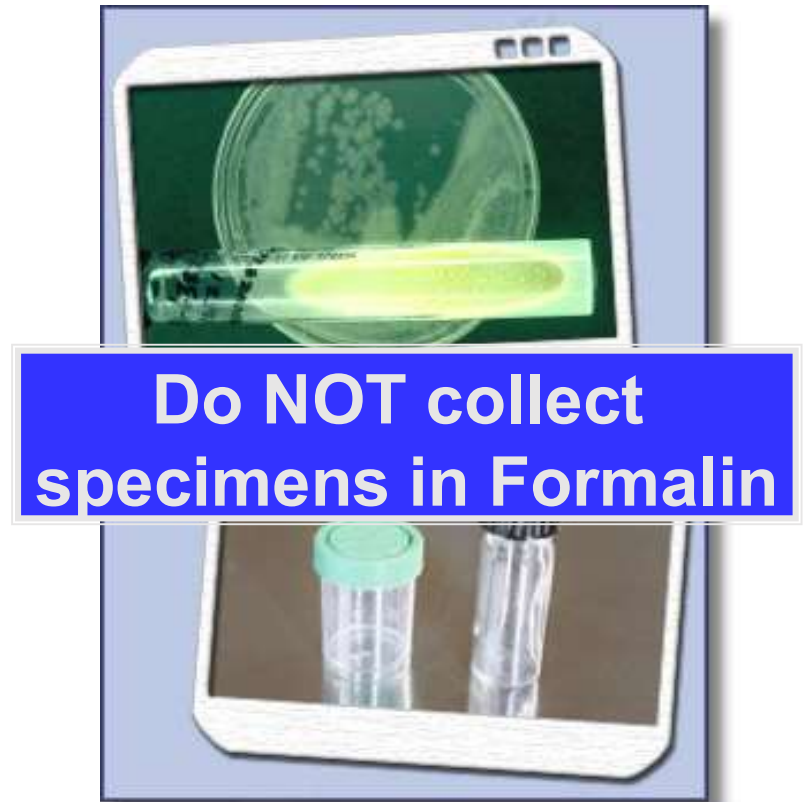

Bacteriologic and Histologic Examinations

Extrapulmonary Specimens

- Urine
- Cerebrospinal fluid *
- Pleural fluid *
- Ascites *
- Pus
- Biopsy specimens

*recovery poor

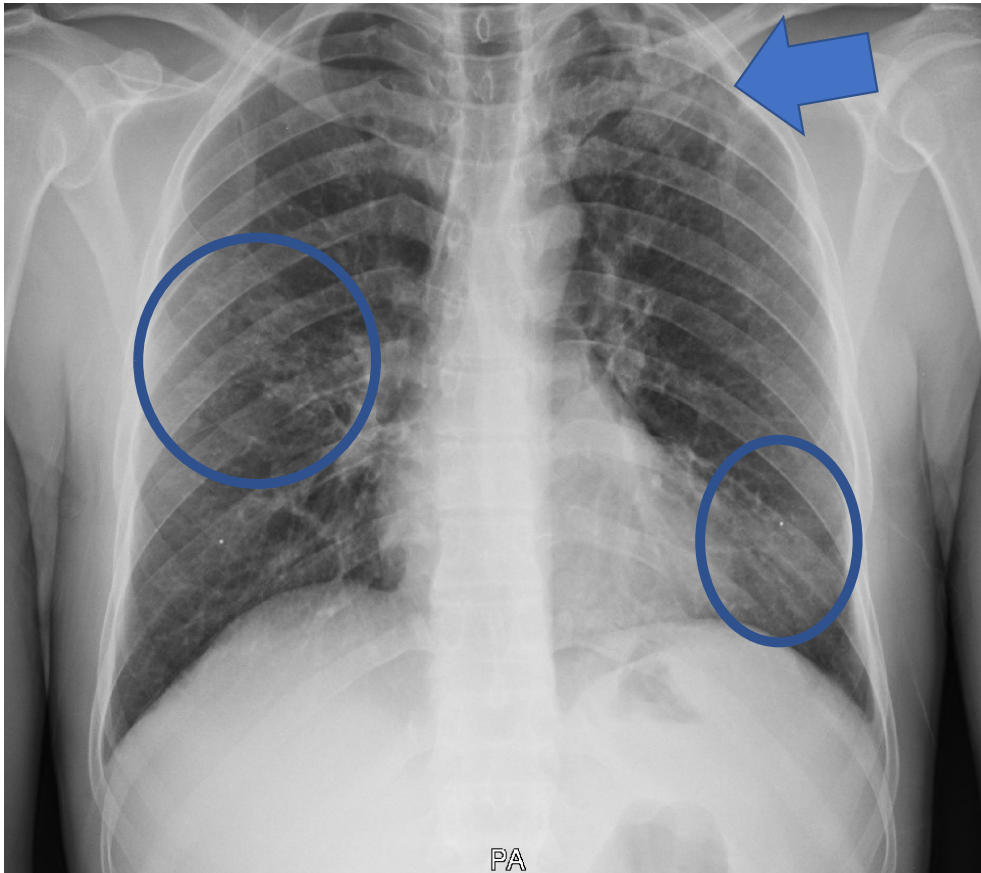


Case Study - Immigrant Evaluation For TB Spring 2018

- 13-year-old immigrated from Northeastern African country within last year
- Thin but otherwise well
- Positive T-Spot
- Normal CXR

Latent TB Infection





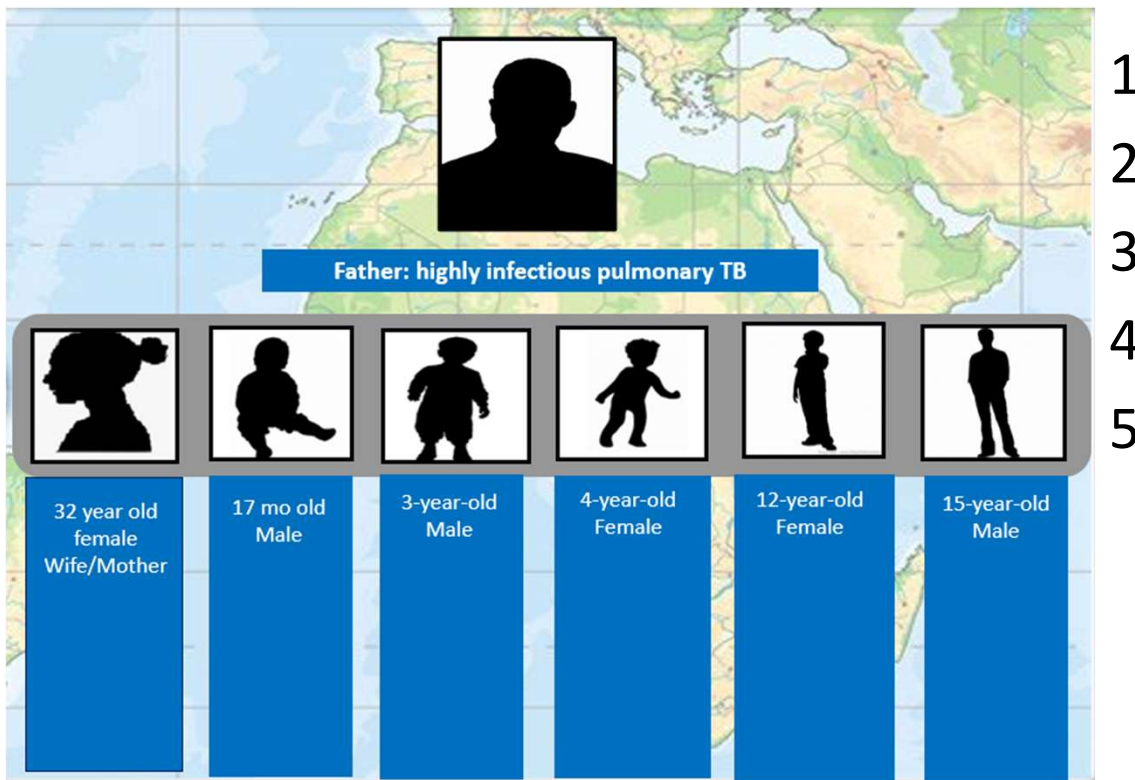
May 2019

37 year old African man
4 months of cough, weight
loss, and poor energy
6 weeks after starting TB
treatment remains strongly
AFB smear positive

AFB – Acid Fast Bacilli

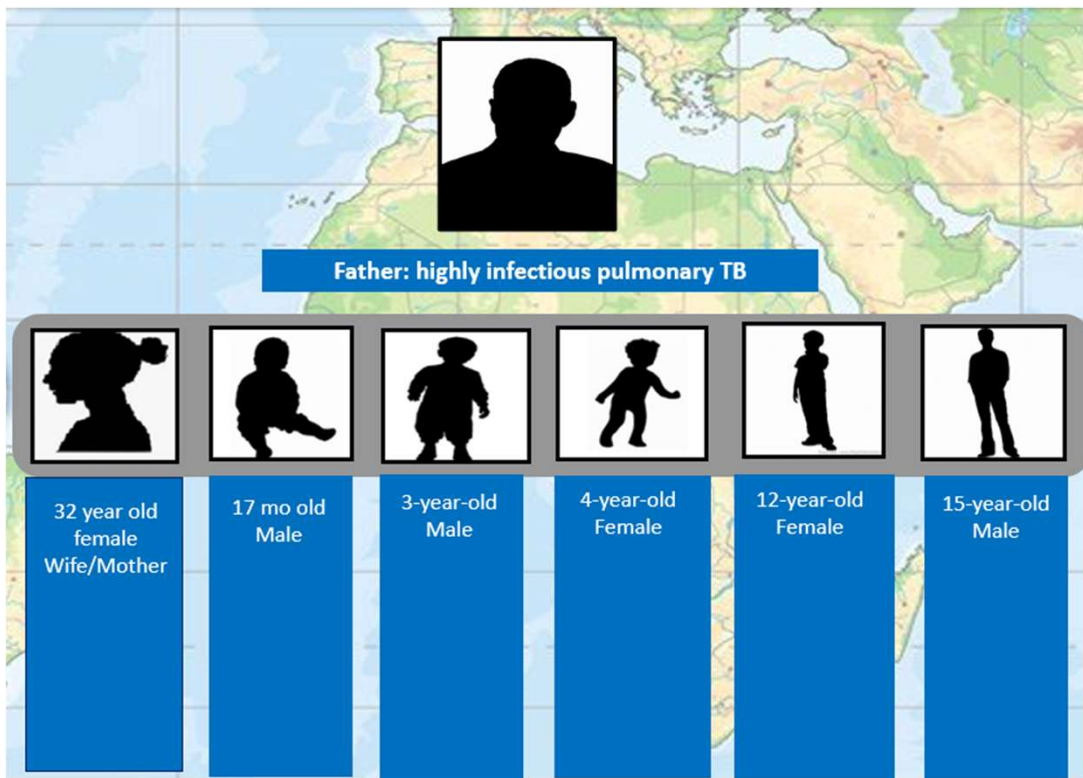
ACTIVE TB DISEASE

Family of Newly Diagnosed Patient Comes to Clinic – What Now?



Public Health's responsibility is to:
Find and treat disease if it is there
Find and treat LTBI if it is there
Protect the vulnerable contacts even if all tests are negative

Family of Newly Diagnosed Patient Comes to Clinic – What Now?

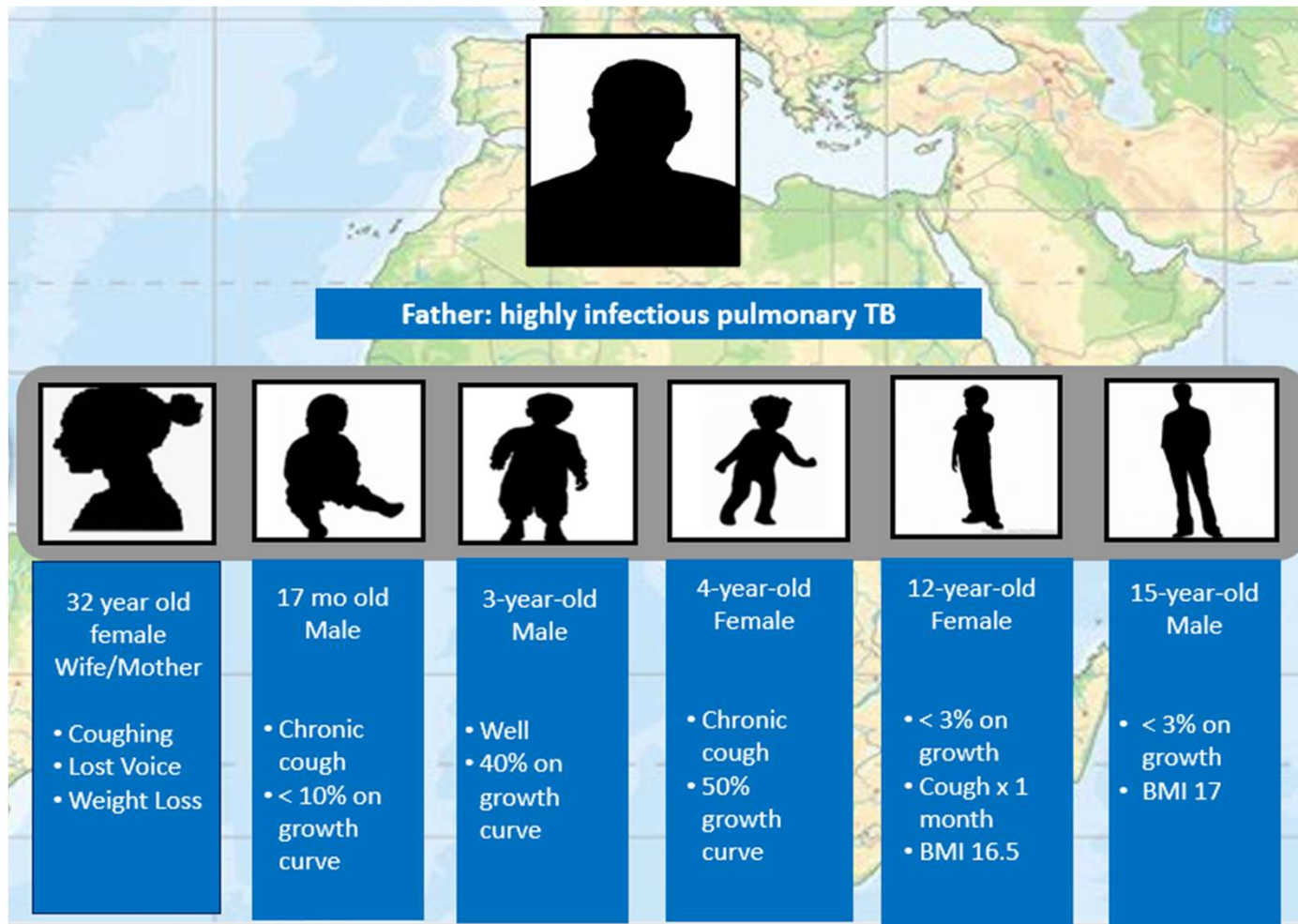


- 1 IGRA-except 17-month-old
 - BCG vaccinated
 - TST for children <2
- 2 Evaluate for symptoms of TB; generally, do they look well? Kids playful? Alert?
- 3 Medical Assessment
 - Weight, BMI, Growth curve for kids
 - Targeted exam – lungs, lymph nodes
- 4 CXR
- 5 Sputum if any signs or symptoms

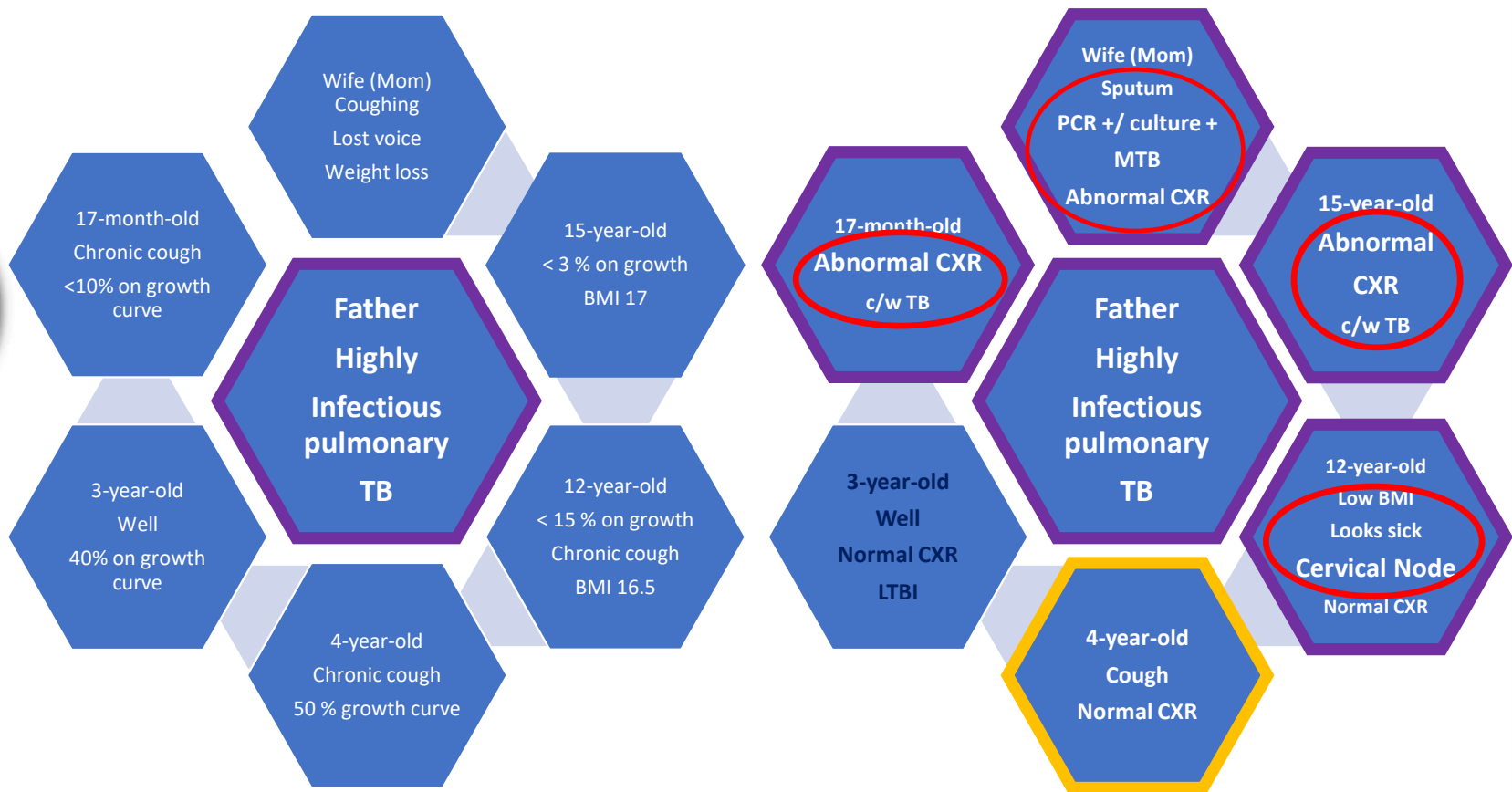
Public Health's responsibility is to:
Find and treat disease if it is there
Find and treat LTBI if it is there
Protect the vulnerable contacts even if all tests are negative

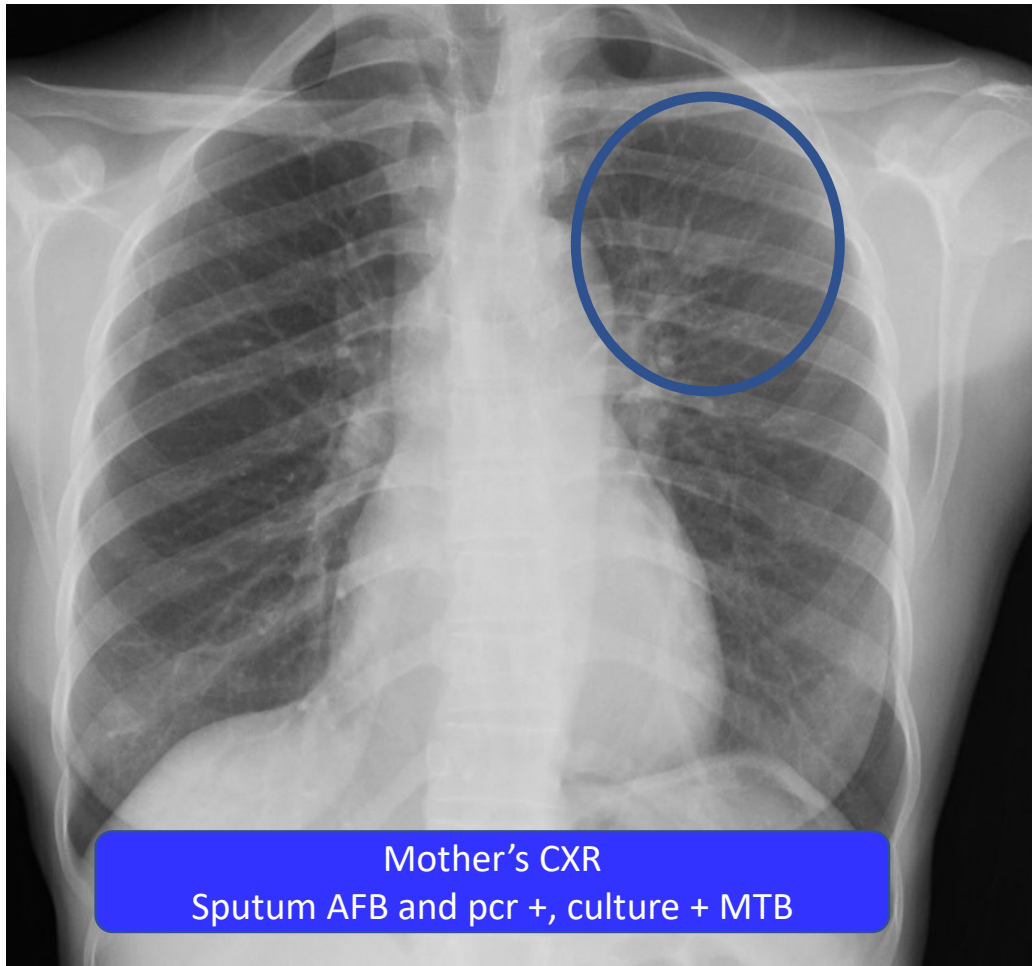
2019 Contact Investigation in Family

Epidemiology is Critical Information



2019 Contact Investigation in Family
All IGRA positive except 17-month-old - 20 mm blistering TST





Mother's CXR
Sputum AFB and pcr +, culture + MTB

CXR read as normal

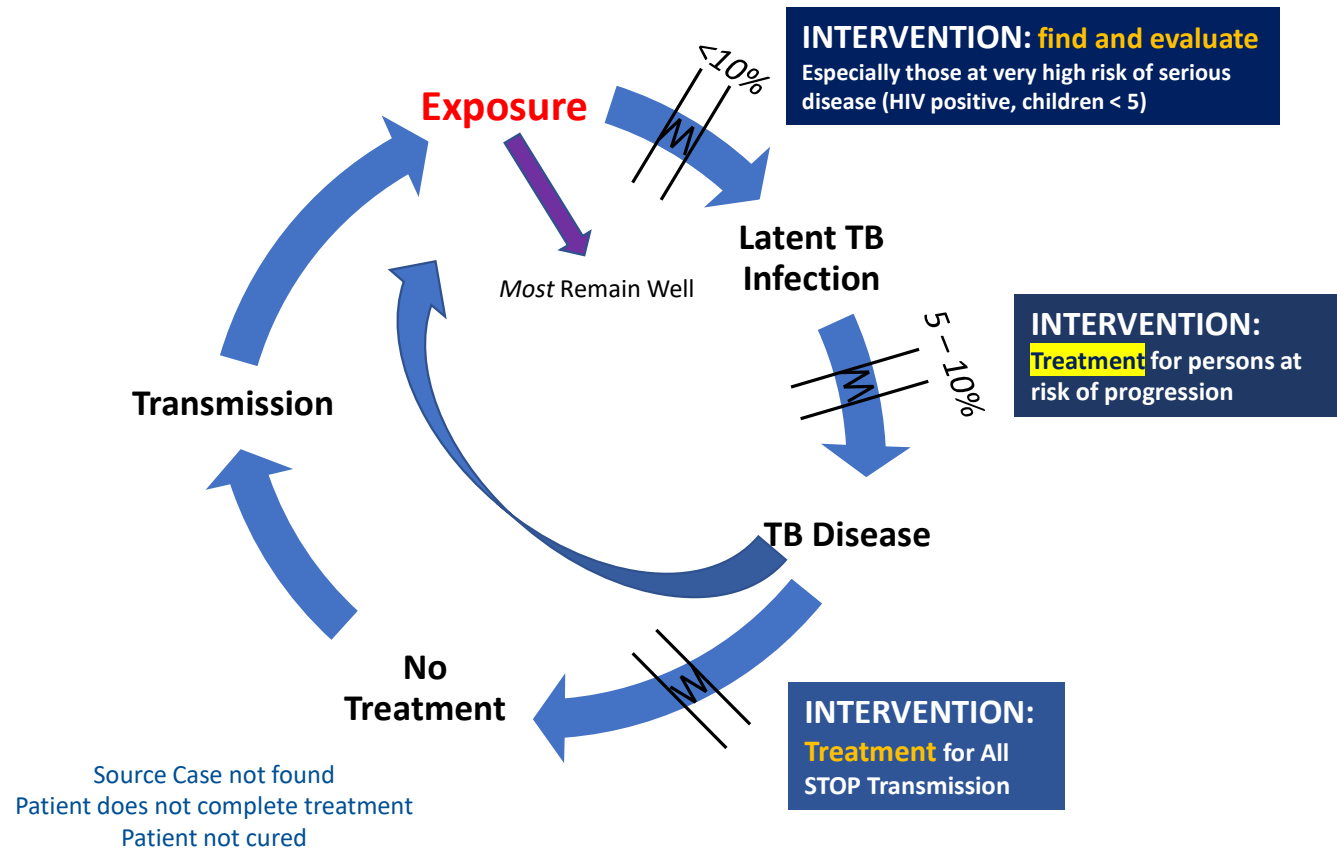
CXR can be normal -
Make sure your patient's
really is.



How Can TB be “Ruled Out?”



Treatment is Prevention



Think TB

TREATMENT IS PREVENTION – WE DO NOT HAVE AN EFFECTIVE VACCINE – YET

TREATMENT STOPS TRANSMISSION

