



Introduction to Radiology For TB Nurse Case Management

Megan Devine, MD

April 29, 2026

TB Nurse Case Management • April 29 – May 1, 2026 • Fort Worth, Texas



Megan Devine, MD

Has the following disclosures to make:

- No conflict of interests
- No relevant financial relationships with any commercial companies pertaining to this activity





Introduction to Radiology For TB Nurse Case Management

Megan Devine, MD

Heartland TB Center

Associate Professor

Pulmonary and Critical Care Medicine

University of Texas Health Science Center at Tyler

Chest Radiology in TB

- X-Rays penetrate air, absorbed by fluids/solids
- Chest radiographs show us shadows of organs and structures in the chest
- Interpretation of a chest radiograph is pattern recognition that requires clinical correlation for true diagnosis
- To know what “abnormal” looks like, you have to know what “normal” looks like



Chest Radiology Basics

- Dark/black = Air
- Dense White = Calcium (Bone Density)
- White = Water Density (Everything else)
 - Water
 - Blood
 - Fat
 - Tissue
 - Pus



Posterior-Anterior CXR



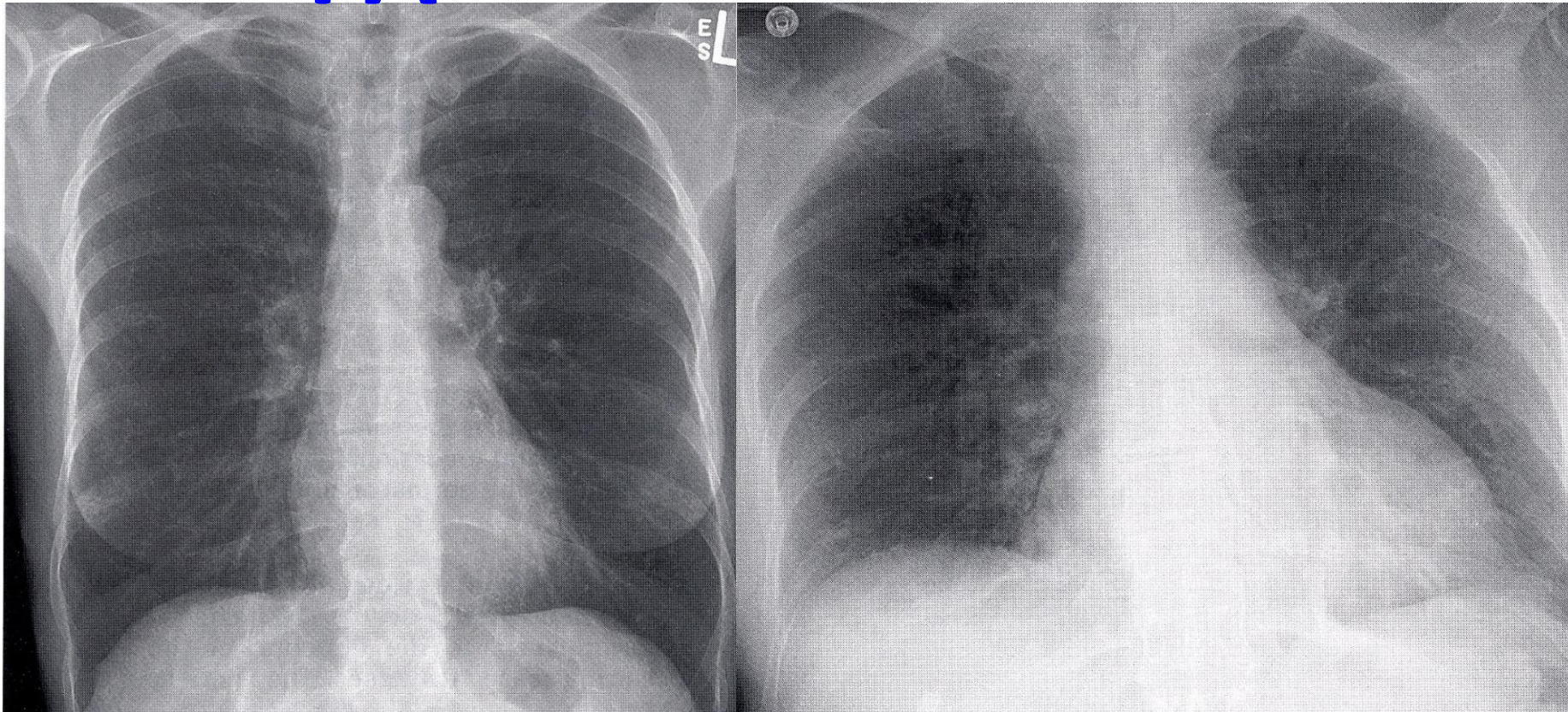
Normal CXR- distance 6 feet from X ray tube to cassette to reduce magnification and enhance sharpness.



Same Patient, Two Views

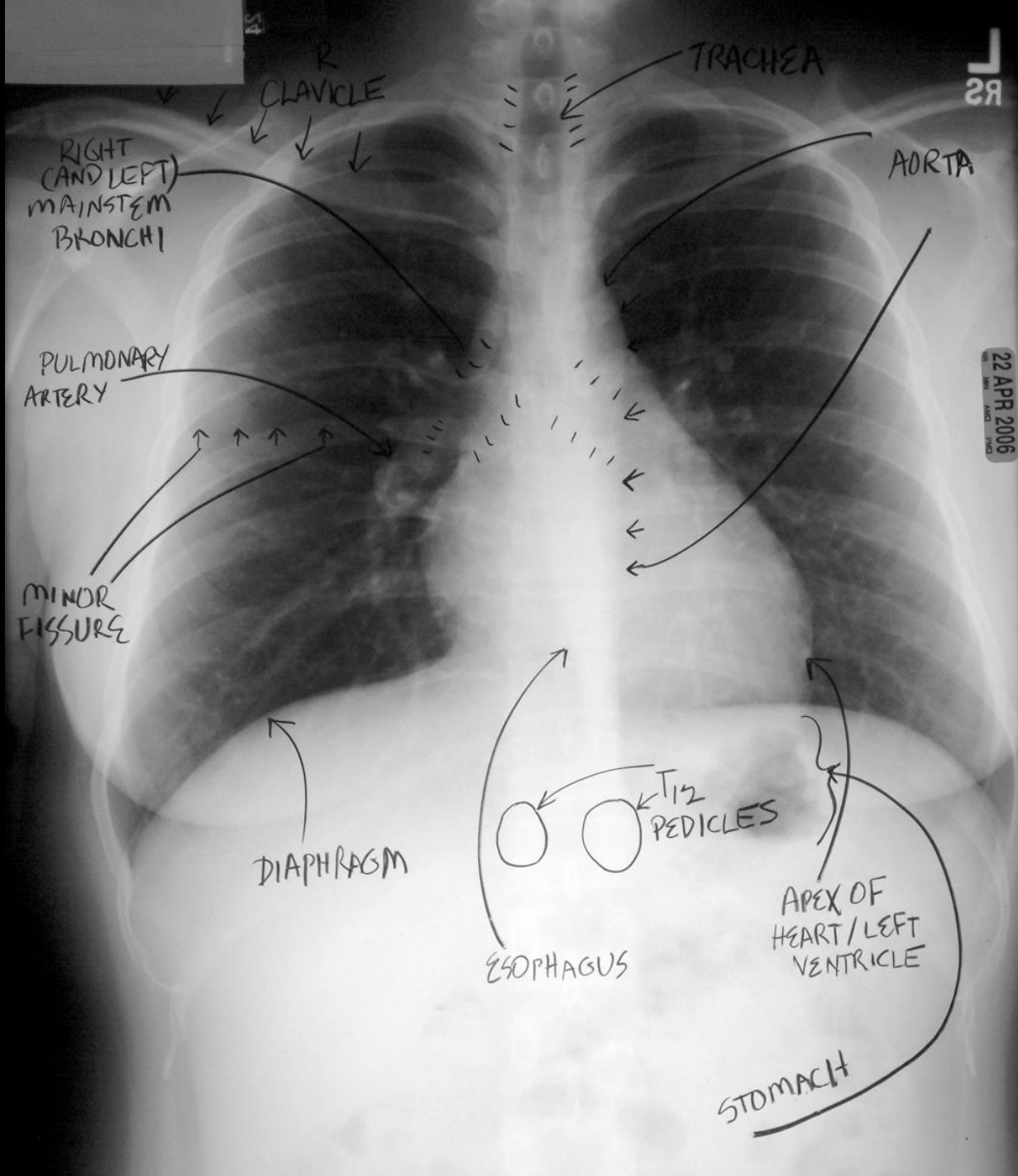
PA

AP

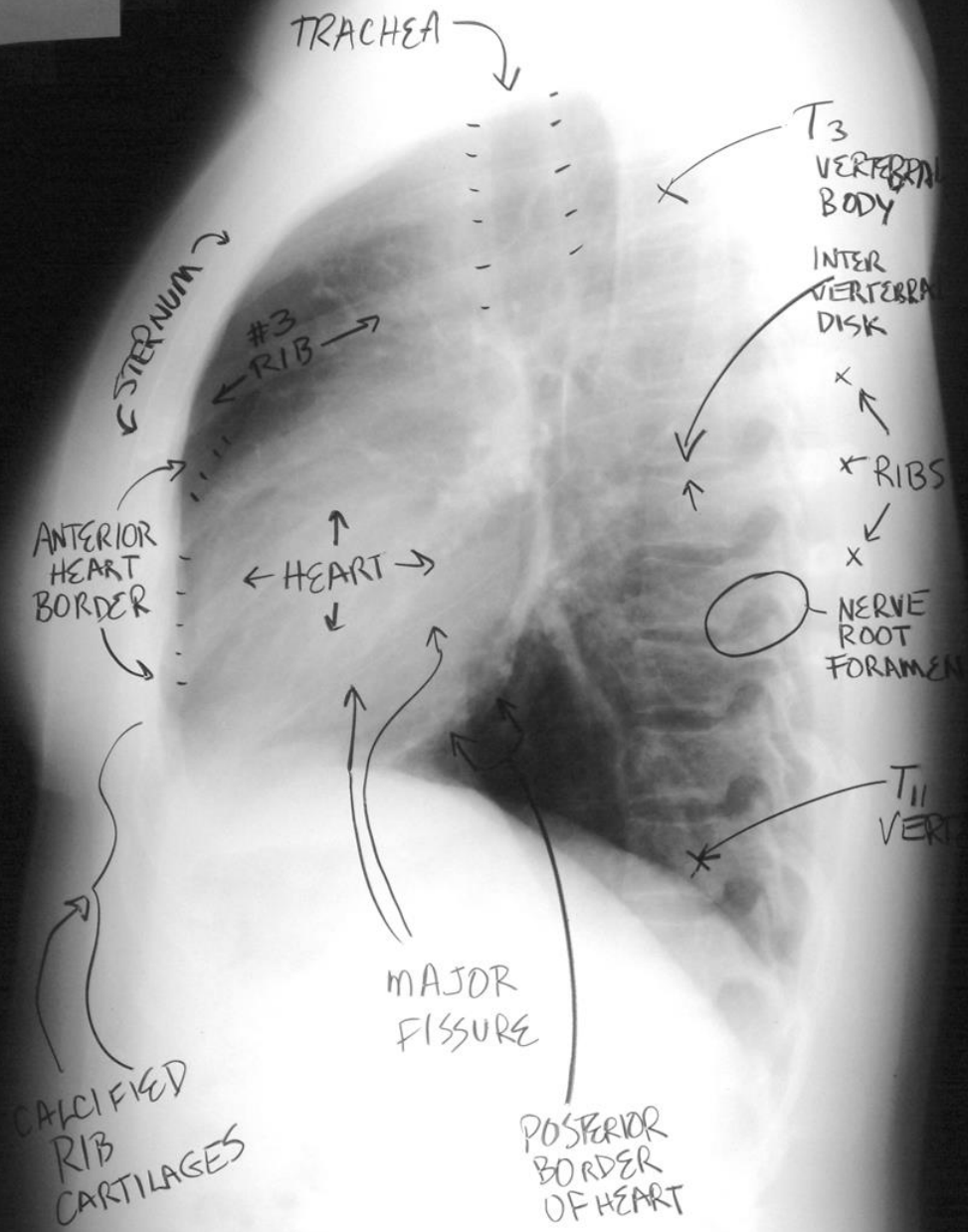


AP is taken at a shorter X-ray tube to receptor distance.
Compared with the PA CXR, the AP has a greater magnification, and the anatomy appears less sharp.





22 APR 2006



Role of CT in the Diagnosis of TB

- CT is not the primary radiologic diagnostic test for TB (CT is overused in the US)
- Usually don't need CT for cavitary consolidation
- If TB is a possible diagnosis, sputum for AFB should be obtained prior to CT
- In most instances, CT should be reserved for patients in whom the diagnosis is unclear

But...if a CT scan has been performed, we want to review it.
Please get the report and the images!



Common Radiographic Patterns

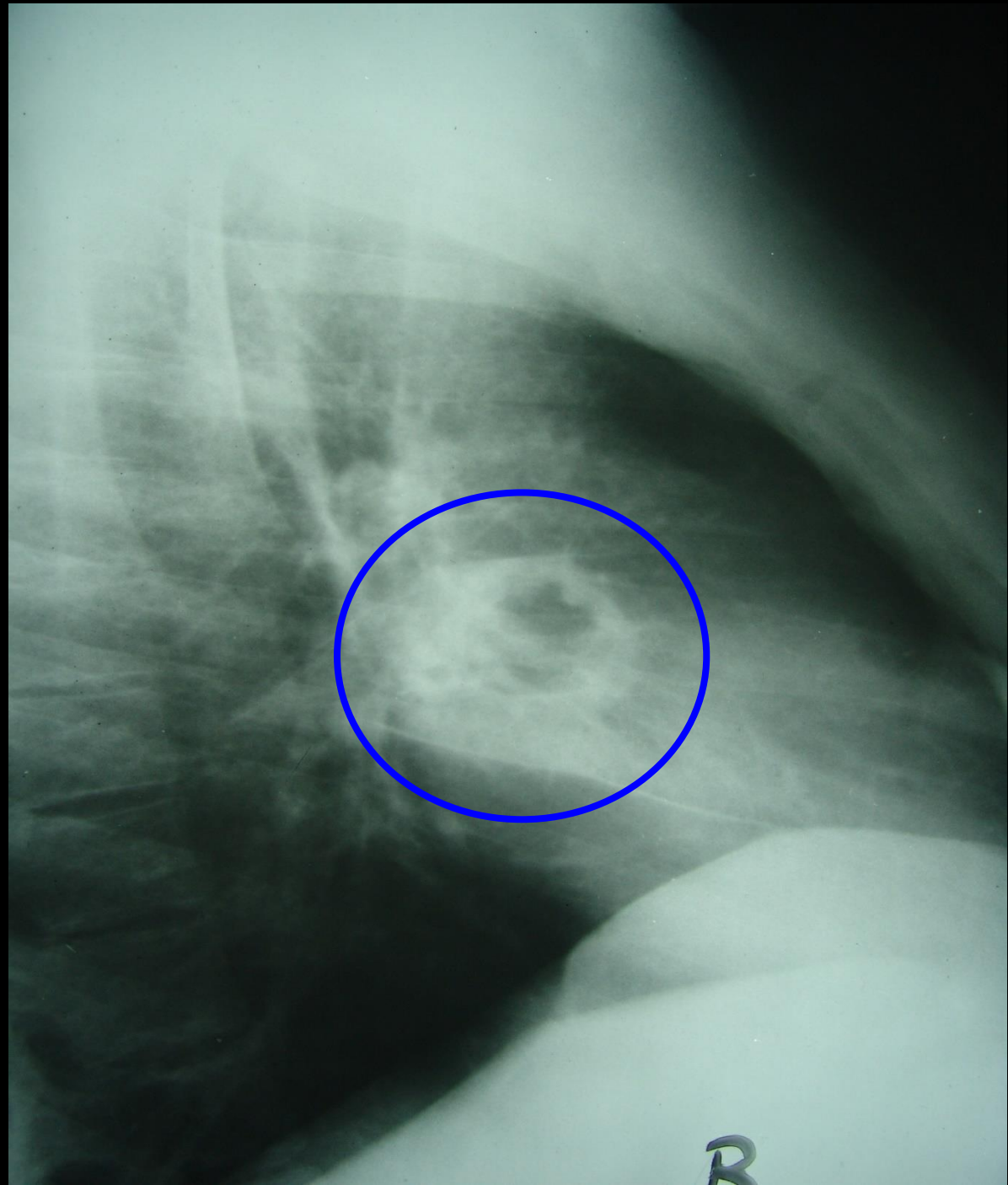
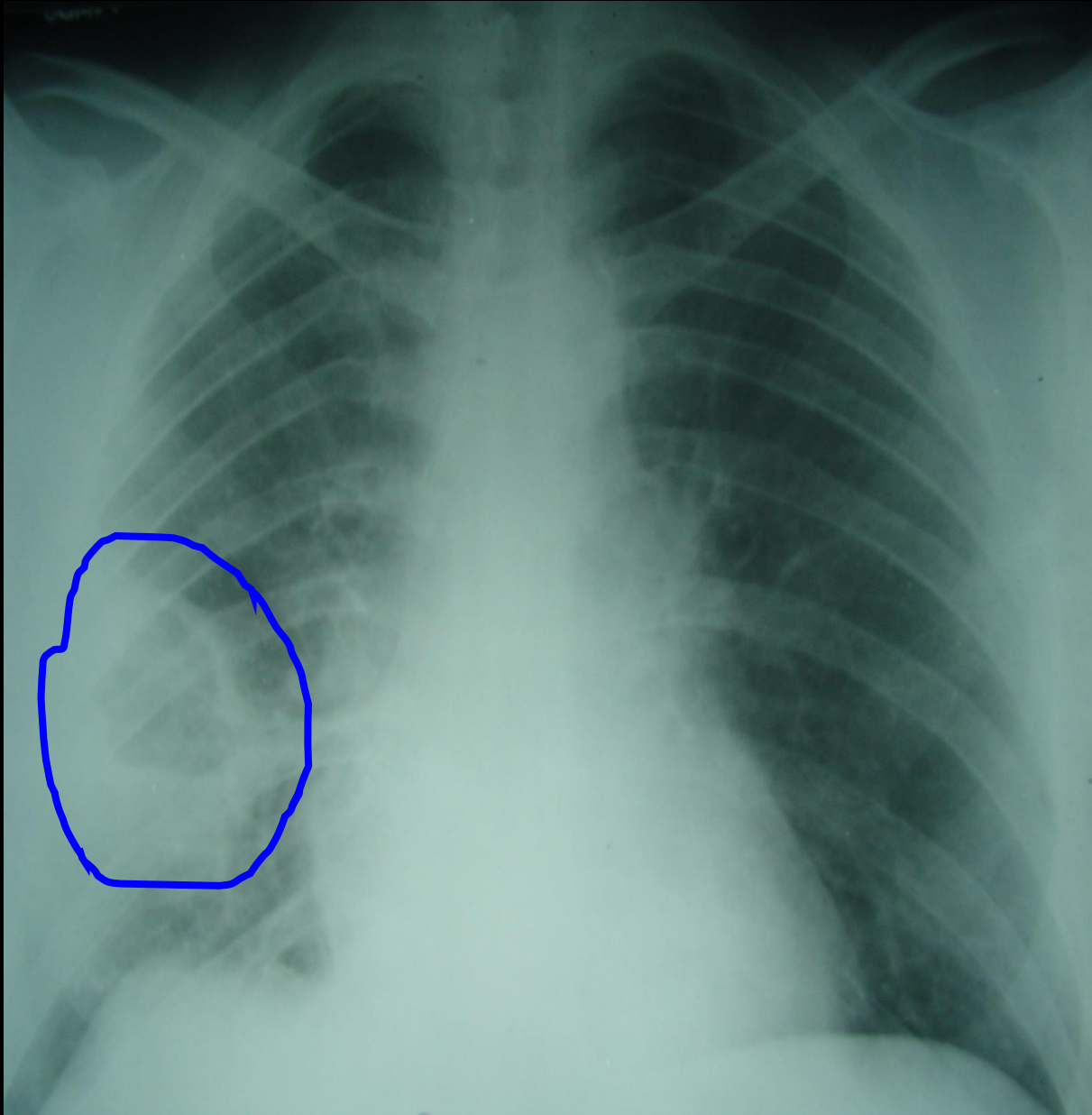


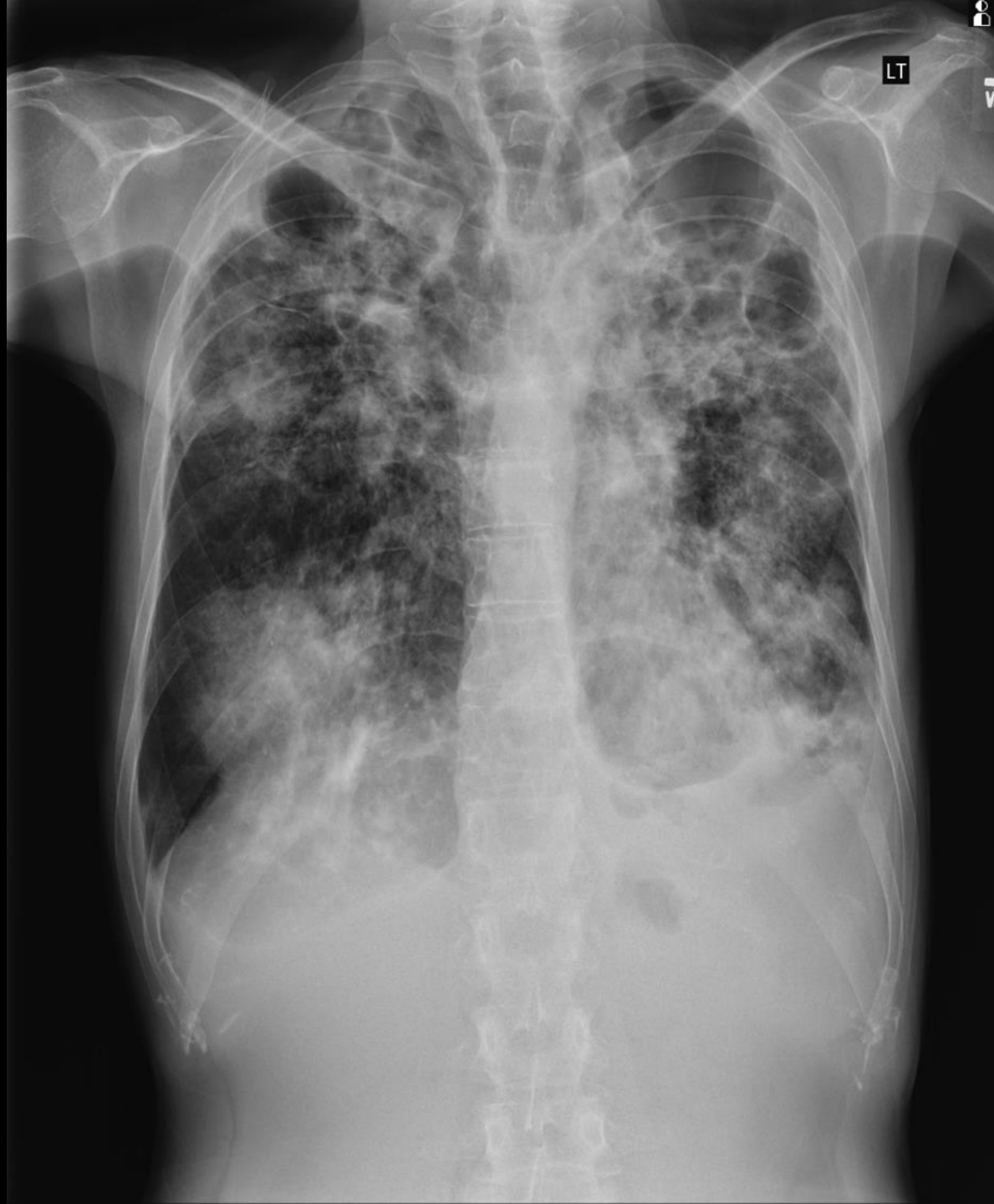Cavitation



R

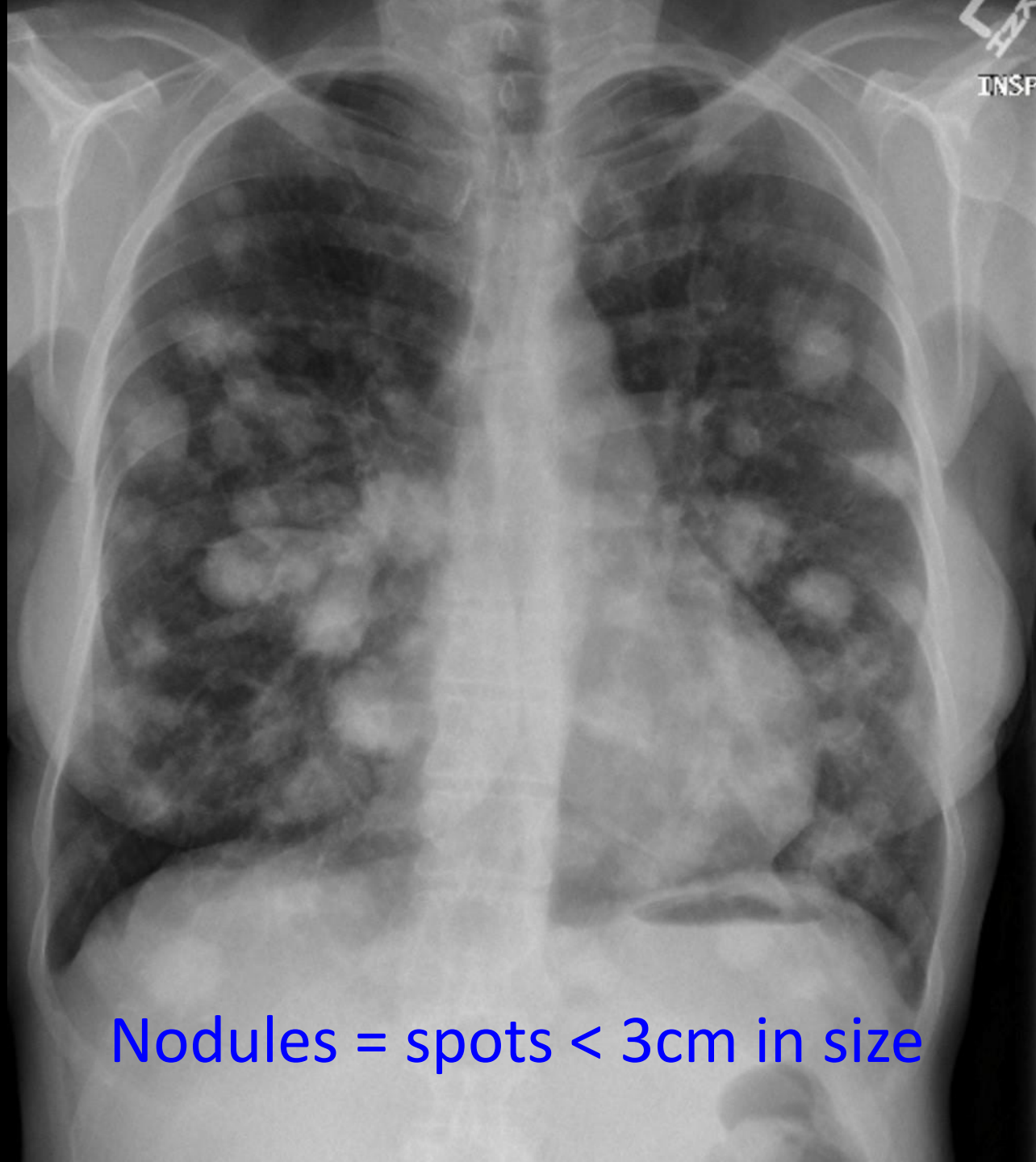






Nodules



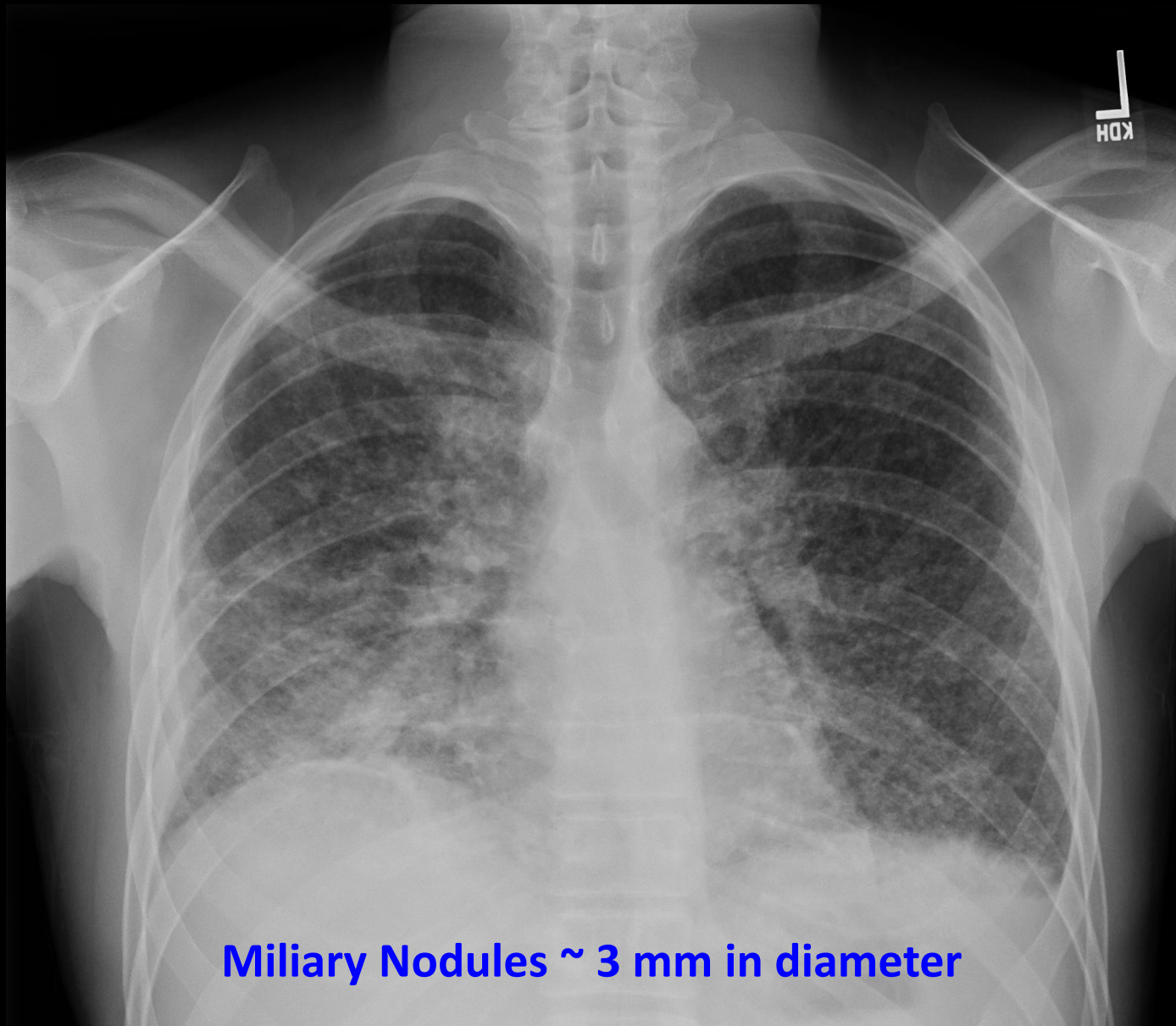


INSP

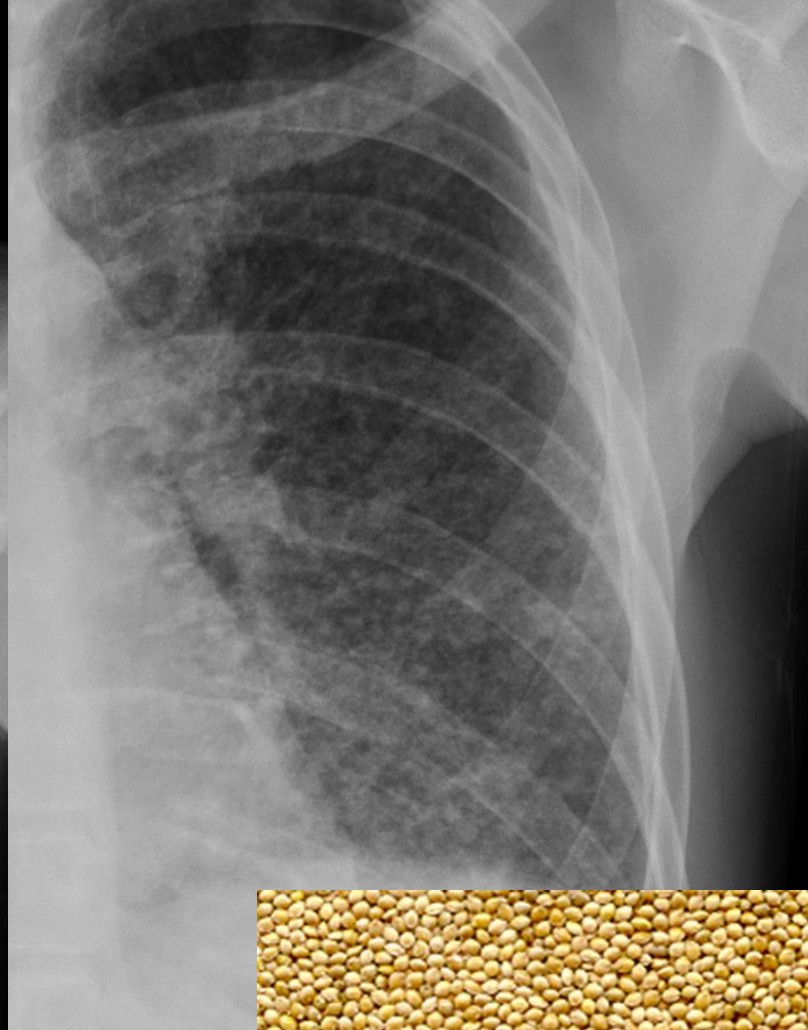
Nodules = spots < 3cm in size

Miliary Nodules

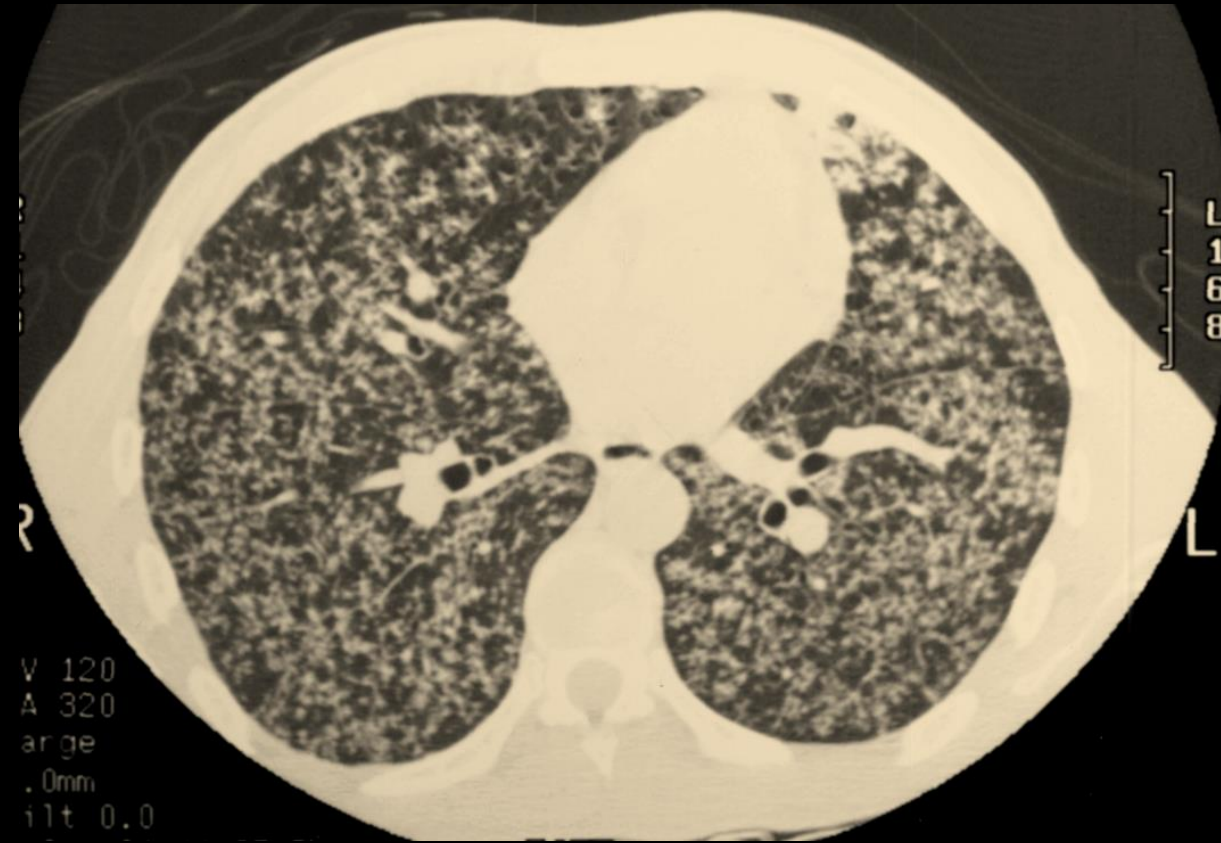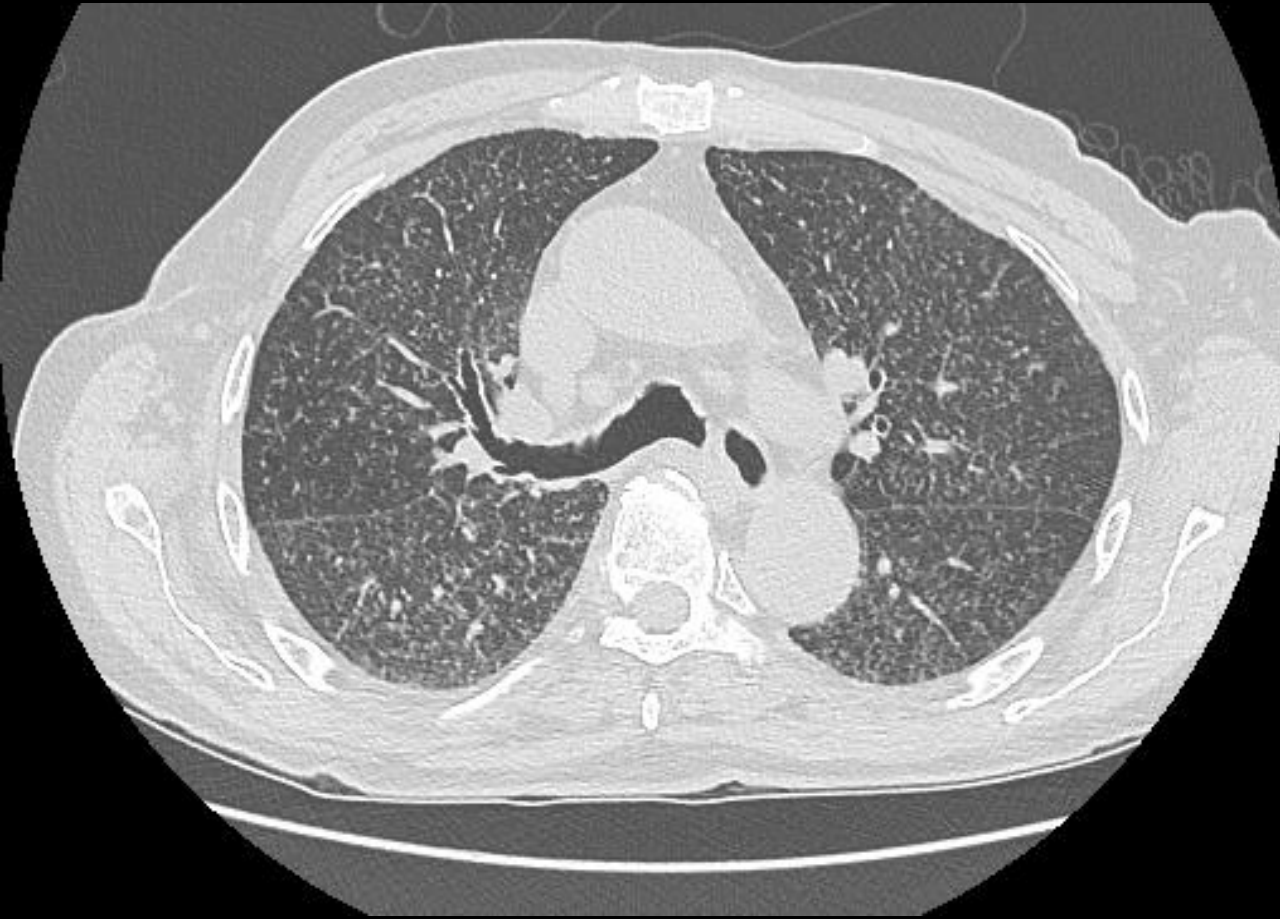




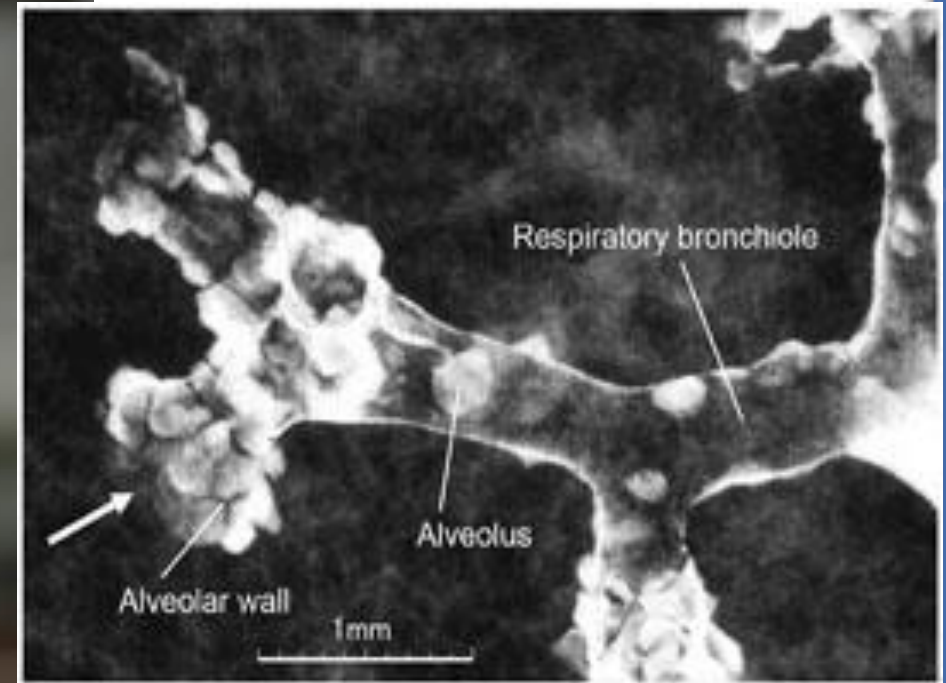
Miliary Nodules ~ 3 mm in diameter

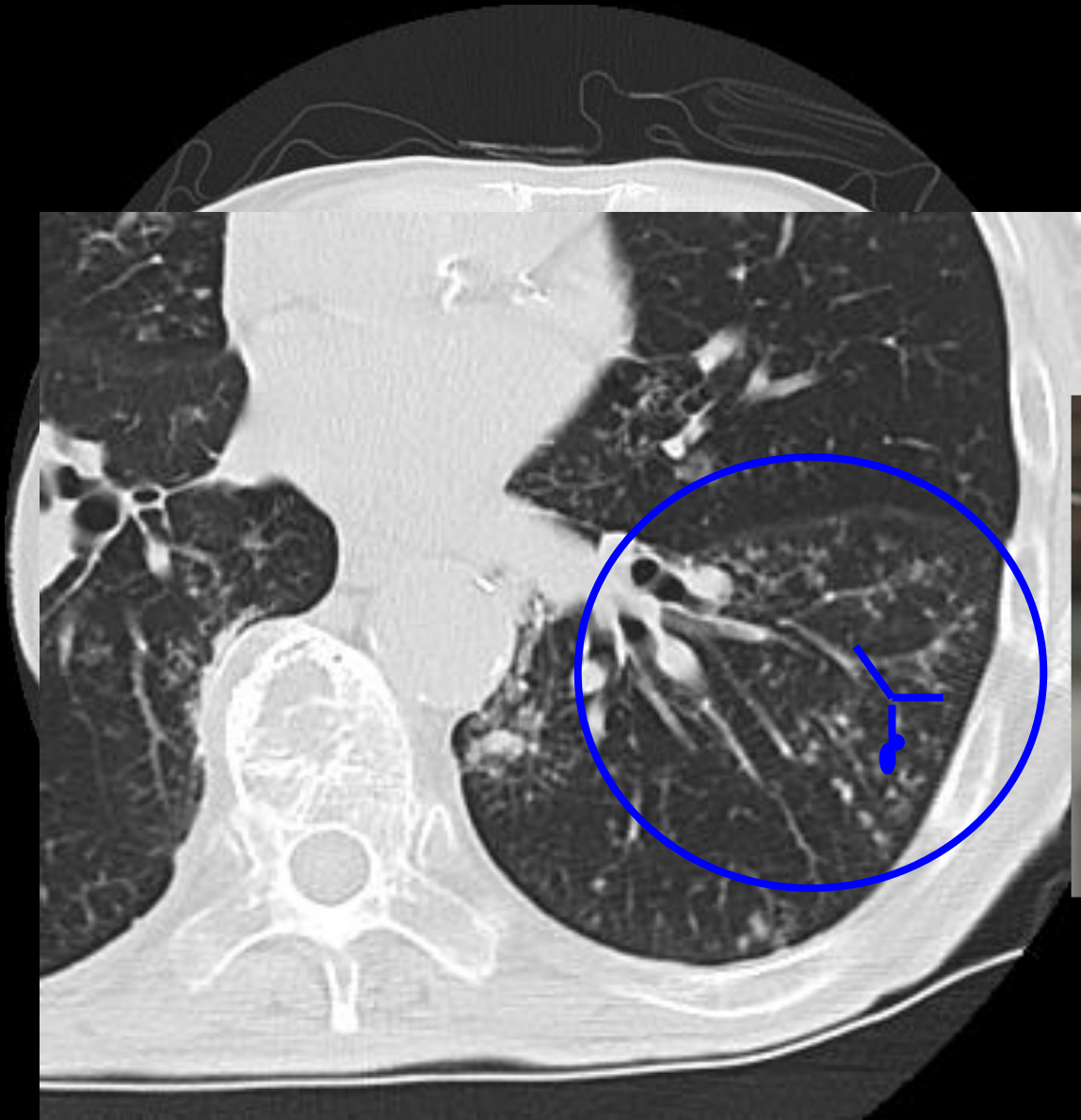

Miliary TB



Tree in Bud Nodules



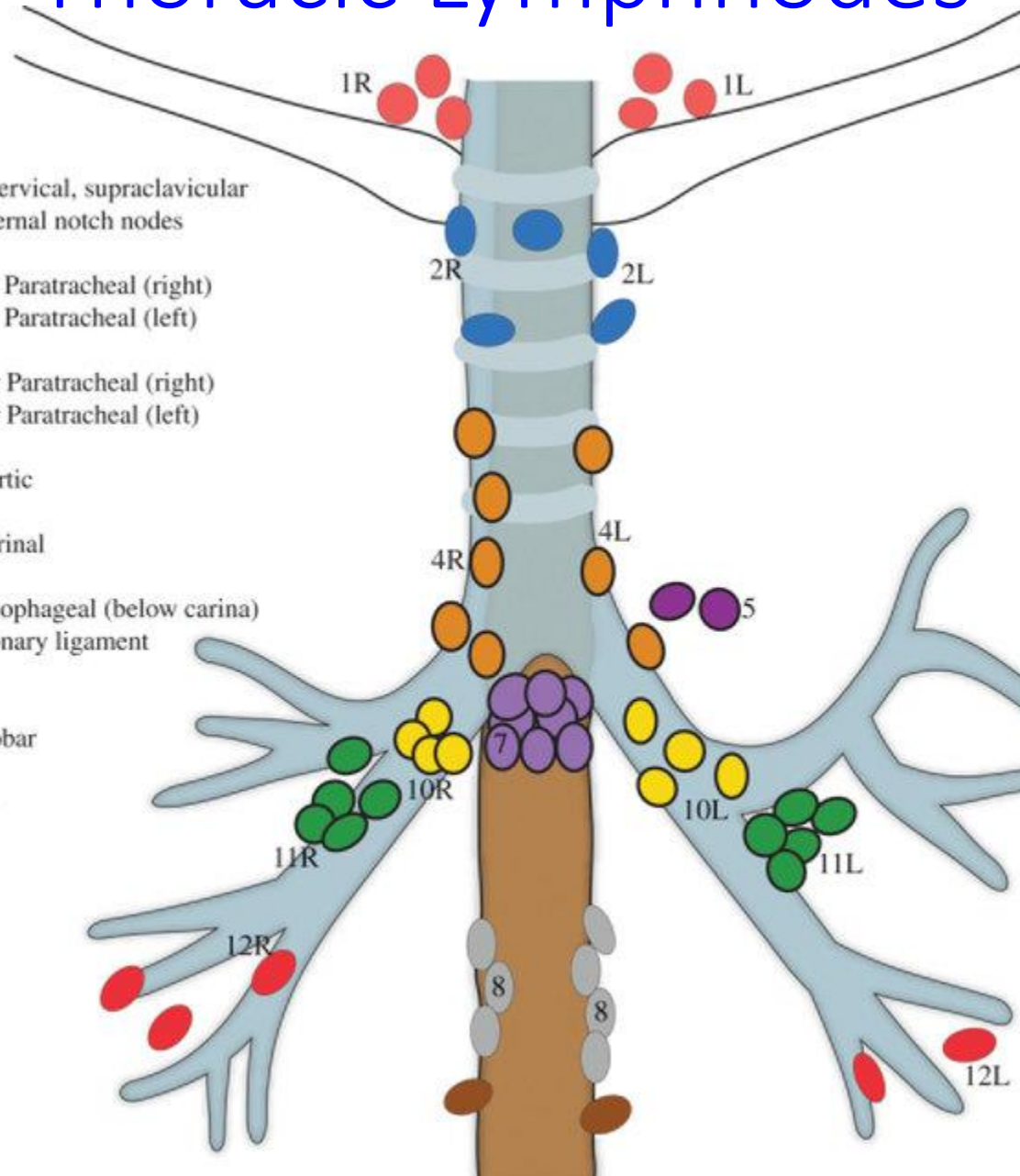


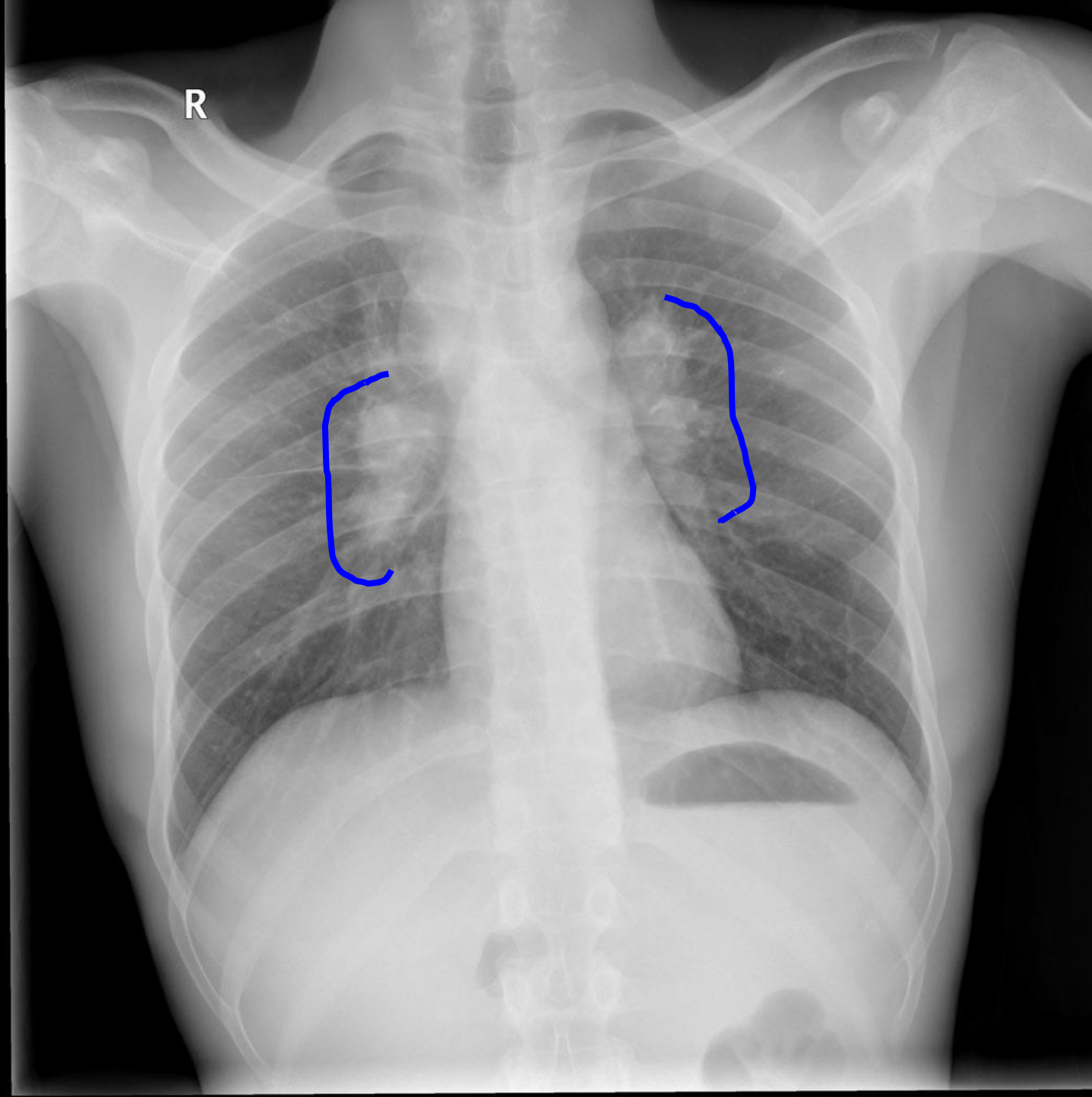
Adenopathy



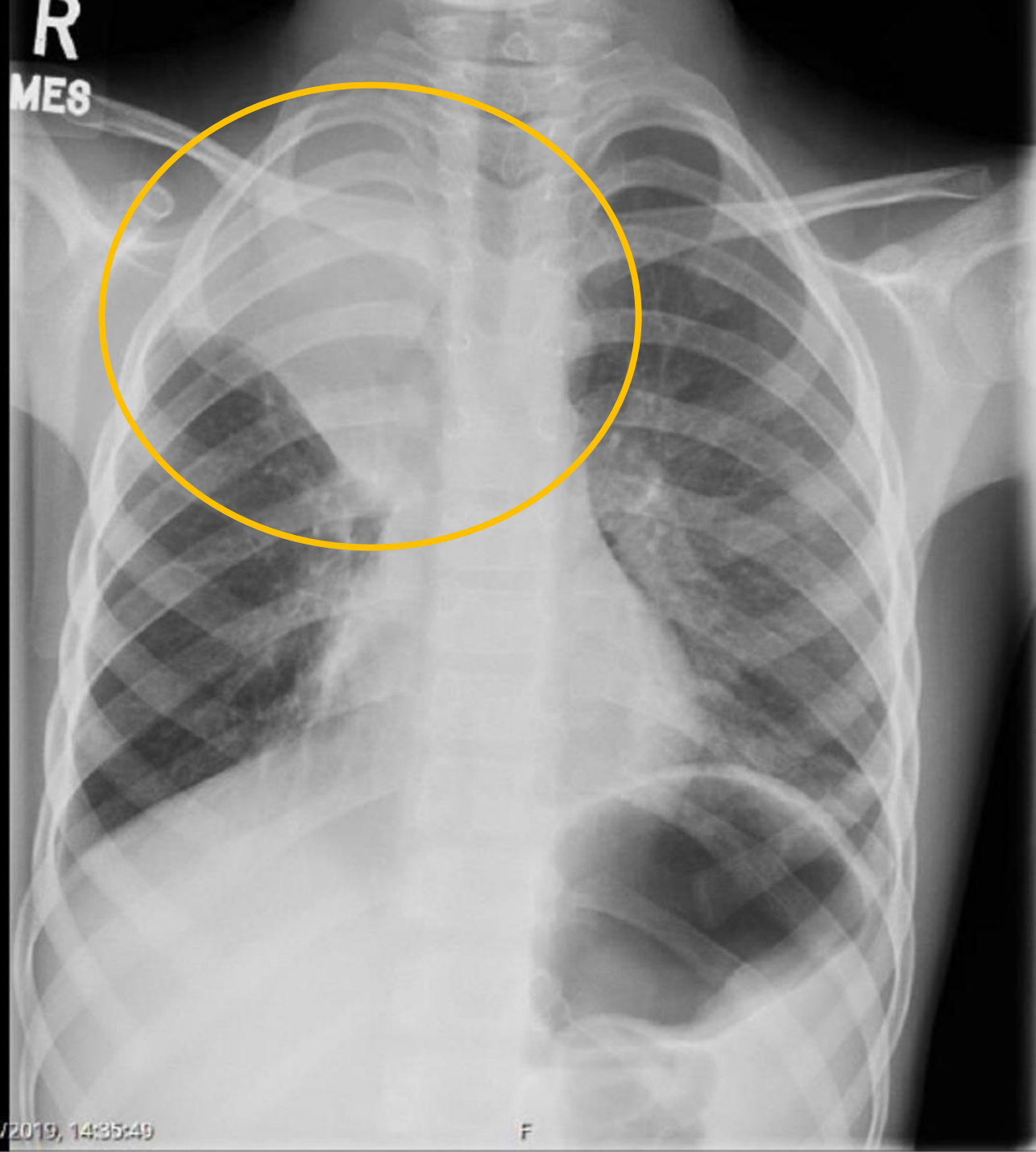
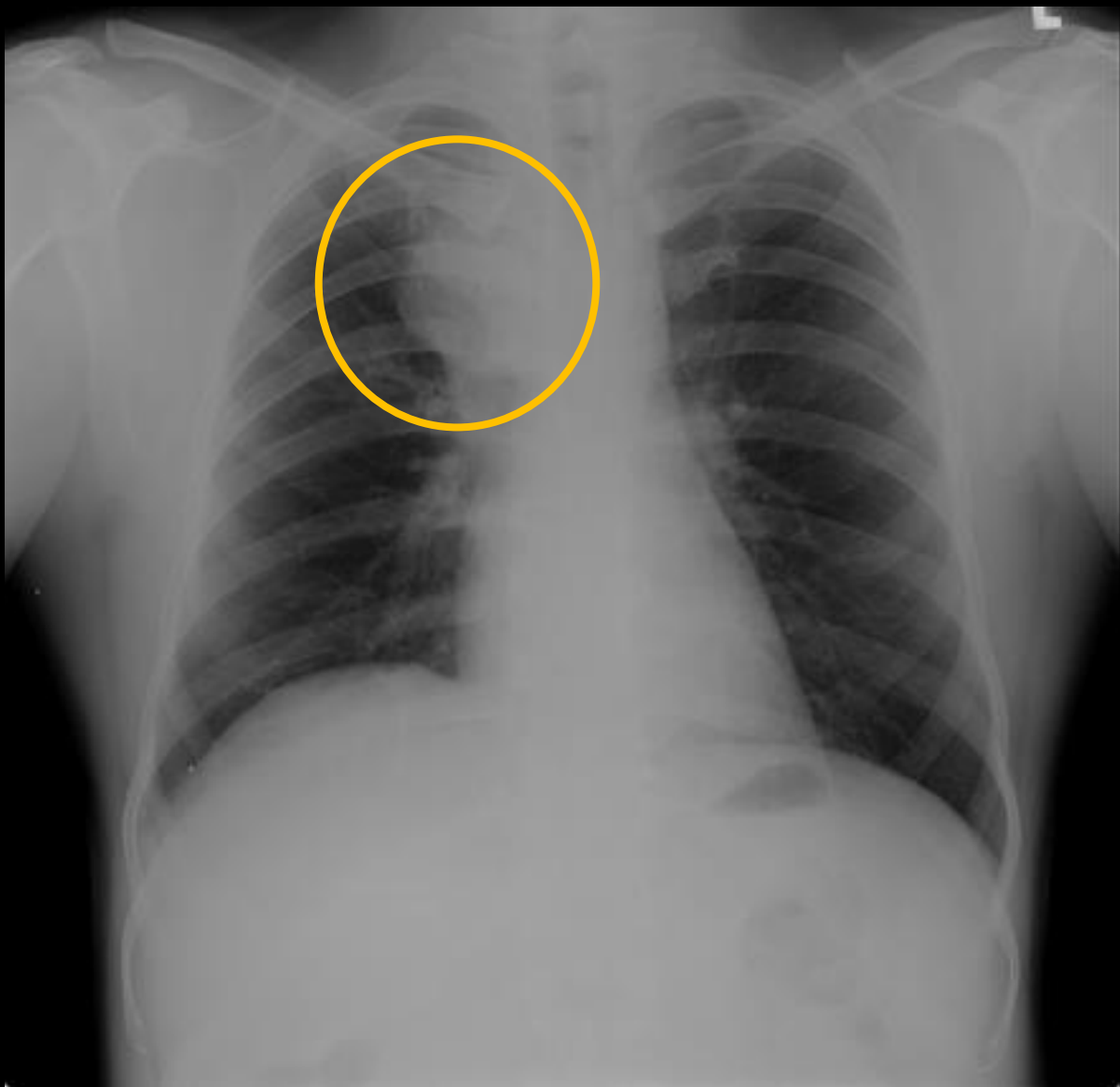
Thoracic Lymphnodes

- | 1 Low cervical, supraclavicular and sternal notch nodes
- | 2R Upper Paratracheal (right)
- | 2L Upper Paratracheal (left)
- | 4R Lower Paratracheal (right)
- | 4L Lower Paratracheal (left)
- | 5 Subaortic
- | 7 Subcarinal
- | 8 Paraesophageal (below carina)
- | 9 Pulmonary ligament
- | 10 Hilar
- | 11 Interlobar
- | 12 Lobar





R



08/2019, 14:35:49

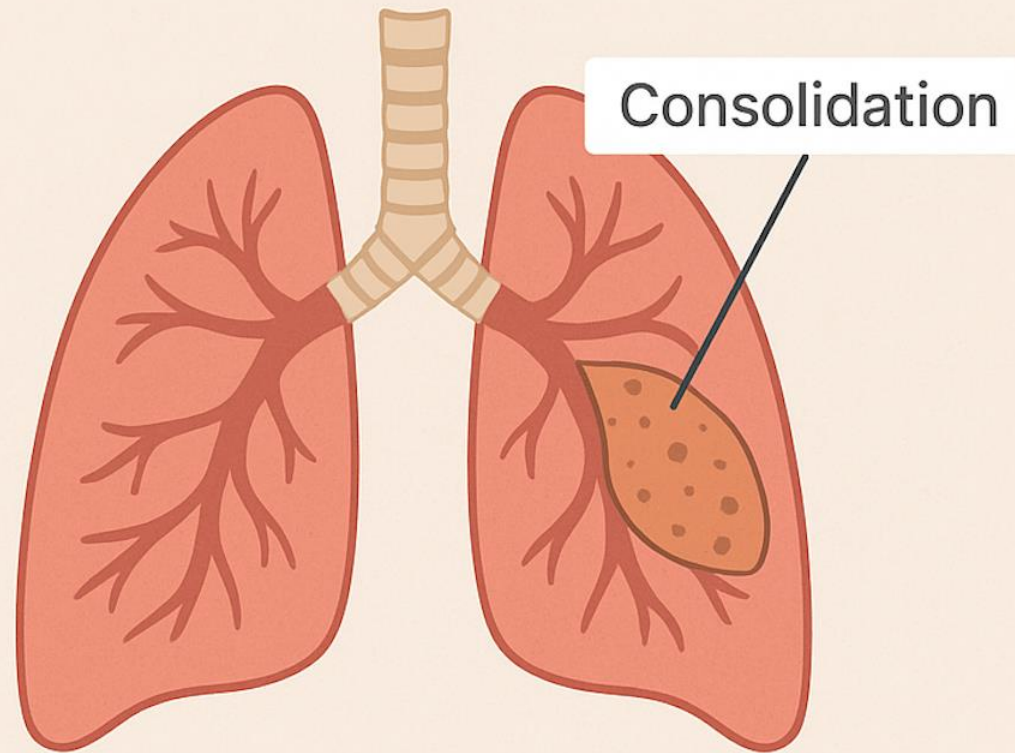
F

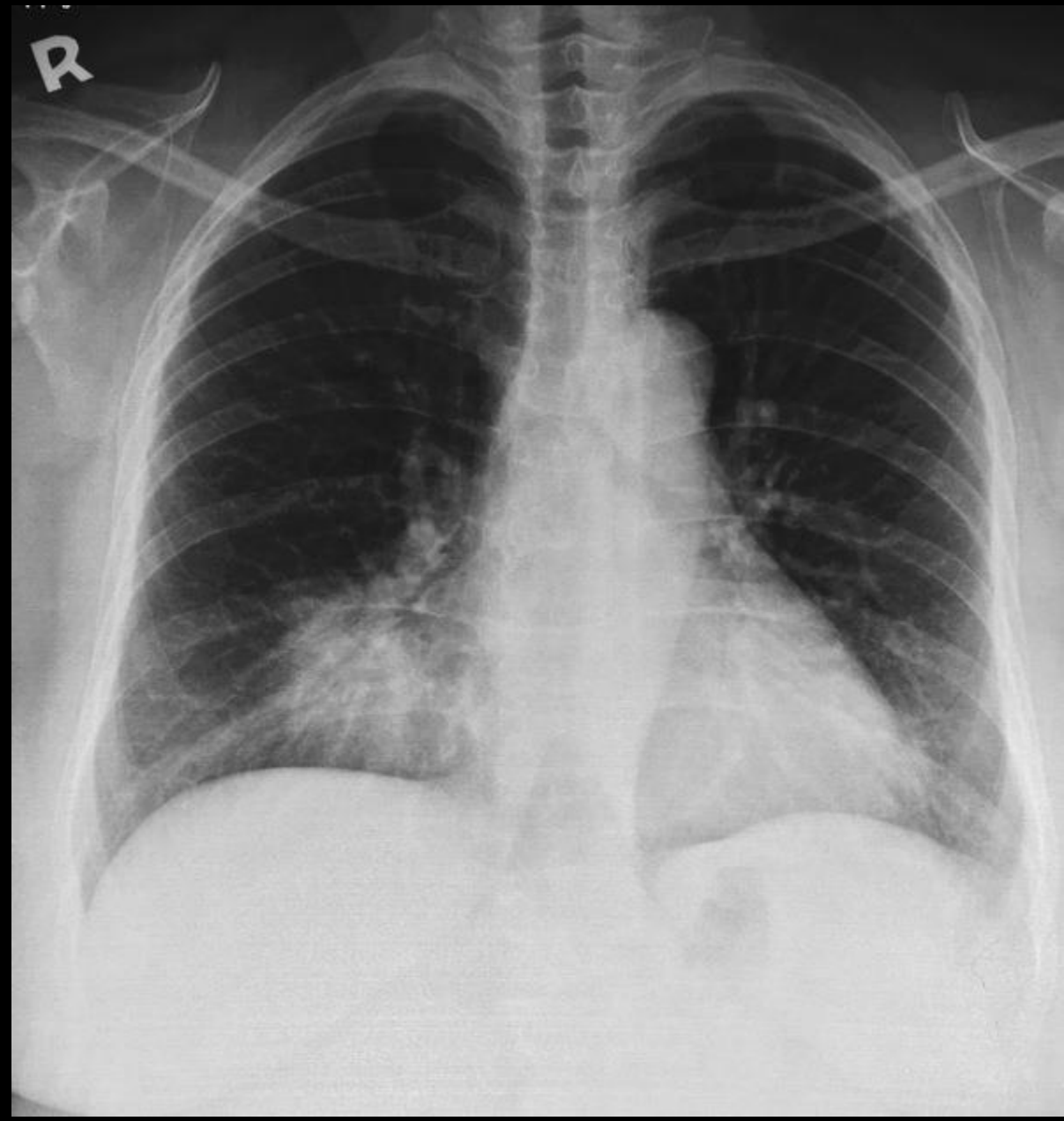
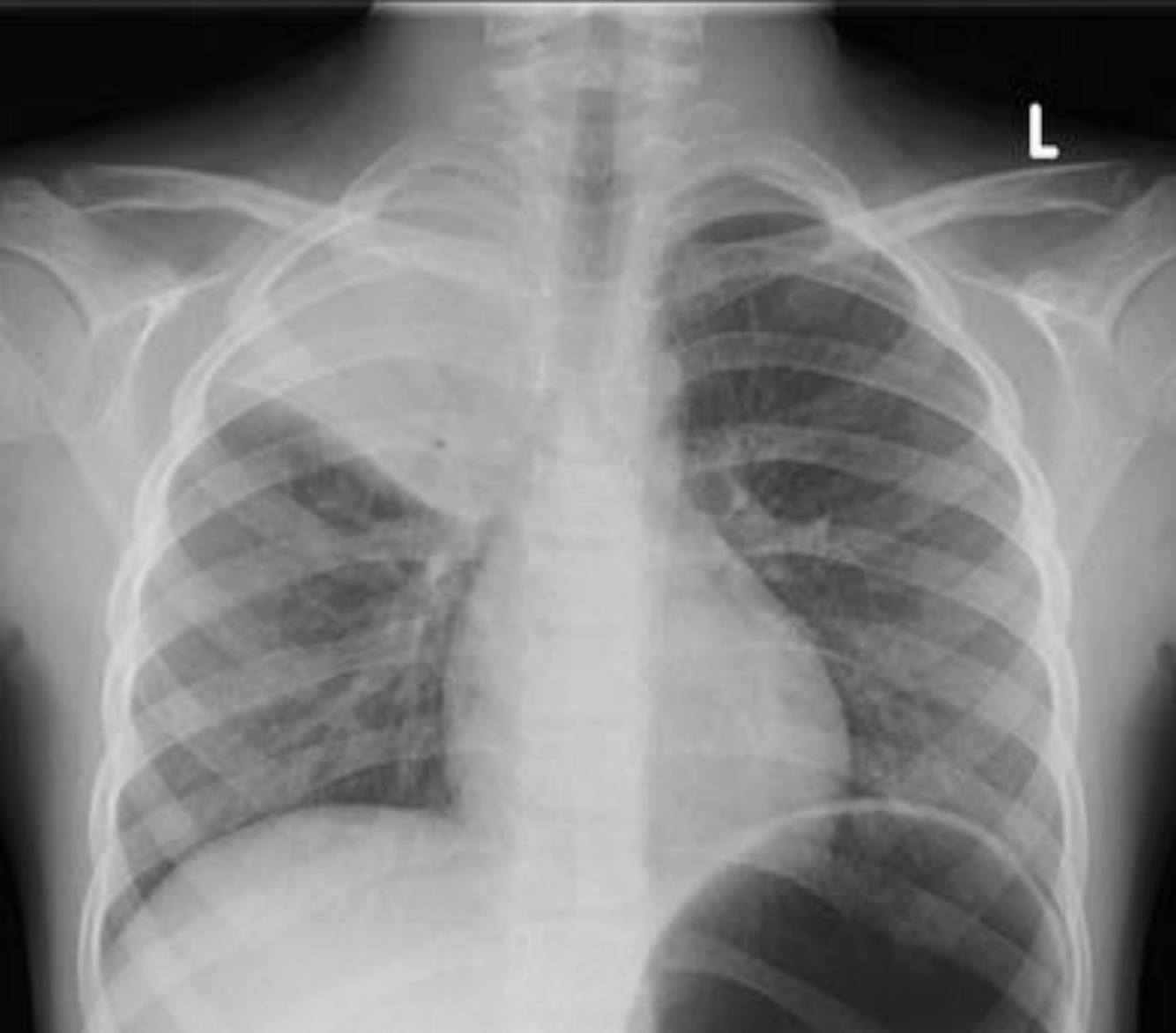Consolidation



LUNG CONSOLIDATION

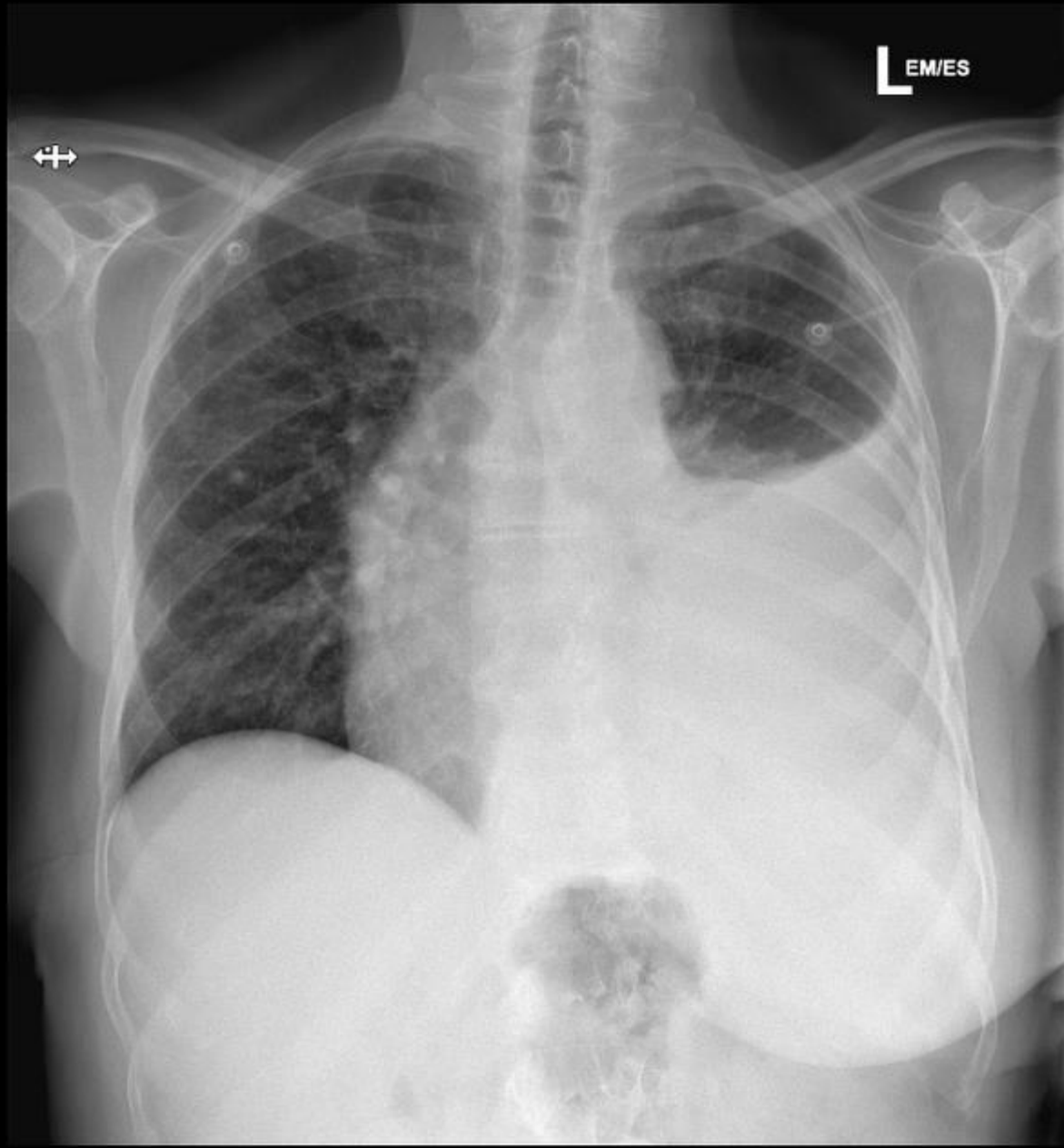
Lung consolidation is a condition in which normally air-filled lung tissue becomes filled with fluid, pus, blood, or other material, making it appear solid or "consolidated" on imaging studies like chest X-rays or CT scans.

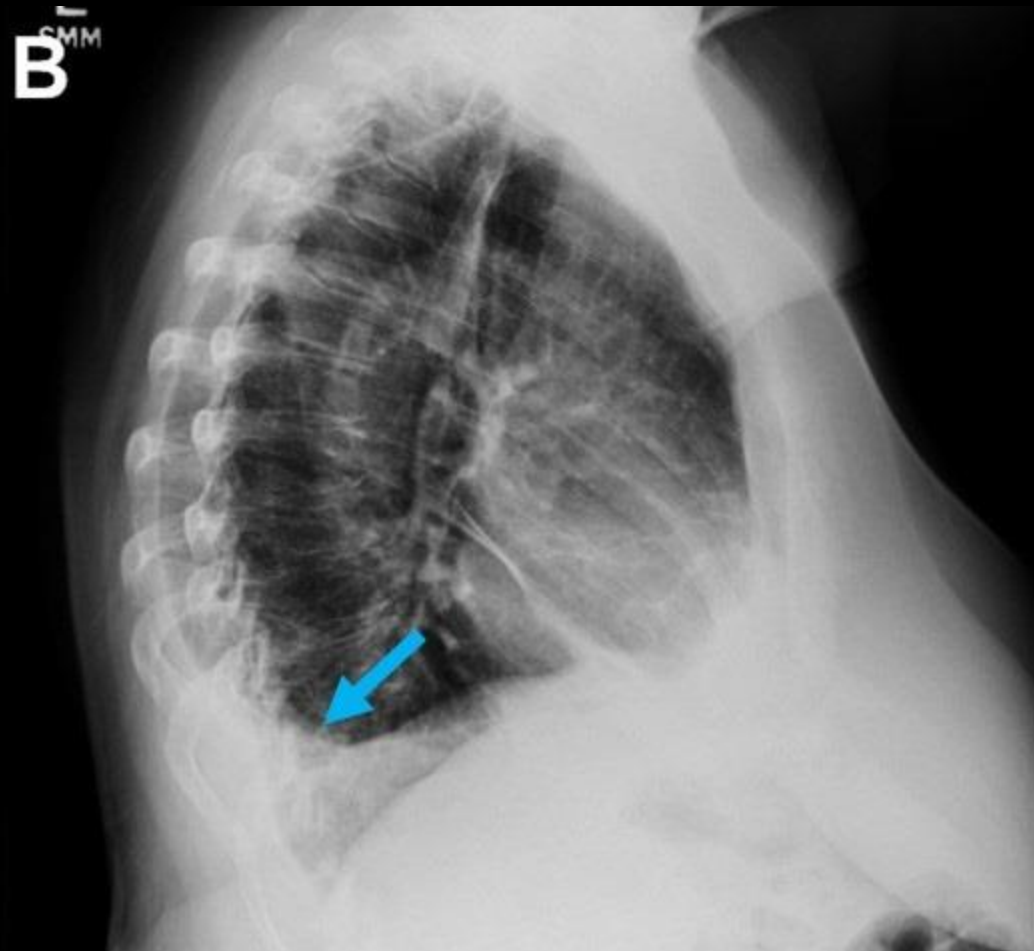
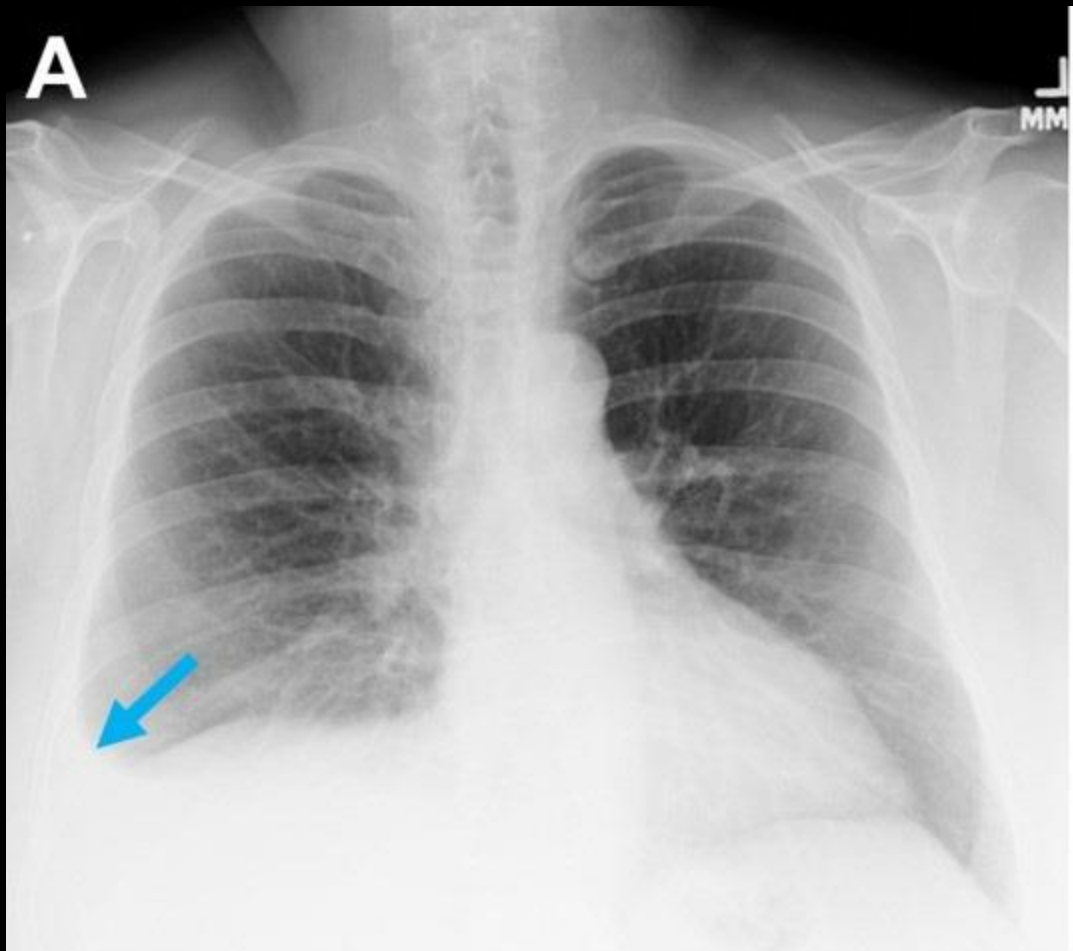




Pleural Effusions





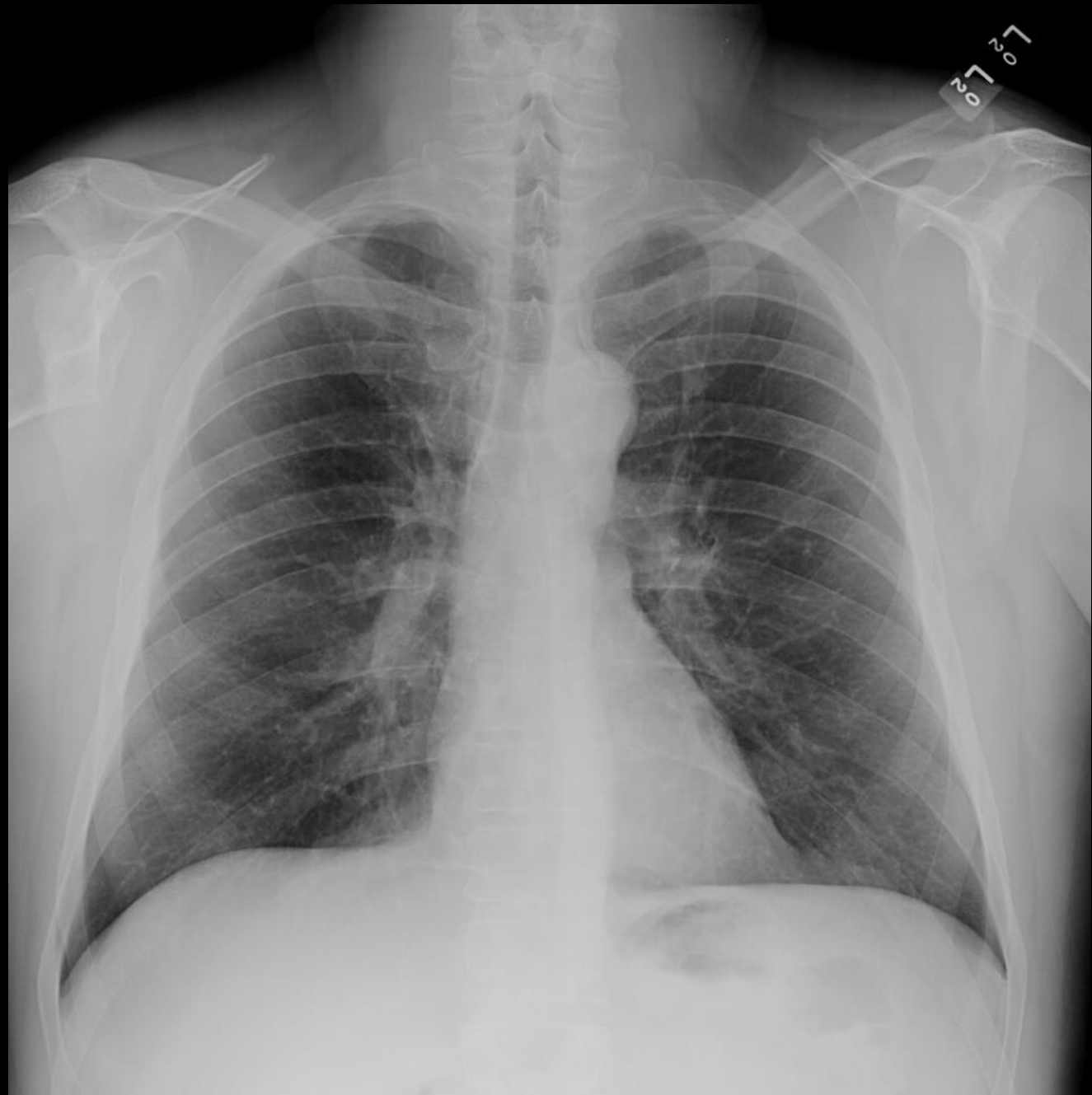

Normal Or Abnormal ?



Systematic Review of CXR:

A
B
C
D
E

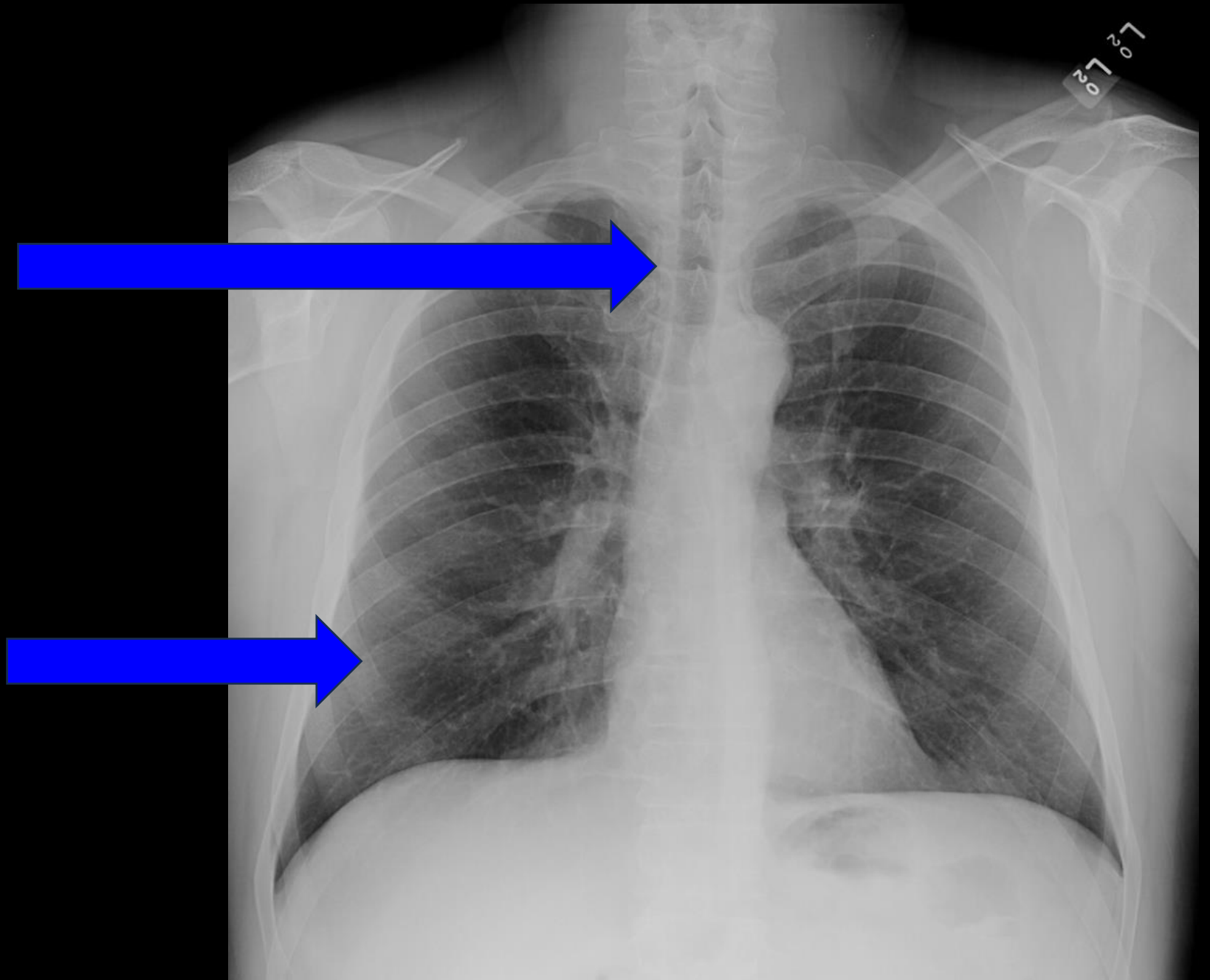


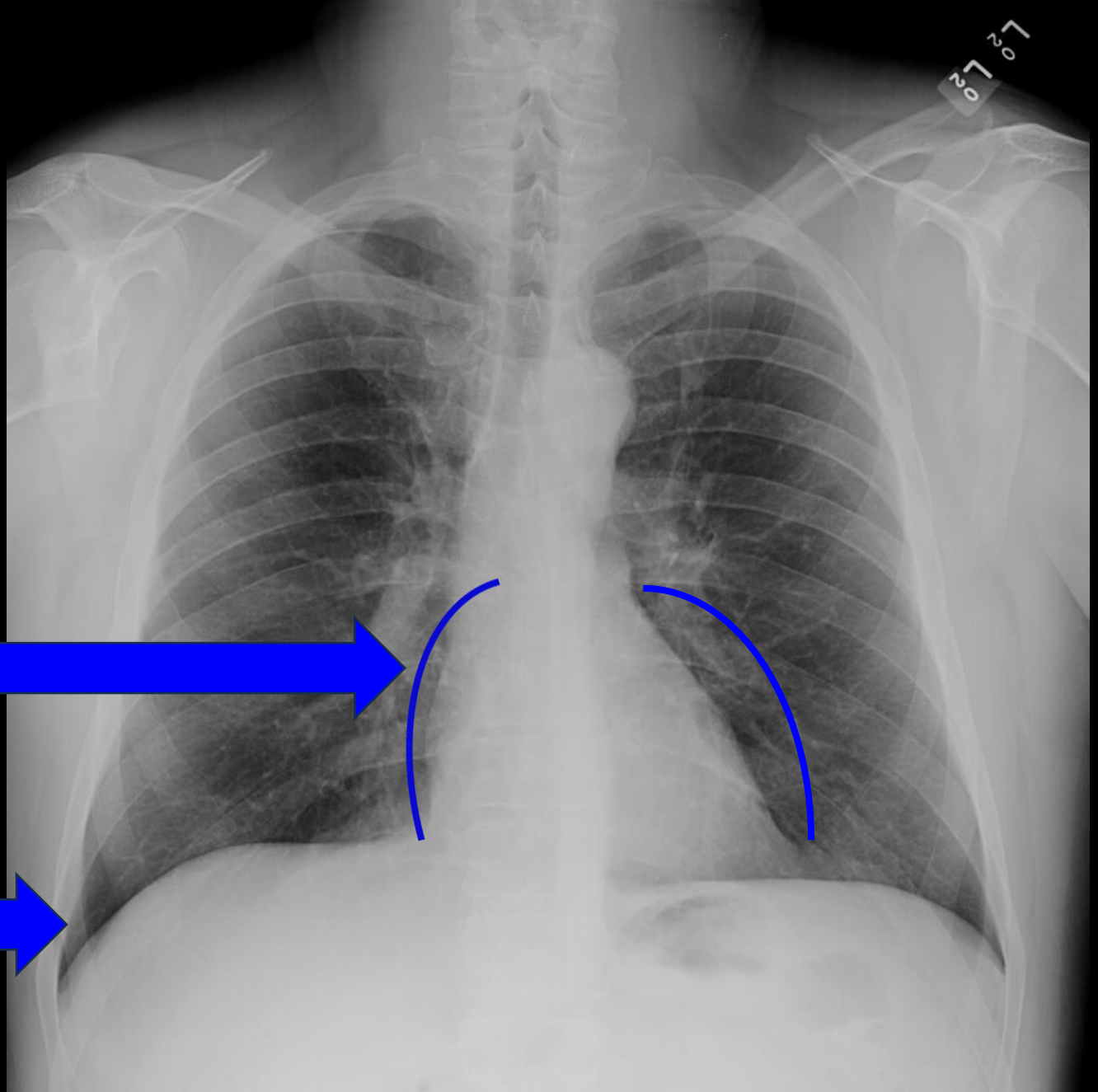
A – Airway

- Smooth
- Straight
- Midline

B – Bones

- Visible
- Smooth





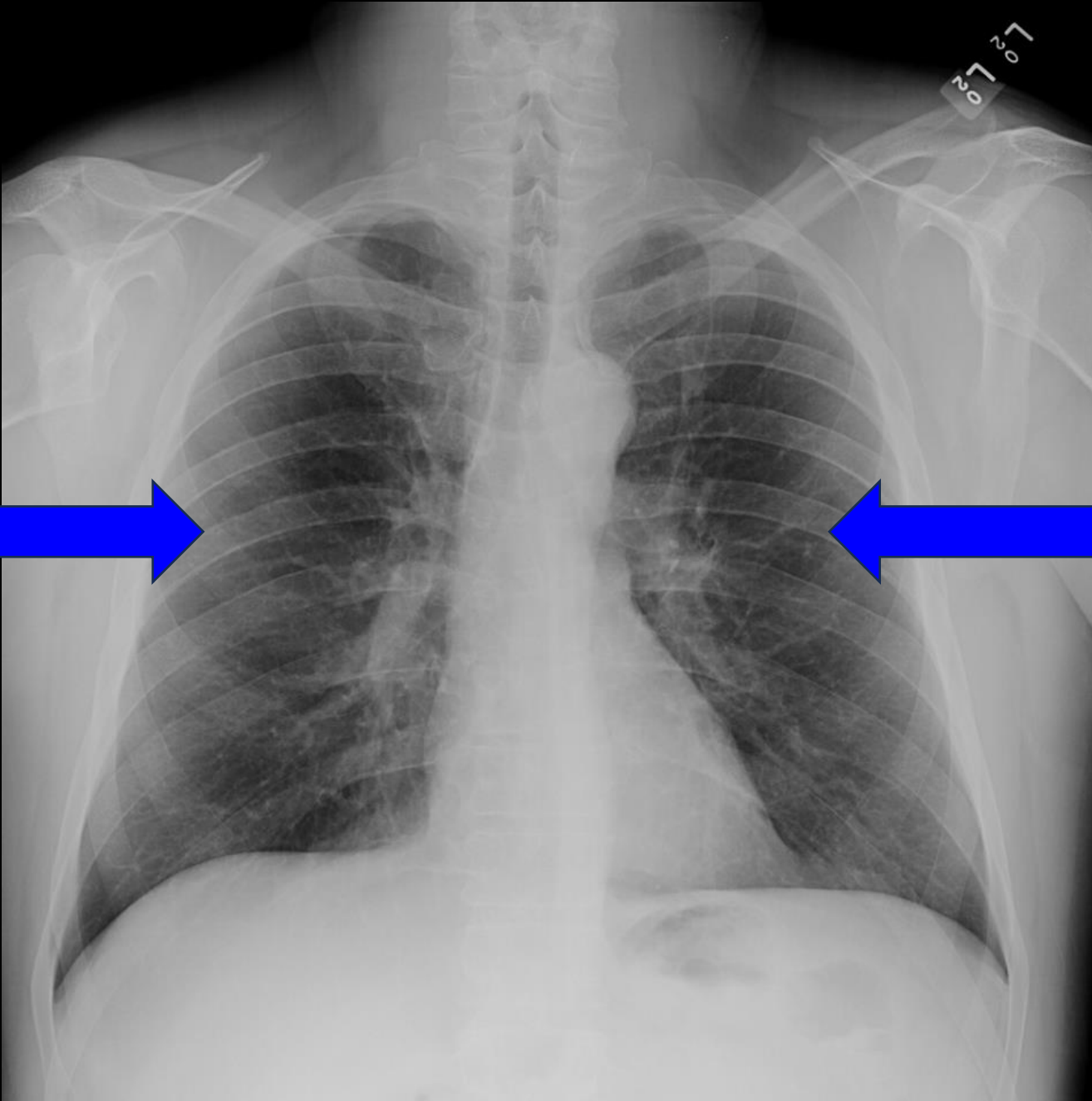
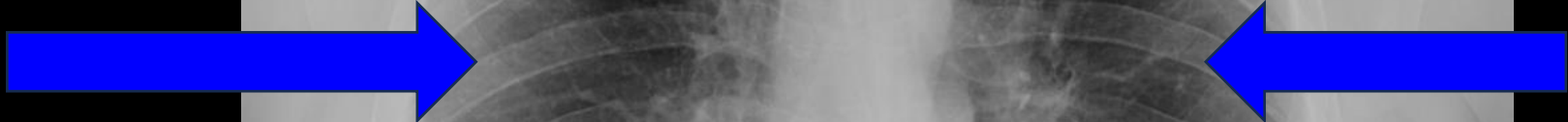C – Cardiac

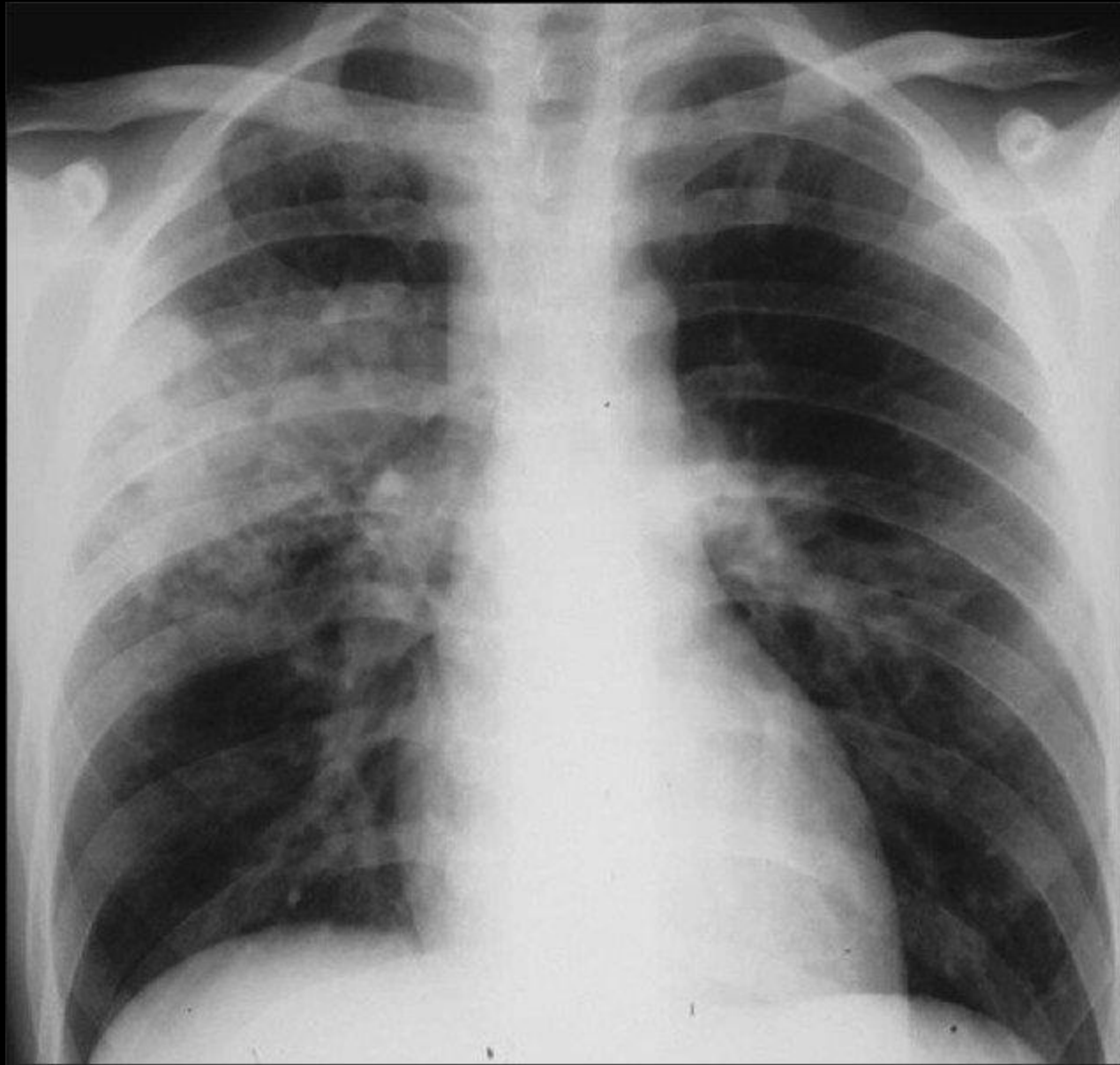
- Visible
- Smooth

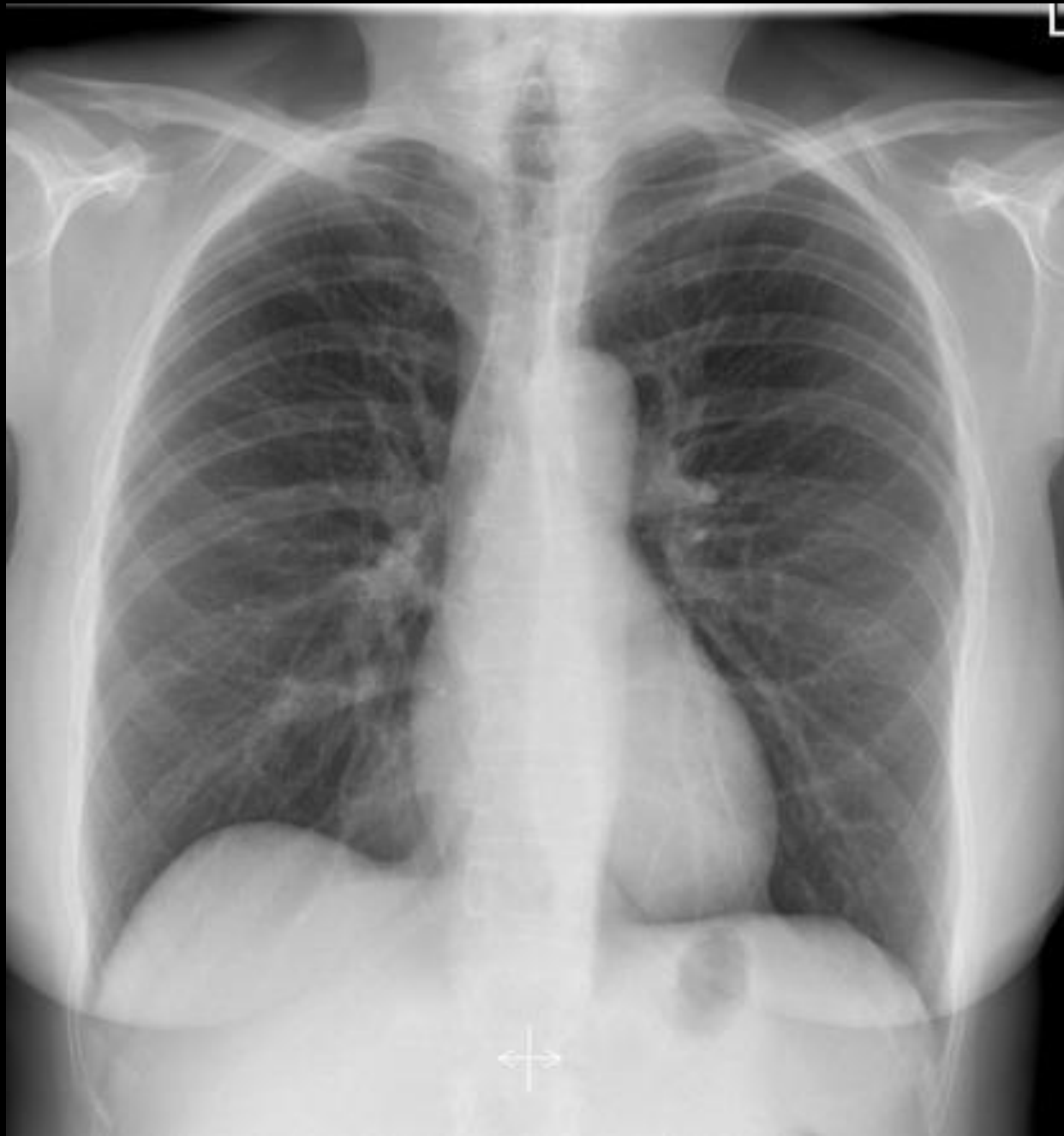D – Diaphragm

- Visible
- Smooth
- Sharp angle

E – Everything Else

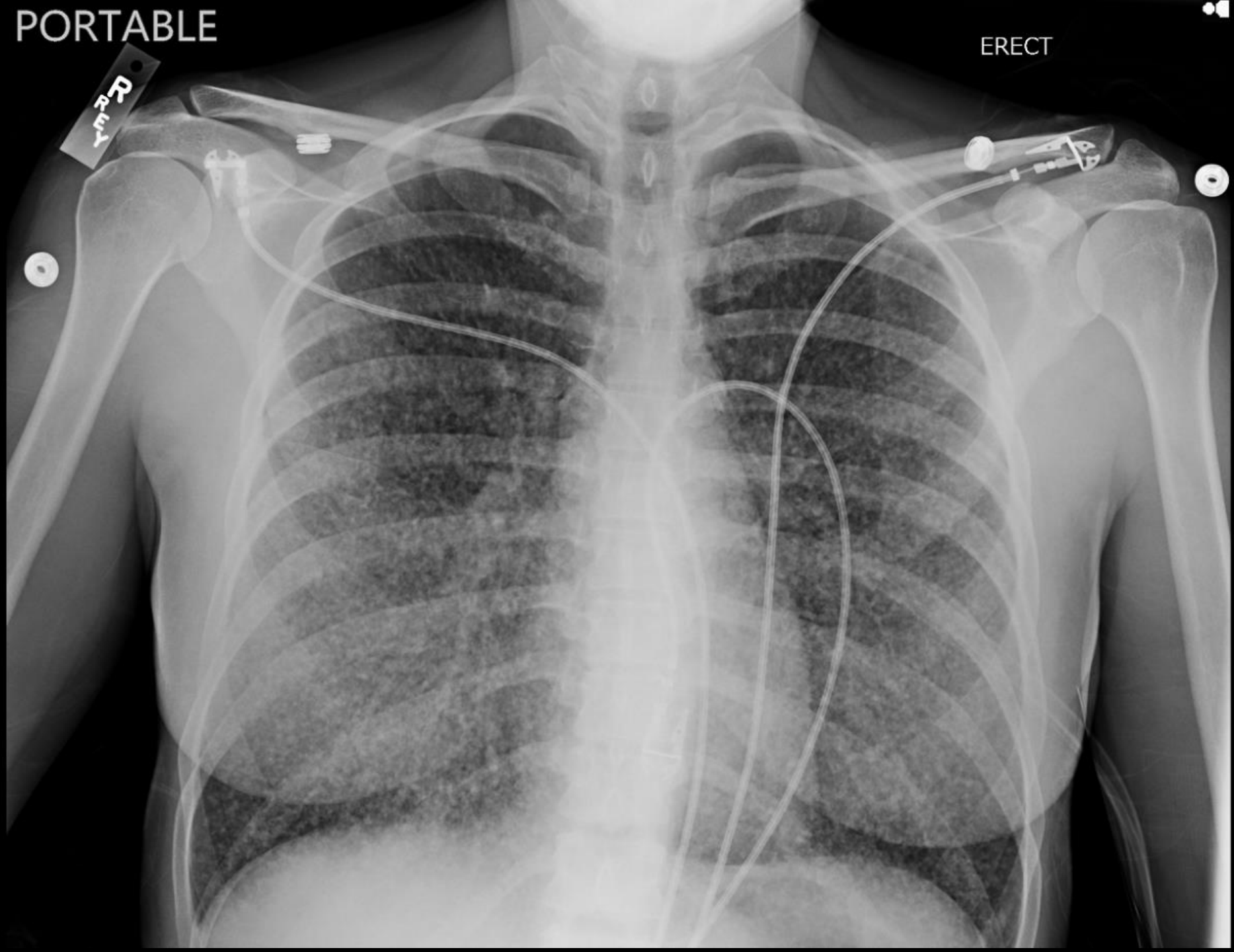


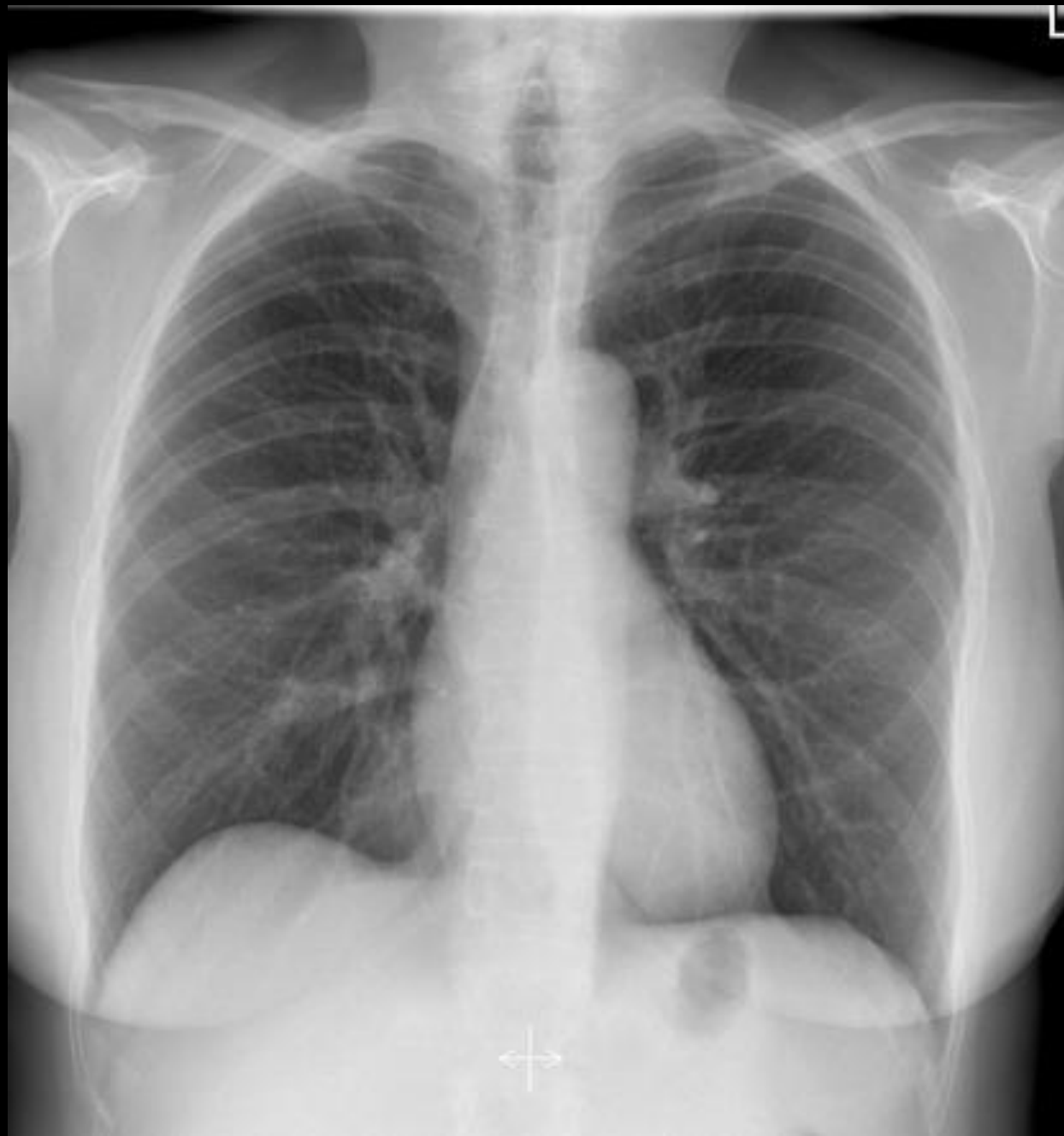


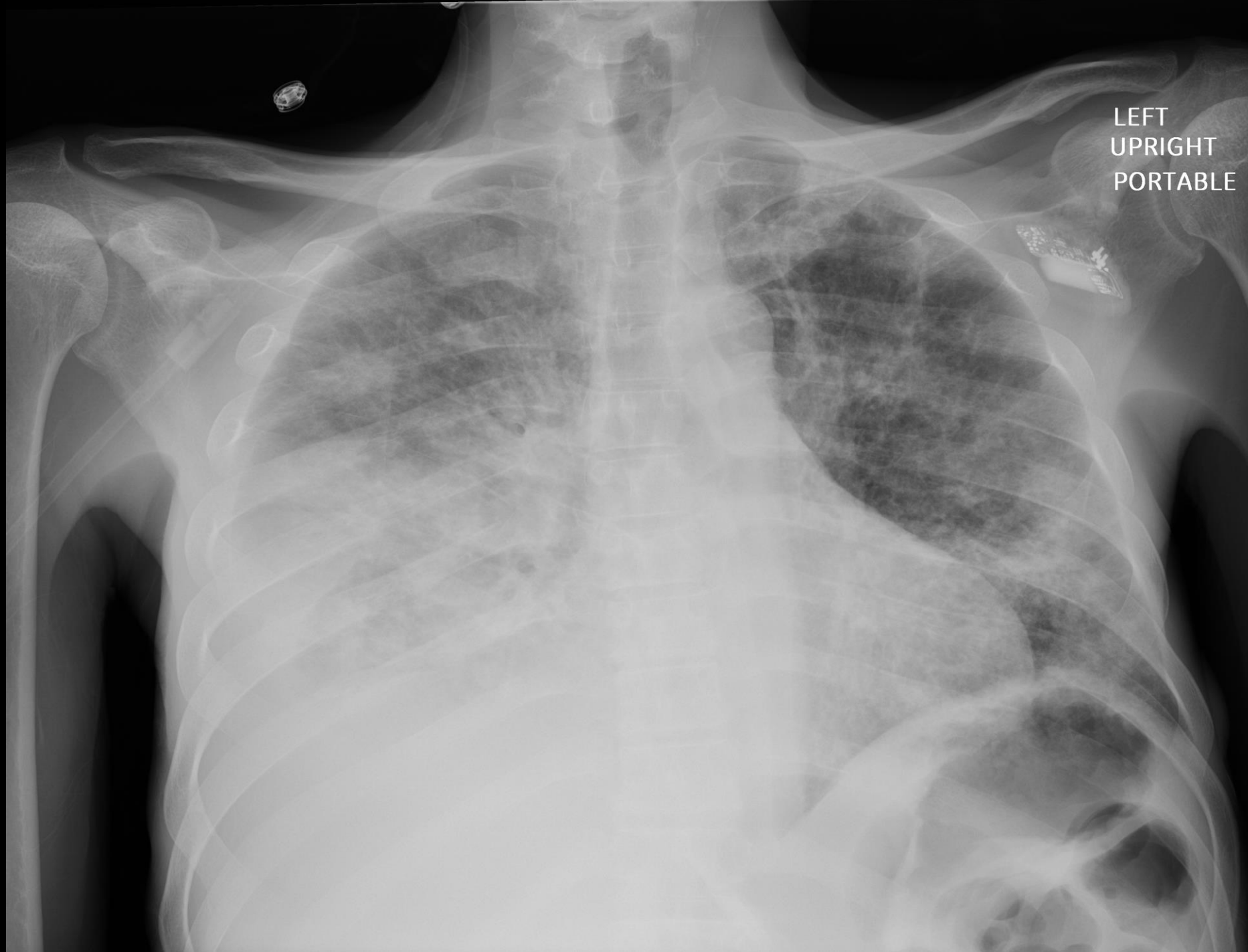
PORTABLE

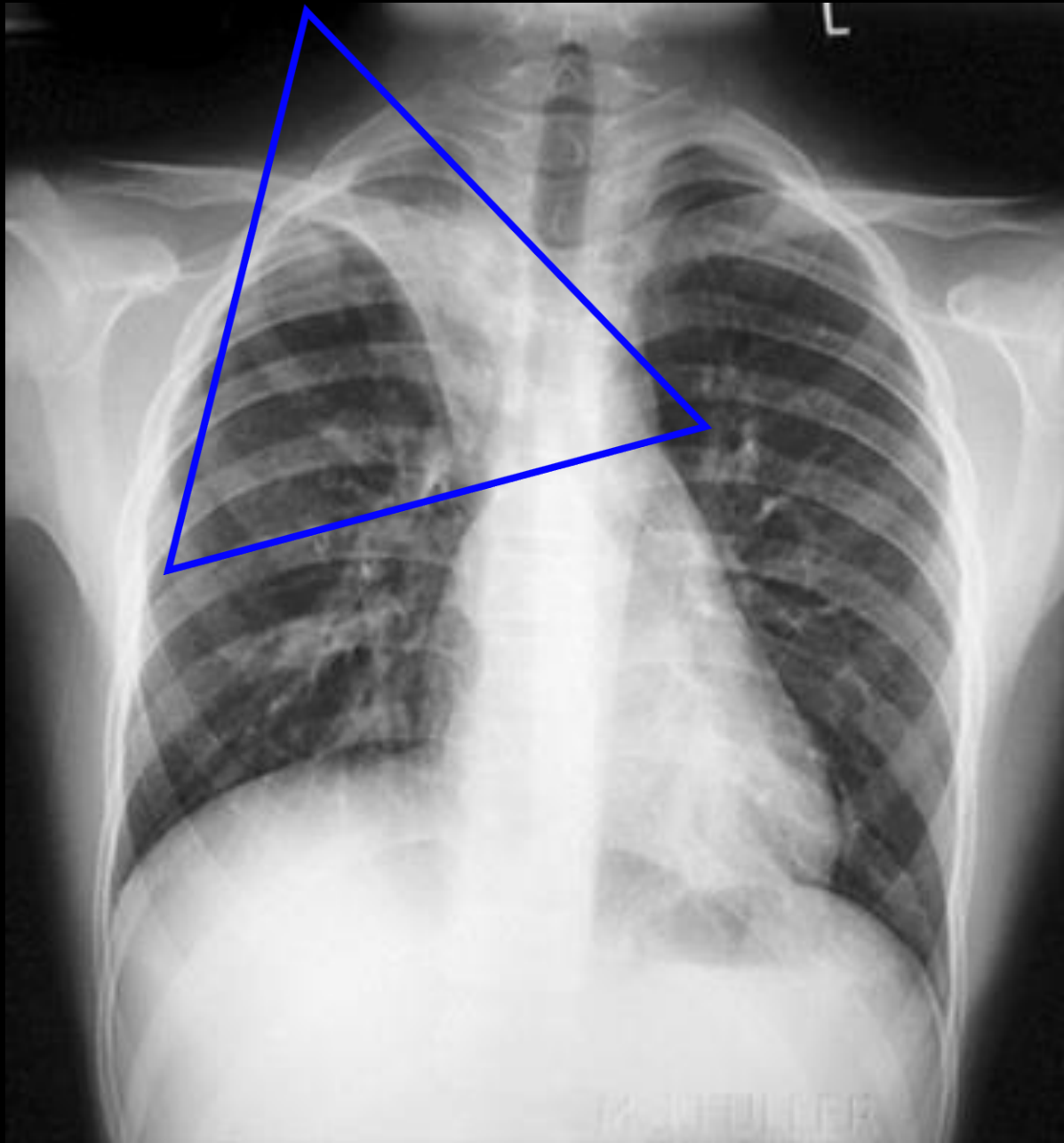
ERECT

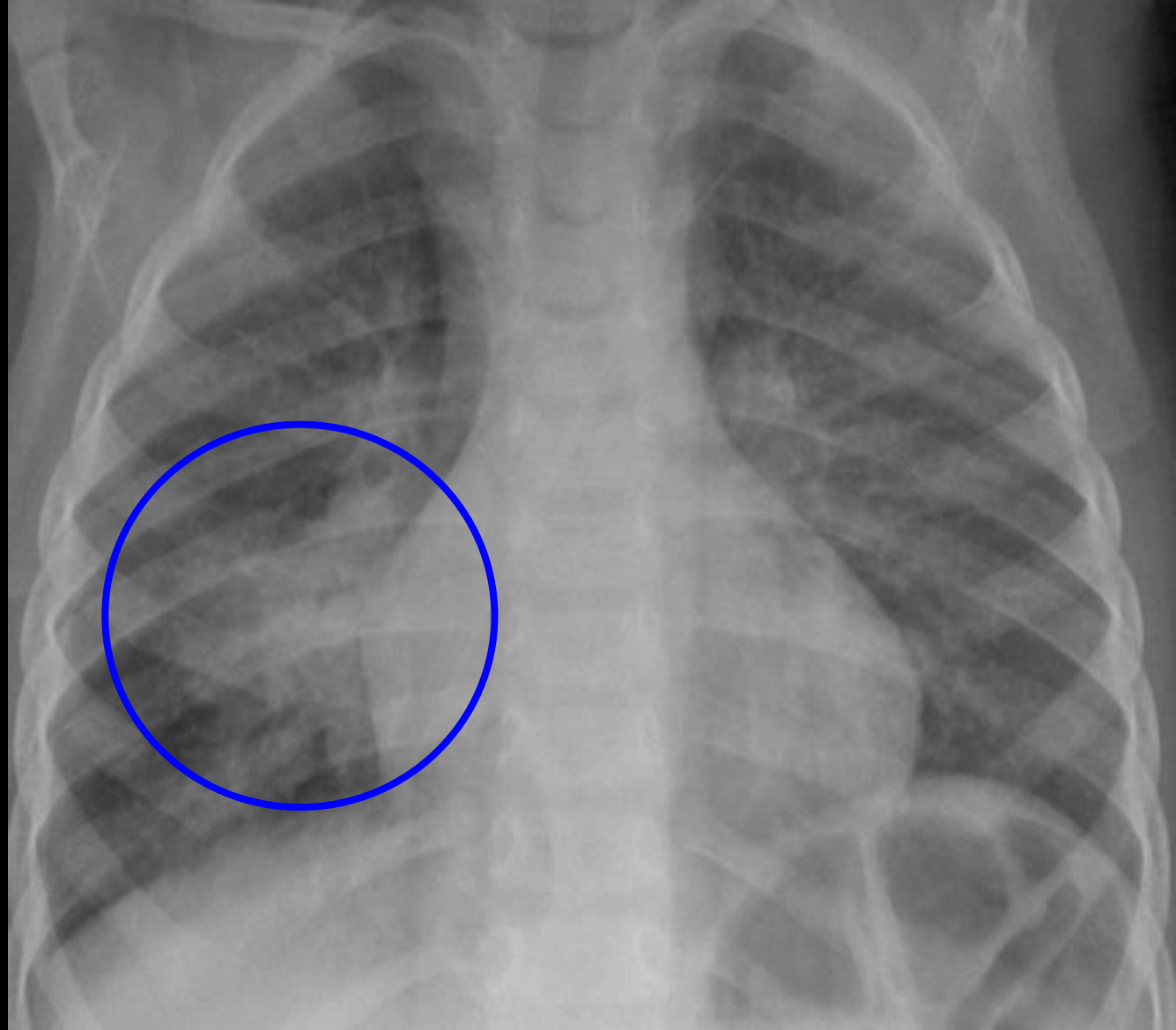




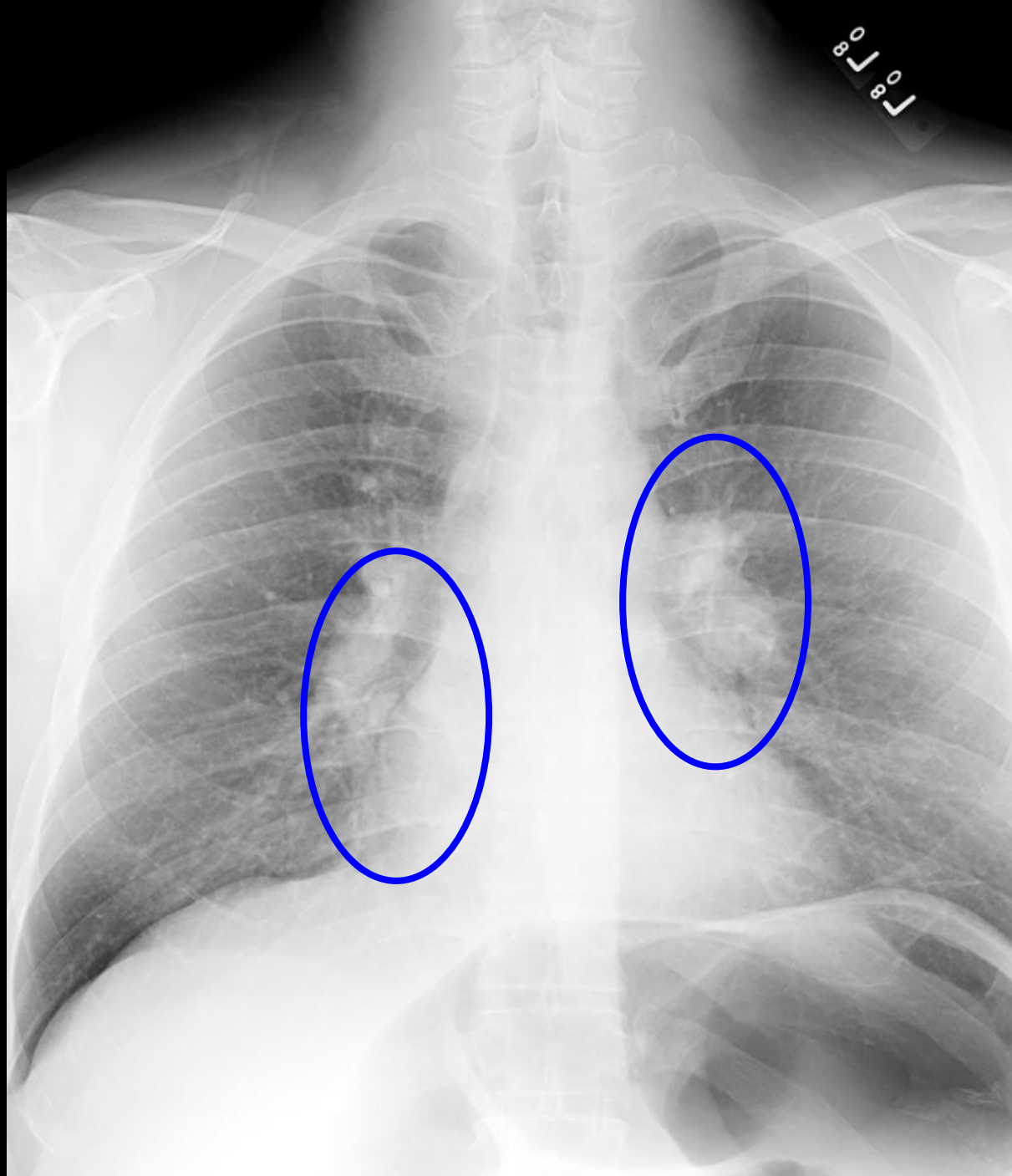


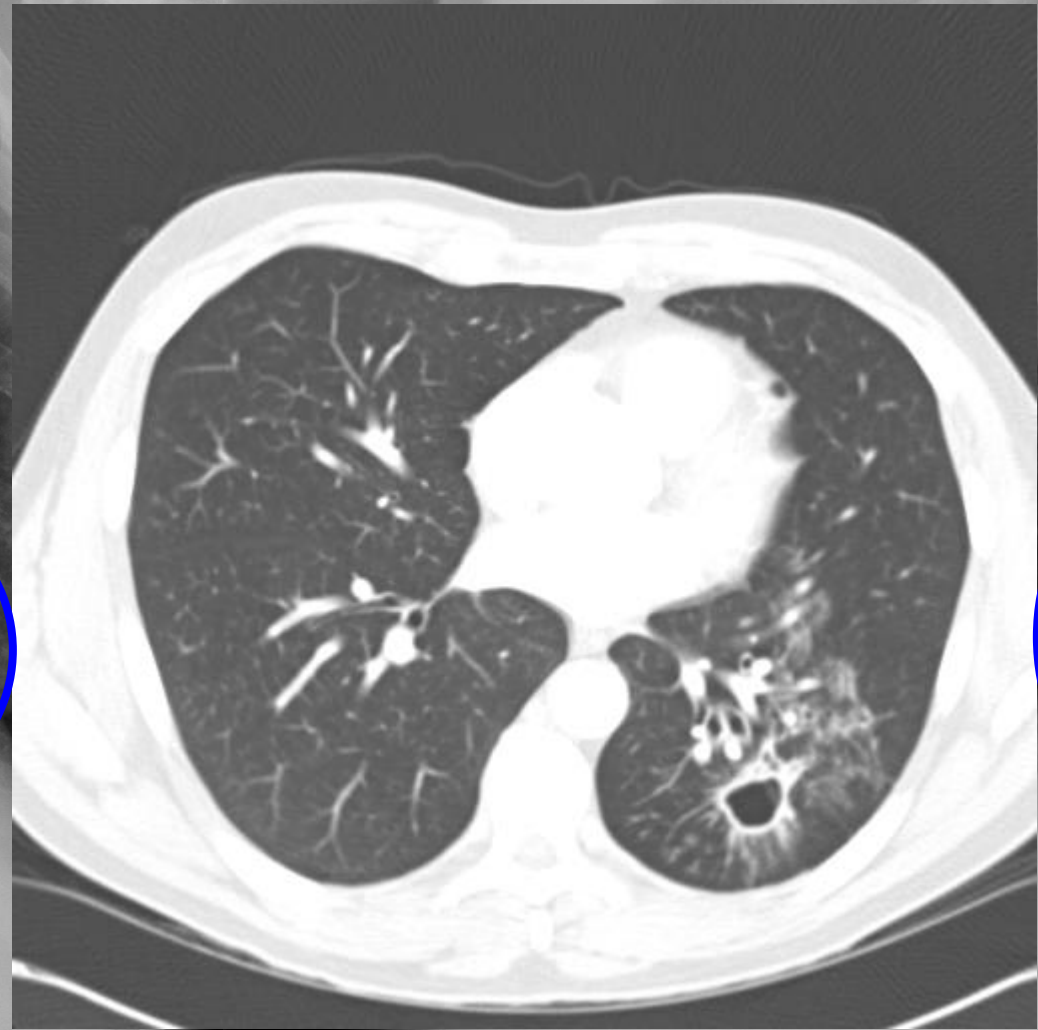
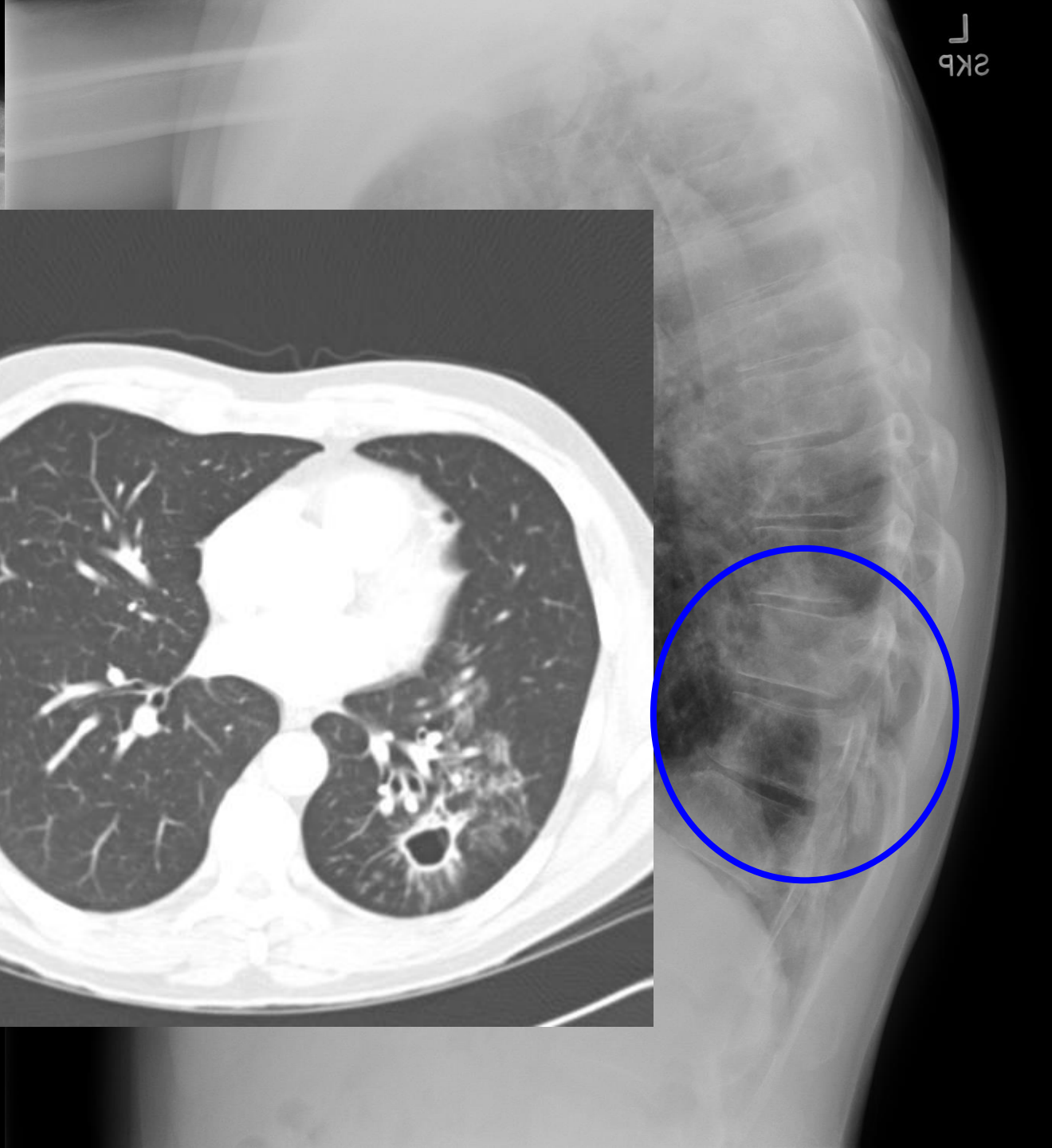
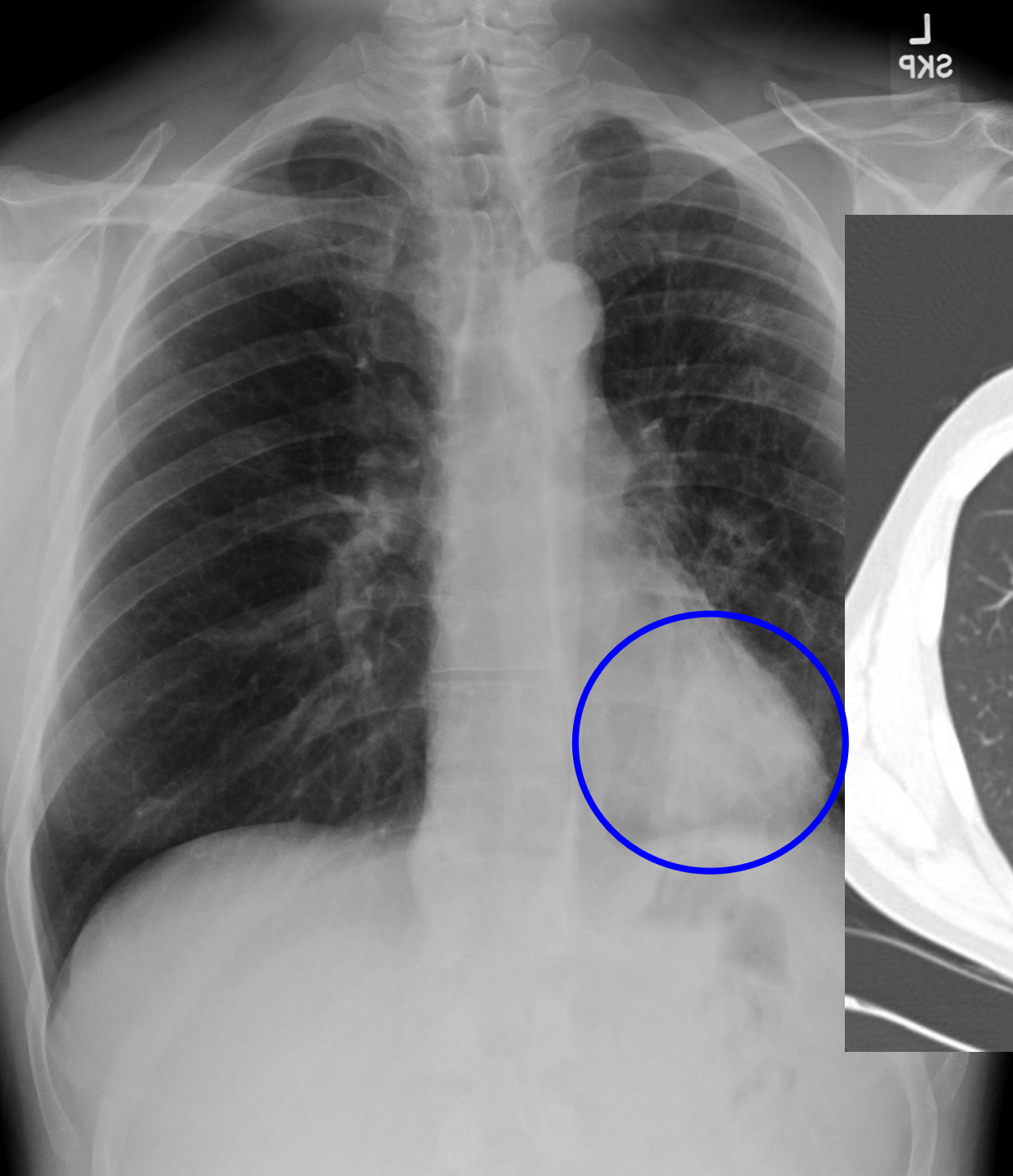
LEFT
UPRIGHT
PORTABLE

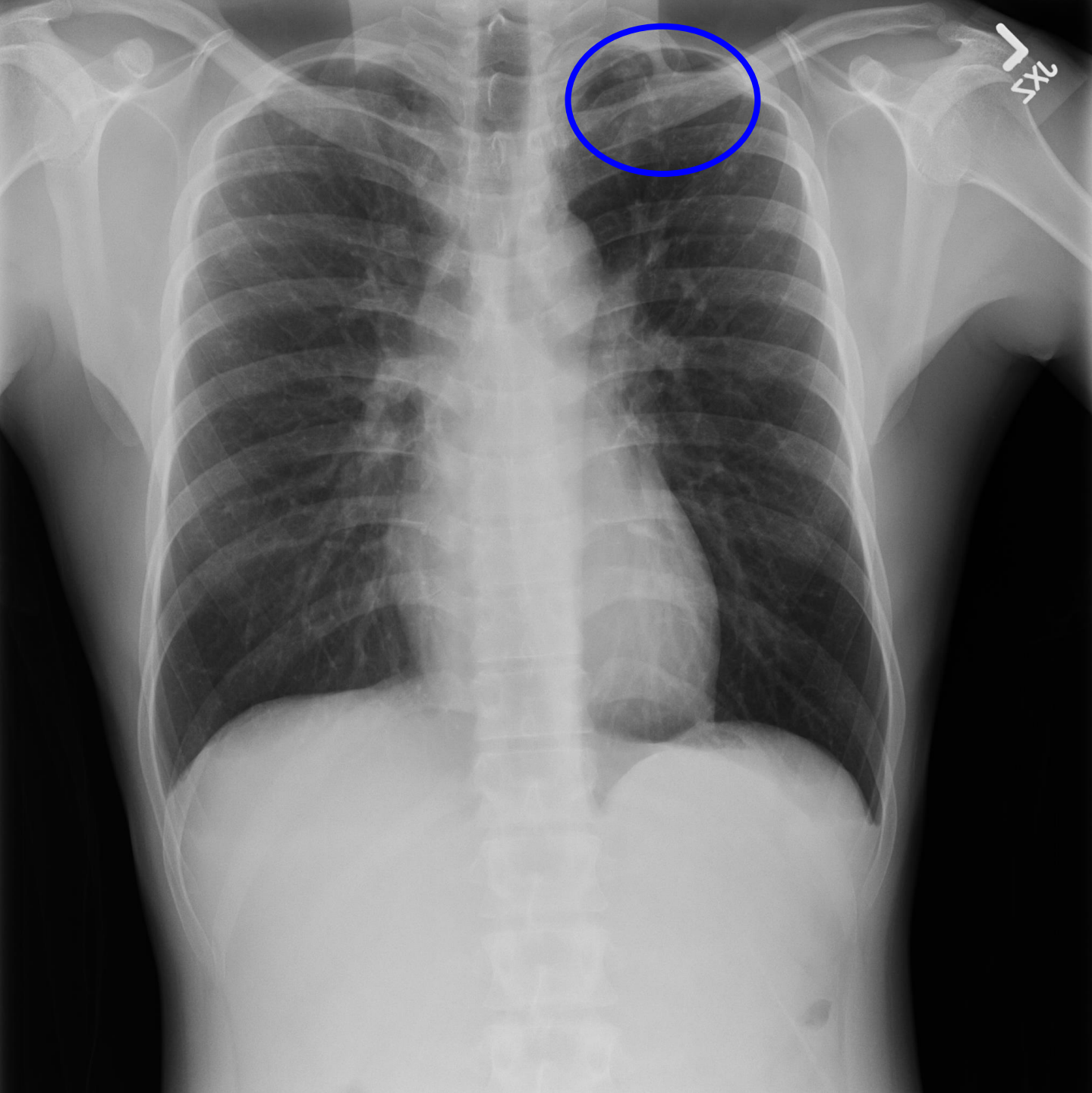
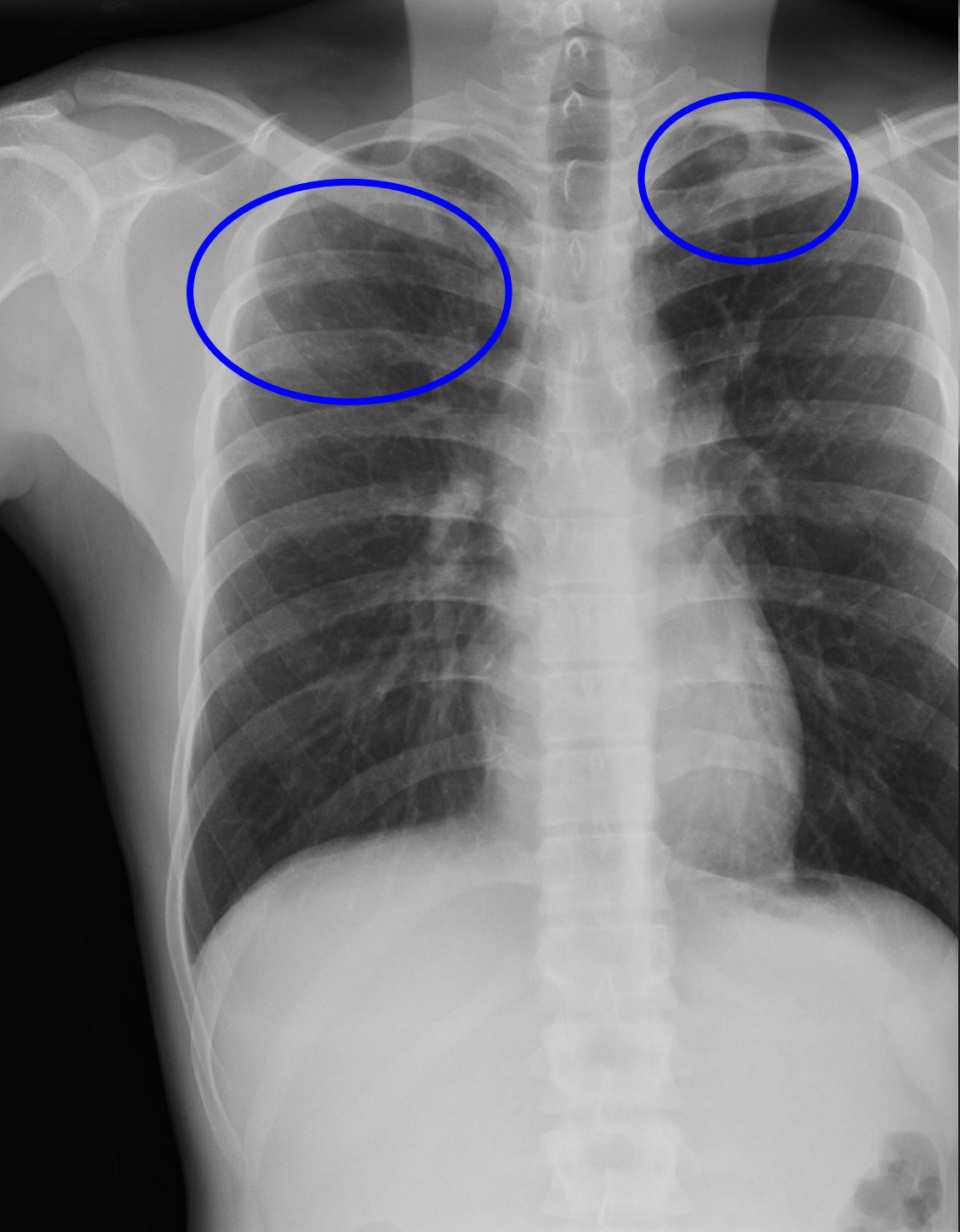




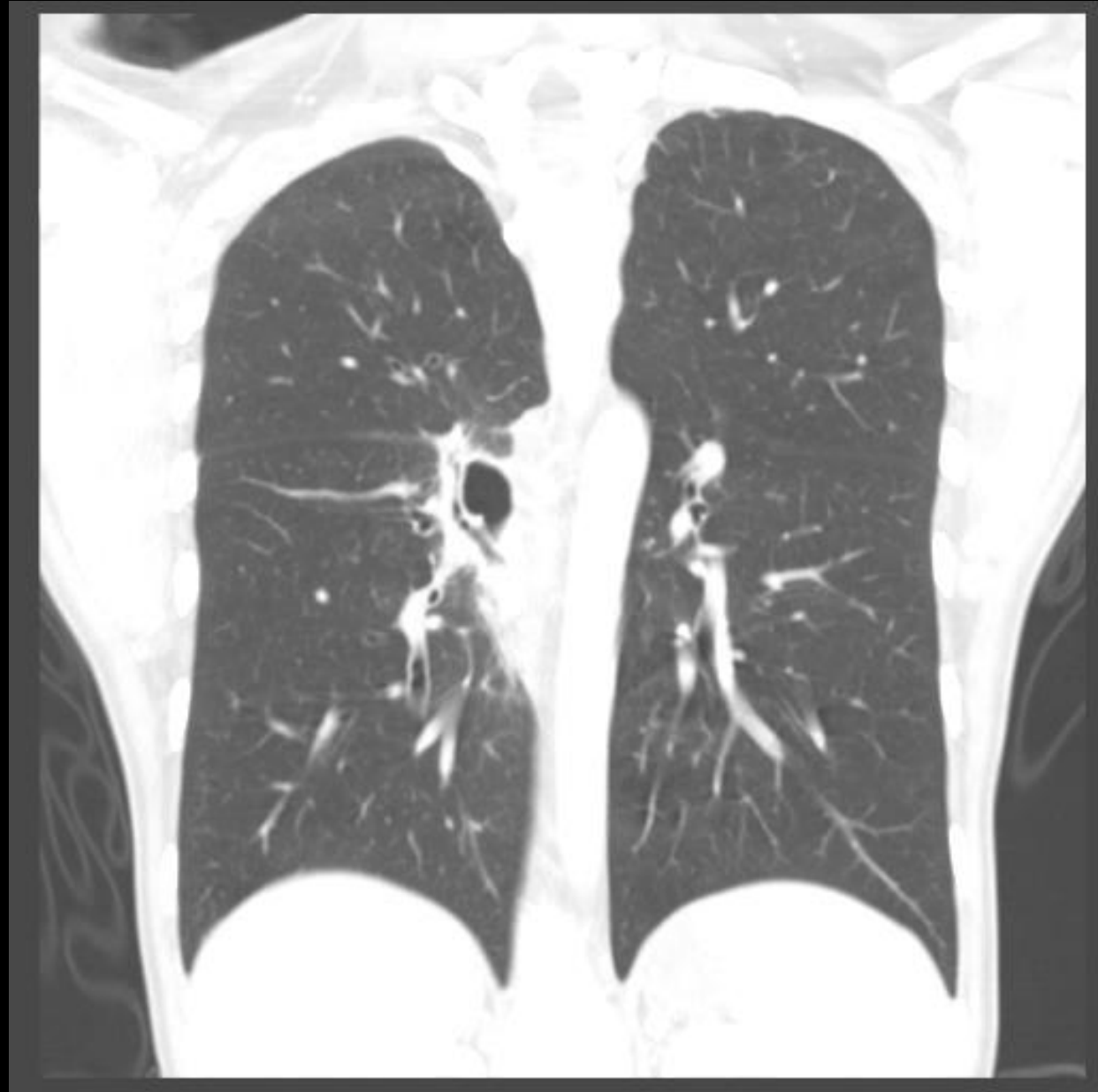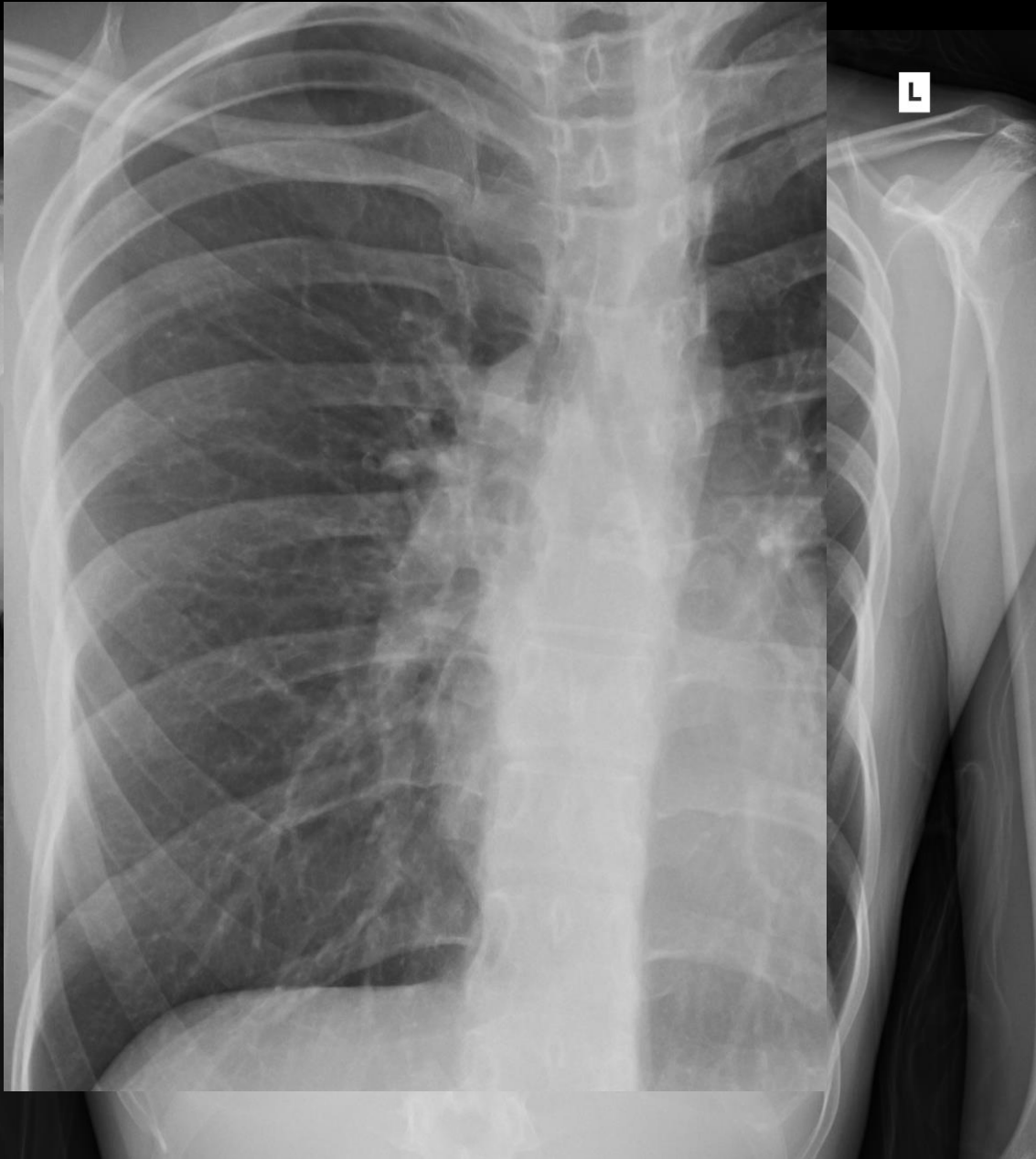


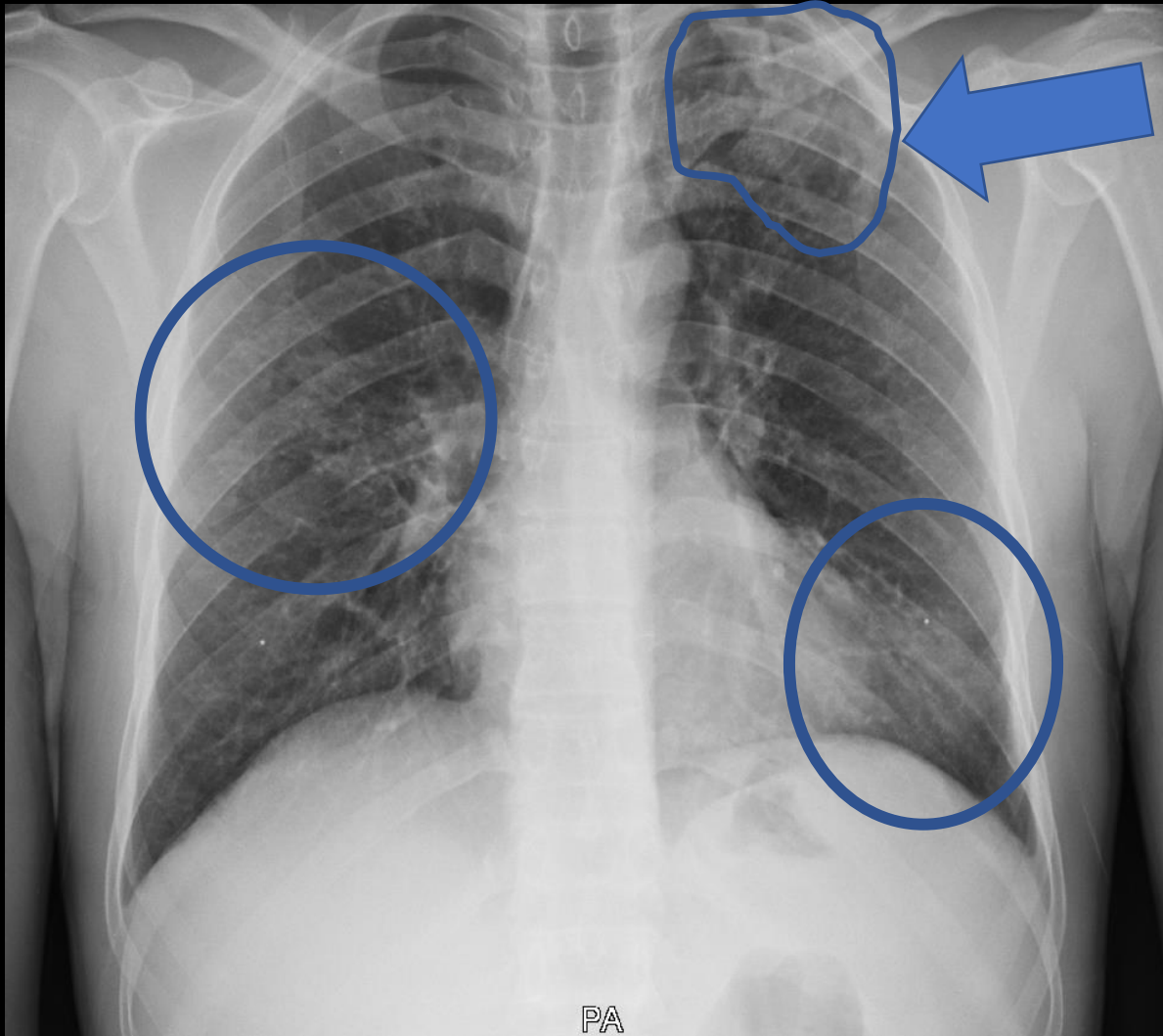






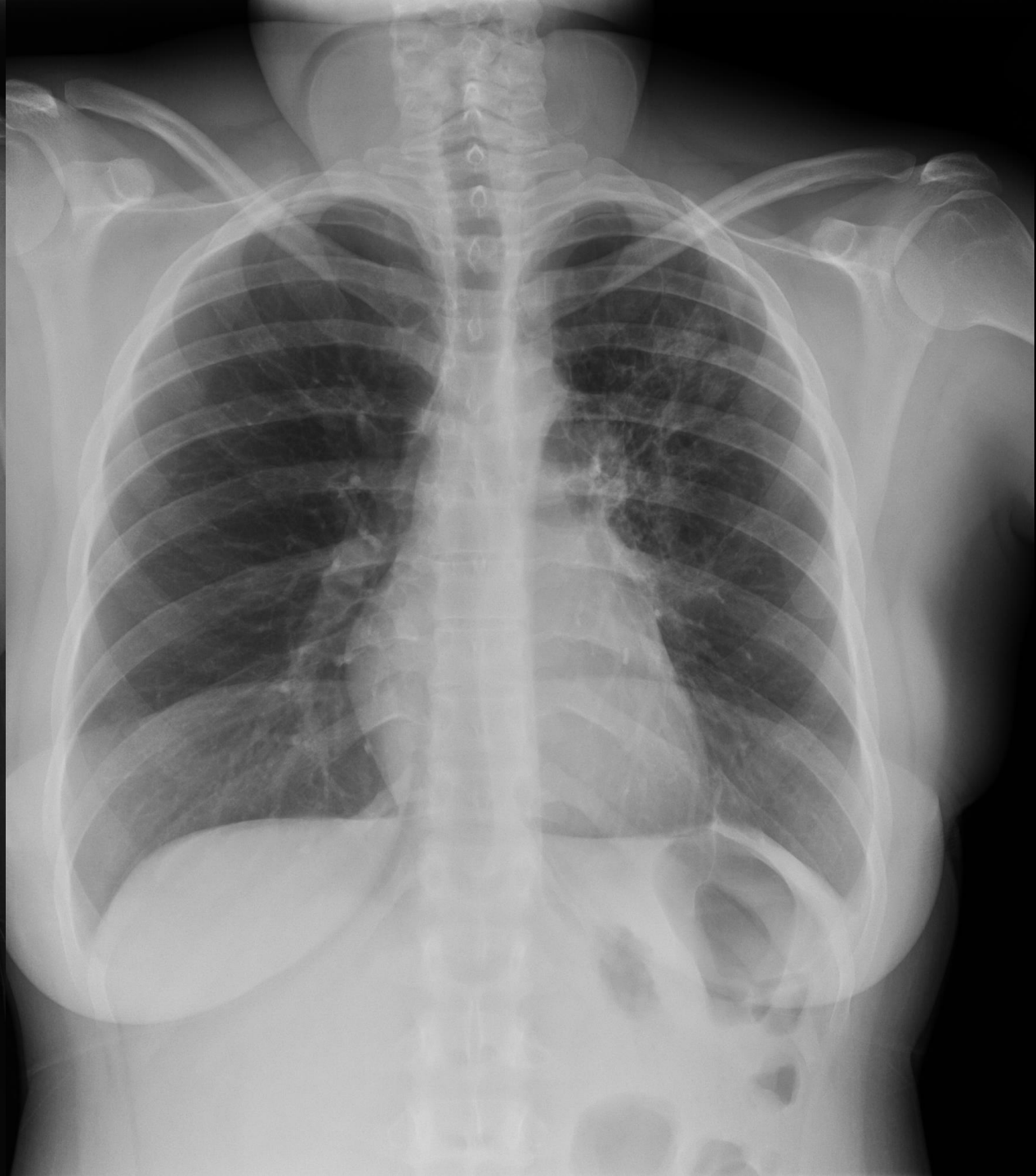
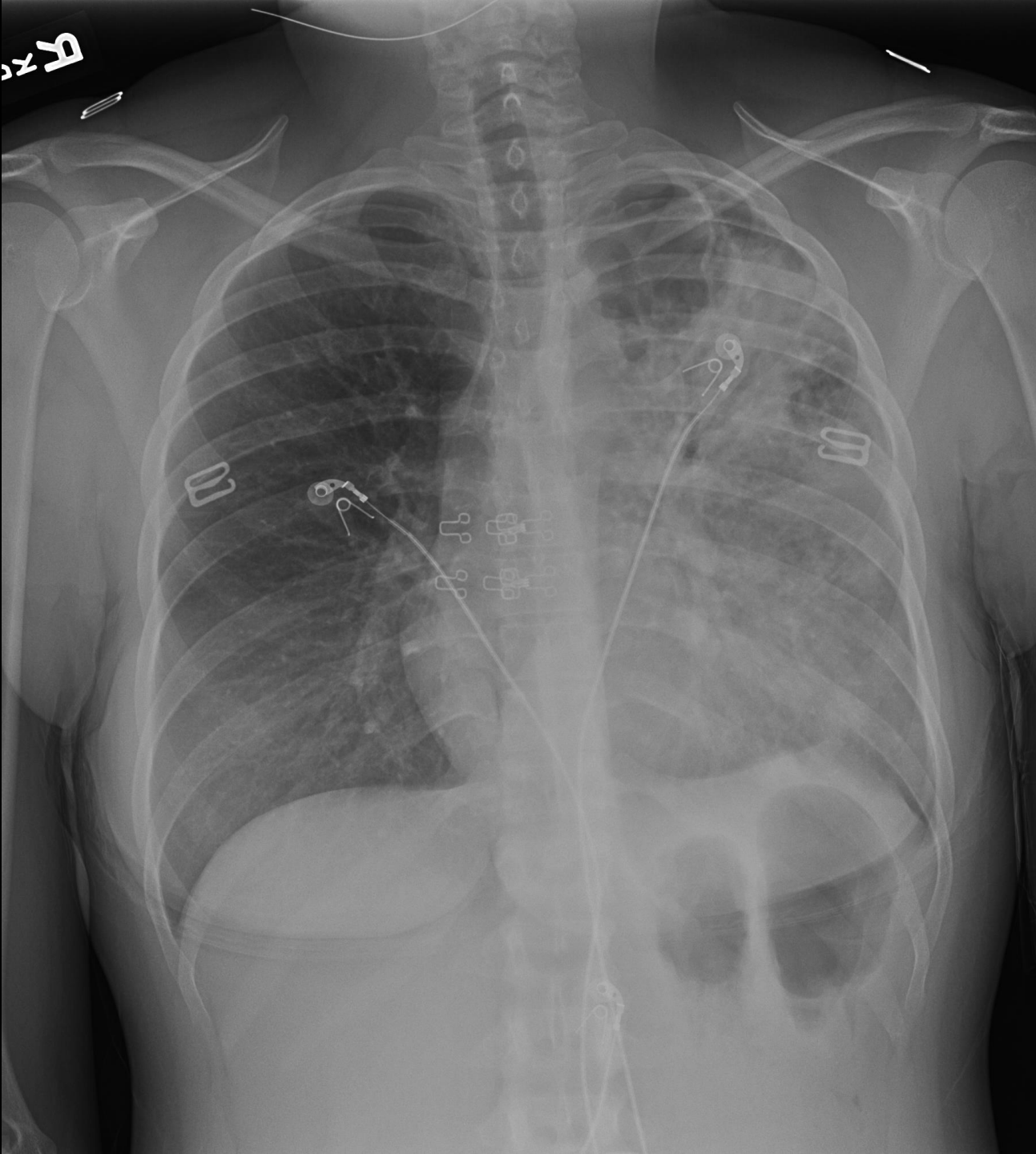




37 year old African man
4 months of cough, weight
loss, and poor energy



Thank you

Heartland TB Center

